

Dermatomyositis as first clinical appearance for a thymic epidermoid cell carcinoma

Roberto Iacovelli, Antonella Palazzo, Davide Conte, Maria Agnese Fabbri, Domenico Vitolo, Enrico Cortesi

Department of Experimental Medicine; "Sapienza" University of Rome, Rome, Italy

Abstract. Primary thymic carcinoma is a rare and heterogeneous group of tumours of the anterior mediastinum that includes different histological types. Frequently, it first comes to clinical attention through paraneoplastic syndromes such as dermatomyositis. We report the case of a 54-year-old woman with several episodes of fever and chest pain in the previous 5 months. The patient was admitted to the Rheumatology Department with a peri-ungual erythema and papular lesions on both sides of each hand and alteration at biochemistry tests. A left deltoid muscle biopsy specimen showed a histological pattern compatible with the diagnosis of dermatomyositis. A computed tomography of the chest, abdomen and pelvis, showed a solid mass in the upper anterior mediastinal area and a mediastinoscopy with mass-biopsy was performed. Only the immunohistochemical staining technique allowed a definitive histological diagnosis. We report the diagnostic challenge and the therapeutic approach of thymic neoplasia. (www.actabiomedica.it)

Key words: Dermatomyositis, thymic carcinoma, paraneoplastic syndrome

Introduction

Primary thymic carcinoma is a very heterogeneous group of tumours of the anterior mediastinum that includes different histological types: neuroendocrine tumours (NET), squamous or mucoepidermoid carcinoma, basaloid, sarcomatoid, lymphoepithelioma like, clear cell and undifferentiated carcinoma. Until recently, their histogenesis and description as a distinct entity from malignant thymoma has been difficult to determine: in contrast with thymomas, thymic carcinomas shows an aggressive behaviour and often invade adjacent organs, such as thoracic vessels, pericardium, and lungs (1).

Frequently, thymic neoplasia first comes to clinical attention through paraneoplastic syndromes: myasthenia gravis is probably the most characteristic, but not the only one. Dermatomyositis and polymyositis are also associated with an increased risk of malignant disease: this risk, however, is substantial-

ly greater since dermatomyositis is assessed to be 30% in patients with polymyositis although these syndromes are rarely related to thymic neoplasia.

Furthermore, tumours with an increased incidence of polymyositis differ from those typical of dermatomyositis; ovarian, lung and colorectal cancer are frequently diagnosed concomitantly with the appearance of dermatomyositis by contrast with non-Hodgkin lymphoma, lung and bladder cancers frequently diagnosed with the polymyositis, suggesting that these tumours can be associated with this diseases (2).

Dermatomyositis represents 10% of paraneoplastic syndromes. It is an inflammatory myopathy with classical symmetrical proximal distribution and characteristic cutaneous manifestations. Published studies report a wide variation in the estimated risk of malignancy in patients with dermatomyositis, ranging from 18% to 45%. The cancer diagnosis is generally concurrent with dermatomyositis onset, but malignancies can be diagnosed up to 3-5 years later (3, 4).

Case report

We report the case of a 54-year-old woman that presented several episodes of fever (38°C) and chest pain successfully treated with ampicillin and non steroids anti-inflammatory agents (NSAID) in the previous 5 months. Similar episodes and diffuse arthromyalgias of the shoulders appeared in the following weeks. Two months later the patient reported asthenia, diffuse myalgia, and face and chest cutaneous rash. The blood tests, requested by her general practitioner, showed high CPK (16394 IU/l), LDH (2313 IU/l), ESR (69 mm/h), CRP (8.6 mg/l), Ra-test (48 IU/l), Fibrinogen (469 mg/ml), D-Dimer (295 µg/ml), Myoglobin (1316 µg/dl), GOT (580 mg/dl) and GPT (297 mg/dl). The blood cell count showed 20.100/mm³ white blood cells (WBC) with 92% neutrophils and 4% lymphocytes.

The patient was admitted to the Rheumatology Department where a clinical examination showed: peri-ungual erythema and papular lesions on both sides of each hand. Repeated blood tests revealed increased CRP (14 mg/l), Amylase (90 IU/l), and Lipase (132 IU/l). The results of rheumatologic tests showed: Ra-test = 46 IU/l; Waaler Rose assay = 20 IU/l; FII latex = 1:160; C3= 152 mg/dl; C4 = 34 mg/dl; ANA = ++; anti-ENA = negative; Anti-SSA > 100 IU/ml; serum electrolytes and coagulation tests were in normal ranges. Microbiological studies were also performed: Widal-Wright, Weil-Felix, CMV, EBV, and HIV tests were negative.

A left deltoid muscle biopsy specimen showed a histological pattern compatible with the diagnosis of dermatomyositis. With the suspect of a paraneoplastic syndrome, a computed tomography (CT) of the chest, abdomen and pelvis was performed, showing a 10 x 6 cm solid mass with lobulated margins in the upper anterior mediastinal area, with a 50% reduction of the superior vena cava lumen (Figure 1). Several thrombotic lesions were observed in the common iliac left axis and right hypogastric vein. The patient began anti-thrombotic therapy with heparin 2500 IU infused in 24 hours. A magnetic resonance imaging (MRI) confirmed the mediastinal mass with displacement of the thoracic vessels.

During hospitalization parenteral steroid therapy was administered with prompt improvement of the

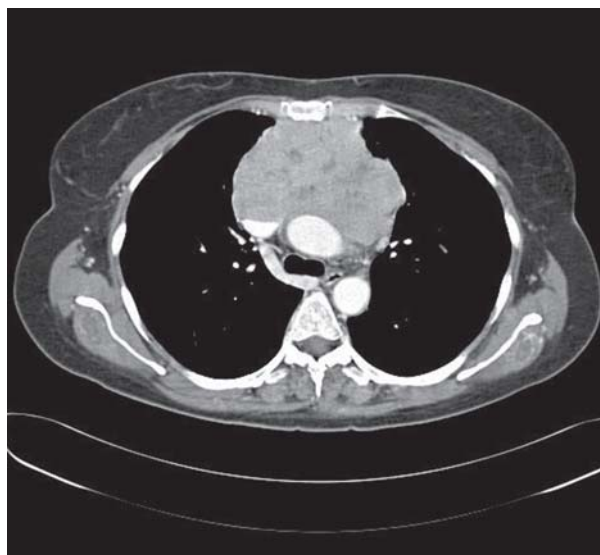

Figure 1. Computed tomography of the thorax showing a mass in the anterior mediastinum

clinical features: the serum indexes of muscular damage decreased, the cutaneous rash and the peri-ungual lesions disappeared and other haematological tests returned within the normal ranges.

The patient was then admitted to the Thoracic Surgery Unit, where a mediastinoscopy with mass-biopsy was performed. The histological findings indicated poorly differentiated epidermoid carcinoma; the immunohistochemical assay was positive for cytokeratine and negative for neuroendocrine markers. A primary pulmonary origin was suspected. Brain CT and bone scintigraphy were negative. A new CT of the chest, abdomen and pelvis, 35 days after the previous one, showed no increase of the mass, no new lesions and the resolution of thrombo-embolic disease.

Due to the local extension of the lesion the patient was judged as inoperable by the thoracic surgeon.

When the patient was referred to our Oncology Unit, a new evaluation of the histological sample was required. On the basis of a positive CD5 immunohistochemical staining (Figure 2), the diagnosis was changed to epidermoid thymic carcinoma, not keratinizing, according to the WHO (1999) classification.

According to the literature, CD5 expression in epithelial cells is a marker that is able to distinguish non-neuroendocrine thymic carcinoma from thymomas and carcinosarcomas of non-thymic origin.

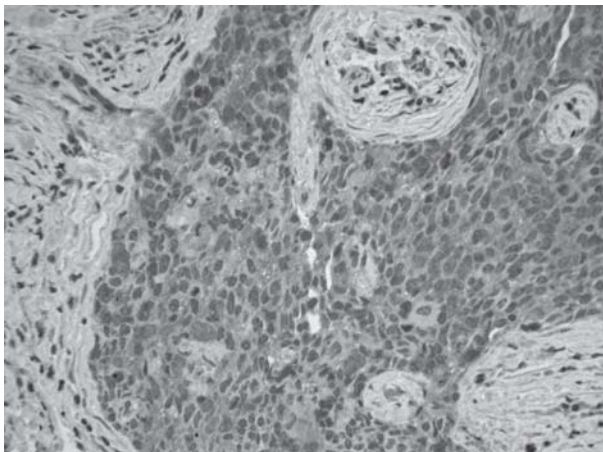


Figure 2. Epidermoid thymic carcinoma not keratinizing, immunohistochemically featured by CD5 staining

Moreover, thymic carcinoma, especially epidermoid, undifferentiated and lymphoepithelioma-like tumours, express CD5 while thymomas and other non-thymic neoplasms are negative for this immunohistochemical marker (5).

Based on this confirmed histological diagnosis the patient was treated with chemotherapy using a cisplatin-epirubicin combined regimen. A CT of the chest, abdomen and pelvis, performed after two months of chemotherapy, showed a stable disease and a regression of paraneoplastic symptoms was reported. The therapy was continued for further three months using the same schedule, but then a CT showed both a local and systemic progression of disease with the appearance of hepatic and bone metastases. The patient's clinical condition worsened, she showed a superior vena cava syndrome due to local progression of the disease and was referred to a Palliative Care Unit.

Discussion

The differential diagnosis for neoplasm arising from upper-mediastinum in a 54 years old patient includes on first instance, and according to the clinical condition, metastasis in a lymph node of a lung large cell carcinoma; a further possibility may be represented by a thymoma and then by a lymphoma. Finally, a mediastinal germ cell tumour may only represent the last possibility. The histology of the neoplasm under

investigation, consisting of solid nests of non keratinizing malpighian like cells, excluded the possibility either of a lymphoma or a lymphocytic rich thymoma. Therefore, the choice was restricted between a metastasis of a large cell lung carcinoma, without the clinical appearance of a parenchymal lesion, and a primary tumour of mediastinal structures such as thymus. In this last regard, for what it may concern thymomas, given the low lymphoid component, the chance was further restricted to a type B3 thymoma (well differentiated thymic carcinoma according Muller-Hermelink) or to a thymic epidermoid cell carcinoma according to WHO 2004 classification (6). The immunohistochemistry excluded the expression of lymphoid and neuroendocrine markers such as CD45, CD56, cromogranin A and synaptophysin but demonstrated cytokeratin clone-MNF116 and CD5 in the majority of the neoplastic cells population. These findings, taken together with the other histological and clinical findings, helped us to establish the diagnosis of thymic carcinoma. In fact it is well known from the literature that thymic epidermoid cell carcinoma represent the only one non-keratinizing epidermoid human carcinoma able to express the CD5.

The paraneoplastic syndrome of thymic carcinoma rarely has been reported. It is widely known that myasthenia gravis is one of the paraneoplastic syndrome of thymoma, while its frequency with thymic carcinoma is reported in literature only in 8% of patients⁷. Although occasionally patients affected by this neoplasia may exhibit symptoms of other autoimmune disease such as polymyositis and dermatomyositis⁸. The pathogenesis of paraneoplastic dermatomyositis is still unclear and it is thought to be an autoimmune response related to disease.

To our knowledge only two other case reports of dermatomyositis accompanied by thymic carcinoma are described in literature (9, 10). Despite many studies aimed to explain the correlation between cancers and autoimmunity, the rarity of thymic carcinoma makes it even more difficult to understand the pathogenetic mechanisms underlying these events.

Several chemotherapy regimens have been used in the treatment of thymic carcinoma and most of them are platinum based such as VIP (etoposide, ifosfamide, cisplatin) and ADOC (cisplatin, doxorubicin, vincristine, and cyclophosphamide). The role of

chemotherapy, however, remains questionable since this proves to be the least sensitive of thymus-derived cancers and the one with the worst prognosis: even symptom palliation is seldom achieved.

Surgery, even when not radical and with debulking purpose only, has been shown to be an important therapeutic measure, especially in thymomas which have a slow growth. The efficacy of surgery or radiotherapy for thymic carcinoma remains controversial (11).

Conclusions

This paper reports dermatomyositis as a first unusual manifestation of a rare neoplasia and it remarks the importance of immunohistochemical staining in order to obtain a correct diagnosis and to decide a proper treatment of this carcinoma.

References

1. Takeda S, Sawabata N, Inoue M, et al. Thymic carcinoma. Clinical institutional experience with 15 patients. *Eur J Cardiothorac Surg* 2004; 26: 401-6.
2. Hill CL, Zhang Y, Sigurgeirson B, et al. Frequency of specific cancer types in dermatomyositis and polymyositis: a population based study. *Lancet* 2001; 357: 96-100.
3. Chandiramani M, Joynsony C, Panchaly R, et al. Dermatomyositis as a paraneoplastic syndrome in carcinosarcoma of uterine origin. *Clinical Oncology* 2006; 18: 641-8.
4. Stockton D, Doherty VR, Brewster DH. Risk of cancer in patients with dermatomyositis or polymyositis and follow up implications: a Scottish population based cohort study. *Br J Cancer* 2001; 85: 41-5.
5. Chalabreysse L, Etienne-Mastroianni B, Adeleine P, et al. Thymic carcinoma: a clinicopathological and immunohistological study of 19 cases. *Histopathology* 2004; 44: 367-74.
6. Travis WD, Brambilla E, Muller-Hermelink HK, et al. World Health Organization Classification of Tumours. Pathology and Genetics of Tumours of the Lung, Pleura, Thymus and Heart. IARC Press: Lyon, 2004.
7. Liu HC, Hsu WH, Chen YJ, et al. Primary thymic carcinoma. *Ann Thorac Surg* 2002; 73: 1076-81.
8. Inoue Y, True LD, Martins RG. Thymic carcinoma associated with paraneoplastic polymyositis. *J Clin Oncol* 2009; 27: e33-4.
9. Fong PH, Wee A, Chan HL, et al. Primary thymic carcinoma and its association with dermatomyositis and pure red cell aplasia. *Int J Dermatol* 1992; 31: 426-8.
10. Takahashi F, Tsuta K, Nagaoka T, et al. Successful resection of dermatomyositis associated with thymic carcinoma: report of a case. *Surg Today* 2008; 38: 245-8.
11. Giaccone G, Wilmink H, Paul MA, et al. Systemic treatment of malignant thymoma. A decade experience at single institution. *Am J Clin Oncol* 2006; 29: 336-44.

Accepted: February 18th 2010

Correspondence: Dr Roberto Iacovelli
Department of Experimental Medicine,
Medical Oncology Unit;
"Sapienza" University, Rome, Italy
Palazzina EX SCRE
Viale Regina Elena 324
00161 Roma.
Tel. +39-3339516295
Fax 064463686
E-mail: roberto.iacovelli@alice.it