

## Individualized therapy for complicated cranial defect: a case report

*Nanze Yu, Zhifei Liu, Hailin Zhang, Xiaojun Wang*

Division of Plastic Surgery, Peking Union Medical College Hospital, Peking Union Medical College, Chinese Academy of Medical Science, Beijing, China

**Abstract.** Despite the considerable advances in plastic surgery in recent years, complicated large cranial defects remain challenging clinical entities with no clear management algorithms, especially in the pediatric age group. We present a 9-year old boy who underwent a hemispherectomy for Rasmussen encephalitis. Functional and cosmetic outcomes are considered during the procedure. ([www.actabiomedica.it](http://www.actabiomedica.it))

**Key words:** large cranial defect, cranioplasty, rasmussen encephalitis, tissue expander

### Introduction

Large cranial defects are commonly seen after trauma, electrical injury and craniectomies. They are further complicated by cranial sinuses involvement, soft tissue defects, and infections. These pose significant challenges to both the reconstructive and neurosurgeons. In the pediatric population, special consideration needs to be placed on the potential influence on brain growth, and the psycho-social development of the patient.

### Case Report

A 9-year-old boy presented to our department with the chief complaint of a large cranial defect on the right side since 18 months. Patient was clinically diagnosed at the age of 13 months with Rasmussen encephalitis (RE). A biopsy confirmed the diagnosis 3 years later after which a corpus callosotomy was performed. Symptoms persisted after the operation, and in April 2008 he underwent a right functional hemispherotomy, which was also ineffective in ceasing the seizures. In May 2008, he received a right hemi-

spherotomy which successfully stopped the seizures. However, the case was further complicated by a local infection, accompanied by scalp necrosis and a resultant exposed skull 3 months after the operation. The intractable infection was only eliminated following radical debridement and a craniectomy in September 2008, which was followed by disorderly distributed postoperative scars. In addition to physical rehabilitation, the patient was placed on oxcarbazepine and sodium valproate to maintain a seizure-free state for the following 2 years.

Physical examination revealed a 20×15cm cranial defect on the right side, with the scalp caved in and adhered to the cerebral falx. Multiple postoperative scars were seen on the right side of scalp (Fig. 1). Muscle strength was grade 3 in both right upper and lower extremities. His mental age was about 2-3 years. There were no abnormalities on the left side, and no pathologic reflexes were detected.

A CT scan was taken and 3D reconstruction of the right side of the skull was performed, allowing for an individualized symmetrical titanium prosthesis (Fig. 2, 4). A two-step treatment plan was implemented aimed at repairing the cranial defect and to remove the areas of scarring alopecia. To resolve the pro-

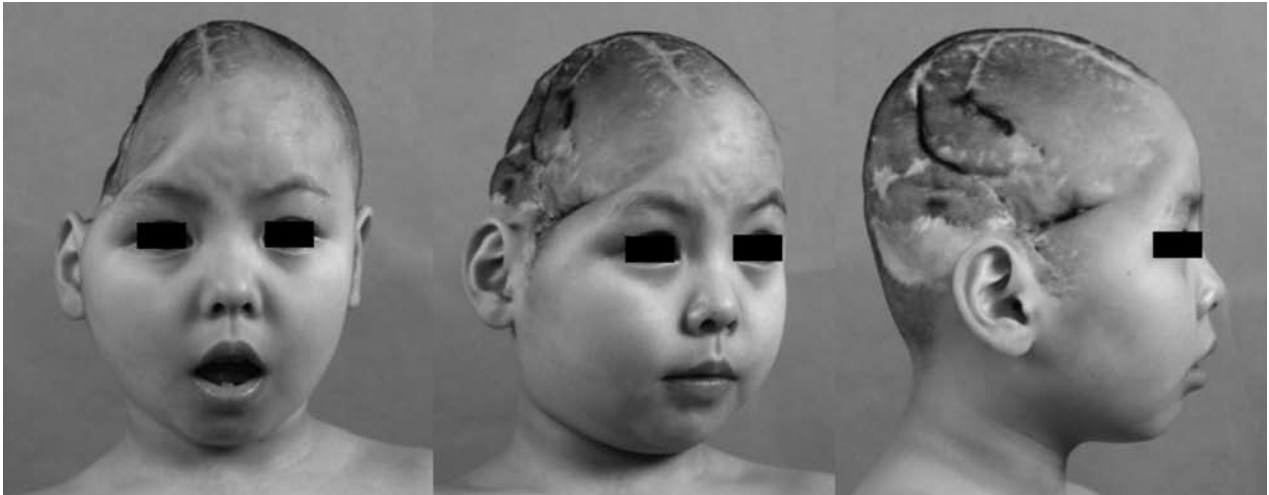

Figure 1. First present to our department. Large cranial defect and multiple postoperative scars were seen on the right side of scalp

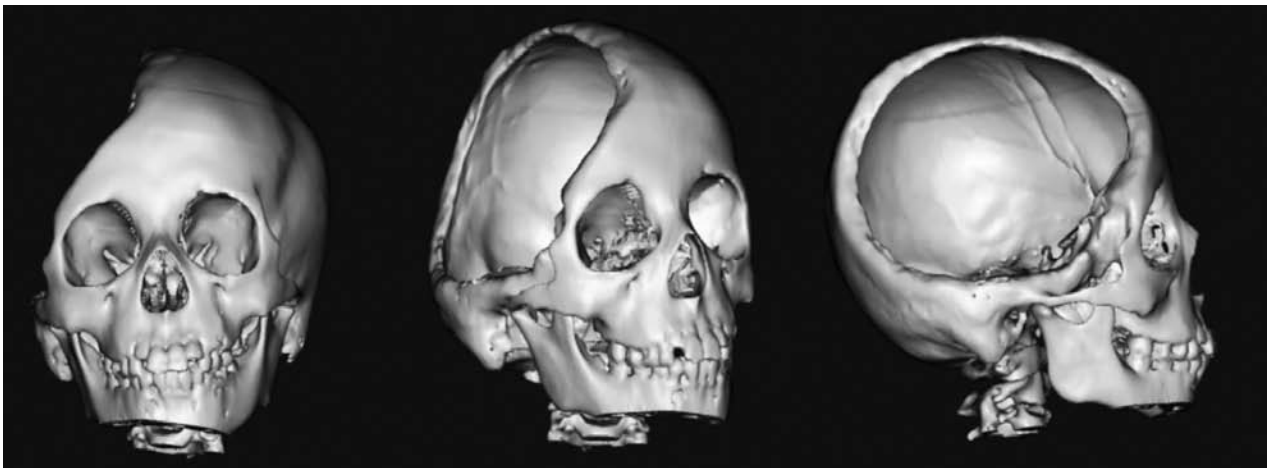


Figure 2. 3D reconstruction showed a mimic view of the defect

blem of scalp insufficiency, 2 rectangular tissue expanders (volumes of 400ml and 500 ml) were embedded subgaleally, into the parietal and occipital parts of the head respectively. Saline was delivered into the expanders regularly once or twice per week for 4 months. After successful completion of tissue expansion (Fig. 3), the second operation to place the titanium skull was undertaken. Dissection was carefully carried out beneath the follicular layer and above the endocranium in order to avoid iatrogenic alopecia or leakage

of cerebrospinal fluid. The dissection region was slightly larger than the defect area so that the individualized titanium prosthesis could be fixed on the skull with titanium nails. Only the anterior and superior borders were fixed so as to avoid future impediment on cranial development (Fig. 4). Wounds were covered with the expanded scalp flaps with hairlines trimmed symmetrically to the left side. An approximate round and symmetrical head was achieved and favorable results were obtained during the follow-up (Fig. 5).

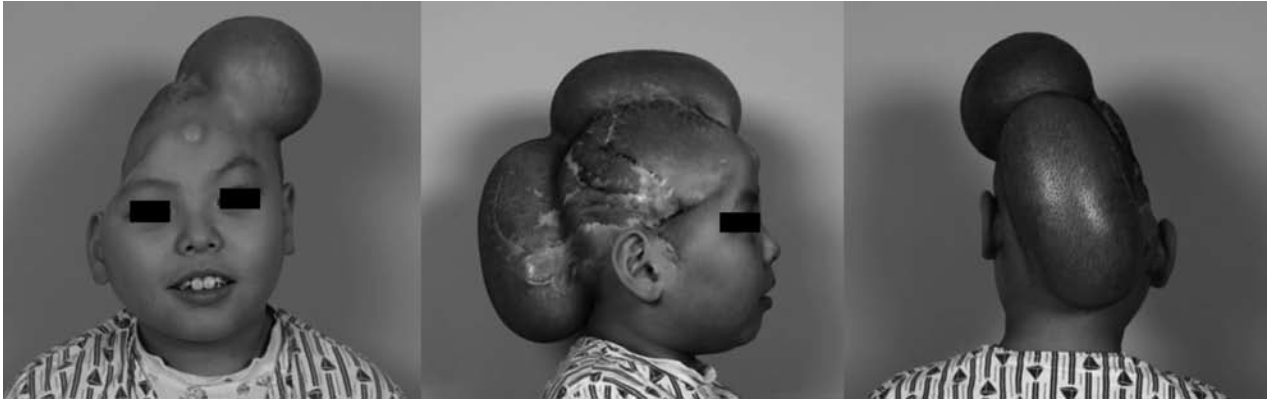

Figure 3. Preoperative views of the head show fully expanded scalp flaps

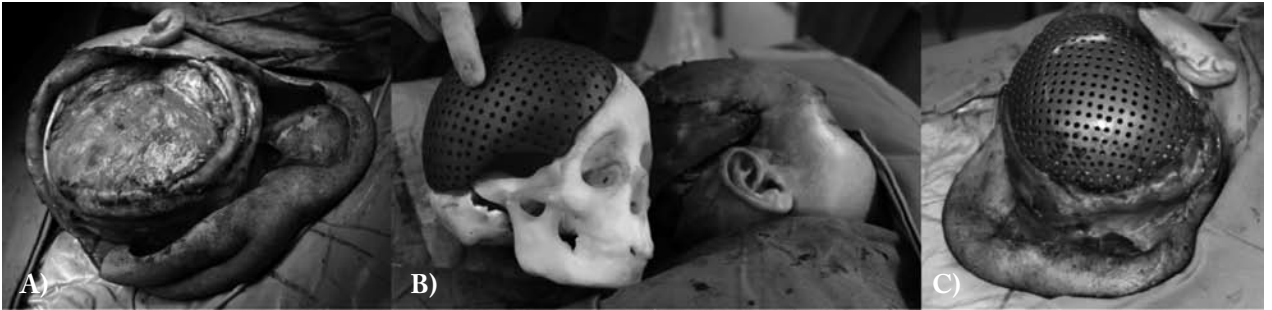

Figure 4. Intraoperative views. A: The expanders were removed and dissection was finished. B: The individualized titanium prosthesis on the top of a skull model. C: The prosthesis was fixed on the skull.

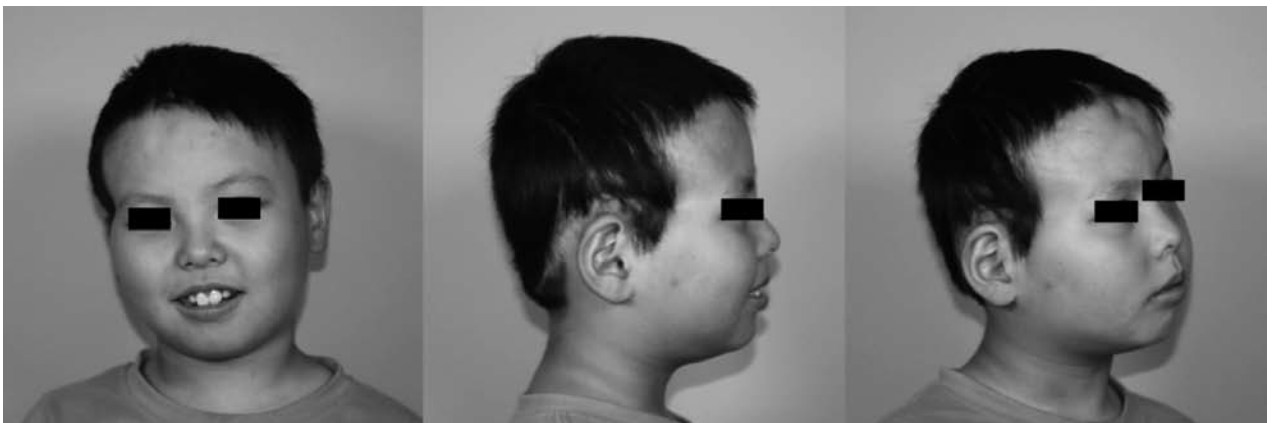

Figure 5. Views of the patient one year after reconstruction showed cosmetically pleasing results

## Discussion

RE, also called chronic focal encephalitis, was first described by Rasmussen in 1958 (1). A rare disorder in children, RE presents with intractable epilepsy and progressive neurological deficits. RE is characterized by chronic inflammation and subsequent destruction of the affected cerebral hemisphere. Several pathological causes have been postulated, such as viral infection, circulating autoantibodies, and T-cell-mediated cytotoxic effects (2). Hemispherectomy is highly indicated to achieve seizure control, which renders the patient seizure free but leads to a severe neurologic deficits. The cranium is of great importance in protecting and maintaining intracranial pressure, and the large defects following craniectomies, which are often greater than 100 cm<sup>2</sup>, removes the protective barrier to the brain, causing it to shift and collapse, thus, impairing neurologic functions. Prompt repair not only avoids brain injury from external forces, but also eliminates contraction from postoperative scars.

Autogenous or alloplastic materials are widely used these days. Based on the 'full coverage cranioplasty' principle, the most standard material has proved to be a free osteo-muscular flap for cranial vault reconstruction, especially in the setting of a chronic infectious process (3). The procedure carries the risks of substantial dural exposure or loss, increased operating time, soft tissue dissection and potential donor-site morbidity (4). However, a combination of autologous and alloplastic materials is currently also regarded as a main method for cranioplasty (5). Titanium is a non-ferromagnetic metal of low atomic number, and it is the most biocompatible metal known and is widely used with minimal morbidity and moderate complications (6). 3D CT reconstruction technique spatially and precisely present the defect and its relationship to its surroundings. An individualized titanium prosthesis based on 3D CT reconstruction technique provides anatomically precise and symmetric repair. For children, things are much more complicated because of the expected growth and development of the brain. For our patient, the protocol was chosen on the basis of avoiding the risk of leakage of cerebrospinal fluid, shortening the operation time, preventing donor-site morbidity and improving cosmetic

results. With regards to the potential space beneath the titanium prosthesis, we prepared two plates. One was in exact symmetry to the contralateral side, while the other had a slightly less concave curvature. A relatively large space provides a site for fluid accumulation and bacterial proliferation. During the operation, the former one was estimated to be a more suitable fit. To accommodate for the natural growth of the skull, only the frontal and superior borders of the prosthesis were fixed.

Tissue expanders are widely used by plastic and reconstructive surgeons for providing additional cutaneous tissues. Owing to the hard base of the skull, the scalp is an ideal region for expansion. Large congenital nevi, scars, and skin graft alopecia are main indications for scalp expansion. Nevertheless, it is still an uncommonly-used technique by neurosurgeons (7, 8). Flaps are designed with consideration to the superficial temporal and occipital arteries. Expansion itself enhances vascularity, so relatively larger flaps are reliable. For expander placement, a pocket plane beneath the galea but above the periosteum is preferred. When performing dissection, the importance of hair follicle protection cannot be overemphasized. During the 4-month expansion process, flaps should be carefully and frequently monitored, for a tiny injury may compromise the entire flap. Adequate expansion is assessed by a full evaluation of the two sides. Optimal preoperative expansion is achieved when flaps are large enough to assure a tension-free closure after the resection of scars. A tissue expander allows for delayed hair-bearing scalp flaps that may fully cover the defect and form a relatively symmetrical hairline contour.

To the best of our knowledge, this is the first instance where tissue expanders have been used in a case of a complicated cranial defect in a child following craniostomy. Thanks to careful postoperative care and rehabilitation, no complications were detected. In our one-and-half-year follow-up, the patient showed significant improvement in learning ability, body coordination, flexibility and muscle strength. Although the findings of cognitive and motor ability analysis are coherent with some reports (9), the evidence is not convincing enough (10). The titanium prosthesis will need to be replaced when the patient reached adulthood.

## References

1. Rasmussen T, Olszewski J, Lloydsmith D. Focal seizures due to chronic localized encephalitis. *Neurology* 1958; 8: 435-45.
2. Thilo B, Stinge R, Knudsen K, et al. A case of Rasmussen encephalitis treated with rituximab. *Nat Rev Neurol* 2009; 5: 458-62.
3. Georgescu AV, Ivan O. Serratus anterior-rib free flap in limb bone reconstruction. *Microsurgery* 2003; 23: 217-25.
4. Brevi BC, Magri AS, Toma L, et al. Cranioplasty for repair of a large bone defect with autologous and homologous bone in children. *J Pediatr Surg* 2010; 45: E17-20.
5. Thesleff T, Lehtimäki K, Niskakangas T, et al. Cranioplasty with adipose-derived stem cells and biomaterial: a novel method for cranial reconstruction. *Neurosurgery* 2011; 68: 1535-40.
6. Josan VA, Sgouros S, Walsh AR, et al. Cranioplasty in children. *Childs Nerv Syst* 2005; 21: 200-4.
7. Miyazawa T, Azuma R, Nakamura S, et al. Usefulness of scalp expansion for cranioplasty in a case with postinfection large calvarial defect: a case report. *Surg Neurol* 2007; 67: 291-5.
8. Oritano TC, Izquierdo R, Scannicchio LB. Reconstructing complex cranial defects with a preformed cranial prosthesis. *Skull Base Surg* 1995; 5: 109-16.
9. Agner C, Dujovny M, Gaviria M. Neurocognitive assessment before and after cranioplasty. *Acta Neurochir (Wien)* 2002; 144: 1033-40.
10. Stelling H, Graham L, Mitchell P. Does cranioplasty following decompressive craniectomy improve consciousness? *Br J Neurosurg* 2011; 5: 407-9.

Accepted: 21th april 2013

Correspondence: Xiaojun Wang, M.D.  
Department of Plastic Surgery of  
Peking Union Medical College Hospital,  
Damucang No. 41, Xicheng District,  
Beijing 100032, China  
E-mail: xjwang100@hotmail.com