

## Imaging of a small bowel cavernous hemangioma: report of a case with emphasis on the use of computed tomography and enteroclysis

*Antonella Corsi<sup>1</sup>, Anna Ingegnoli<sup>1</sup>, Pietro Abelli<sup>2</sup>, Flavia De Chiara<sup>2</sup>, Cristina Mancini<sup>3</sup>, Giulia Martina Cavestro<sup>4</sup>, Libera Fanigliulo<sup>4</sup>, Francesco Di Mario<sup>4</sup>, Angelo Franzè<sup>5</sup>, Maurizio Zompatori<sup>1</sup>*

<sup>1</sup>Department of Clinical Sciences, Section of Radiology, University of Parma; <sup>2</sup>Department of Radiology and Diagnostic Imaging, Parma Hospital; <sup>3</sup>Pathology Section, Department of Pathology and Laboratory Medicina, University of Parma; <sup>4</sup>Chair of Gastroenterology, Department of Clinical Sciences, University of Parma; <sup>5</sup>Gastroenterology and Endoscopy Unit, Parma Hospital, Parma, Italy

**Abstract.** Hemangiomas of the small bowel are rare benign tumors, that are dangerous since they may cause massive or occult gastrointestinal bleeding. We describe a case of a jejunum cavernous hemangioma detected by computed tomography (CT) and barium studies. An abdominal CT scan (with intravenous contrast agent) depicted a pronounced contrast enhanced lesion arising from the front wall of a loop of the proximal ileum. Enteroclysis revealed a small intramural nodular defect. ([www.actabiomedica.it](http://www.actabiomedica.it))

**Key words:** Cavernous hemangioma-jejunum-bleeding –CT- barium examination

### Introduction

Hemangiomas of the small intestine are uncommon benign tumors, and may cause massive or occult gastrointestinal bleeding.

The age at diagnosis ranges from 5 to 25 years, occasionally presenting with gastrointestinal (GI) bleeding. Historically hemangiomas of the small bowel are difficult to differentiate from other more common entities.

We report a case of a small bowel cavernous hemangioma causing massive gastrointestinal hemorrhage, that presents the characteristic imaging features for an accurate imaging study.

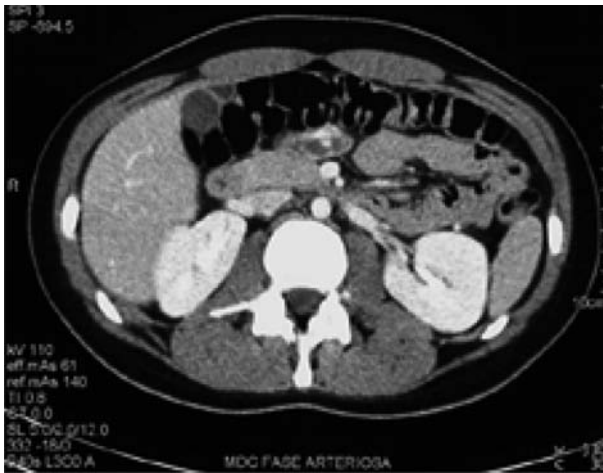### Case report

A 22-year-old female patient with a known history of dysmenorrhoea suddenly developed dyspepsia, alimentary vomiting, and a lipotimic event. Two days

later she was hospitalized because of weakness, black stools, and anemia (Hb 9 g/dl; normal 12-16 g/dl). On admission, physical examination was negative for an abdominal palpable mass. The patient denied non-steroidal anti-inflammatory drug assumption.

Esofagogastroduodenoscopy was performed and revealed antral gastritis but did not identify a site of bleeding, despite the continuous presence of melanoctic stools. On the second day, her clinical condition became severe with profuse weakness, vertigos, tinnitus, abundant melena, with a hemoglobin level of 6.1 g/dl. She was immediately transfused and an emergency abdominal CT was performed.

The diagnostic considerations included: a neoplasm (small bowel tumor, lymphoma), Merckel diverticula, and a vascular lesion. The CT scan (6 slides, with and without contrast agent) showed a non homogeneous contrast enhancement at the level of the jejunum walls (Fig. 1). A thickened wall of the involved GI segment was also documented. The Hounsfield absorption values were compatible with angio-



**Figure 1.** Contrast enhanced CT scan shows thickening of the jejunum with a heterogeneous and persistent enhancement of the lesion.

mathosis (not containing phleboliths). This area had a maximum measure of 3 x 1 cm. There was no evidence of tumor invasion to the adjacent organs, liver metastases, ascites, intestinal obstruction, or perforation. No intra or retroperitoneal lymphadenopathies were detected.

An enteroscopy was also performed approximately until 50 cm distal to the Treitz ligament but no source of bleeding was found.

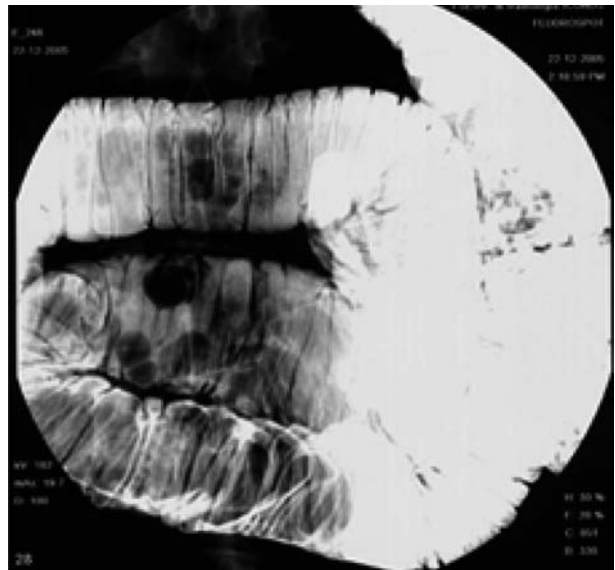
Barium examination, however, showed small lacunar imaging on antimesenteric depositor of the right mean jejunal loop. This nodular defect was compressible, collapsing after air insufflation (Figs. 2-3).

The patient was consequently prepared for elective laparotomy and segmental jejunum resection. At the opening of the specimen a brown nodule of 1x 0.9x 0.6 cm size was present. Histopathologic evaluation revealed dilated structures, lined by flat endothelial cells.

Histological diagnosis of a cavernous hemangioma was made (Fig. 4). The postoperative course was regular.

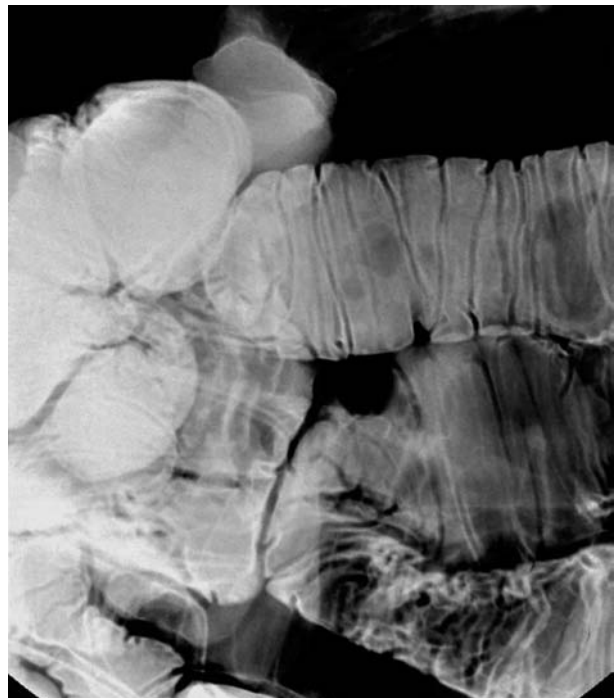
## Discussion

Hemangiomas are defined as masses of capillaries, blood-filled endothelial-lined spaces, or a combi-

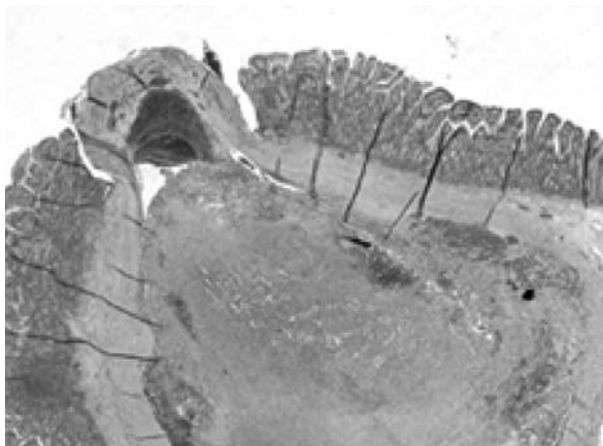


**Figure 2.** Examination of upper GI tract demonstrates a large, submucosal nodular lesion.

nation of these. Hemangiomas of the GI tract are uncommon, accounting for only 0,05% of all intestinal neoplasms and 7-10% of all benign tumors of the



**Figure 3.** The lacunar lesion was compressible, collapsing after air insufflation.



**Figure 4.** Photomicrograph (original magnification, x 10; hematoxylin-eosin stain). Histopathologic evaluation documents erosion of the the hemangioma surface.

small bowel (1). These tumors may be solitary or multiple. Multiple hemangiomas are usually associated with various cutaneous vascular lesions or syndromes including: blue rubber bleb syndrome (characterized by cavernous haemangiomas of the skin and GI tract, and other viscera); Maffucci syndrome (enchondromas, subcutaneous cavernous hemangiomas); Klippel-Trénaunay-Weber syndrome (limb hypertrophy, cutaneous hemangiomas and varicosities) (2-4). Intestinal hemangiomas have also been reported in Peutz-Jeghers syndrome (5).

Cavernous hemangiomas are considered as progressive intestinal hamartomas (6). Macroscopic examination reveals bluish purple, soft structures. Inside the hemangiomas an extensive network of vascular lakes also involving the intestinal wall is found to be present; microscopic analysis shows submucosal large, thinwalled vessels (7).

The histological aspect is represented by cystic spaces lined by endothelial cells, which are immunoreactive for VIII factor and negative for keratin (8). Commonly situated in the middle jejunum, hemangiomas are rarely found in other locations of the GI tract. Intestinal hemangiomas are usually soft and polypoid; they vary in size from a few millimeters to infiltrative polypoid masses that are several centimeters long. Phleboliths are common (they may be seen in the radiograph of the abdomen), although absent in our case. The majority of GI tract hemangiomas are of

the cavernous type. They usually diffusely infiltrate the bowel wall and may expand into the mesentery, retroperitoneum, or pelvic walls. Alternatively they can appear as small, discrete, submucosal nodules confined to a small segment or can be widely distributed throughout the GI tract.

A recent classification system, based on histological appearances, was suggested by Abrahamson and Shandling. It divides intestinal hemangiomas into the following three categories: the first type, the capillary hemangioma, described as a small tuft of sub-mucosal capillaries that expand intraluminally and may develop into a stalk-like mass; the second type, represented by mixed capillary and cavernous hemangioma; the third and the most common type, which is the cavernous hemangioma (9). Differentiation between the three types is possible, although radiographically difficult.

Ninety percent of hemangiomas are clinically evident, presenting with symptoms such as either acute or chronic GI hemorrhages, anemia, obstruction, and rarely platelet sequestration (1,9-13). Other potentially serious complications may occur: intussusception, small bowel obstruction, perforation, malabsorption, or bleeding from other sites of involvement (10, 11). It is of paramount importance to recognize hemangiomas in order to decide the most appropriate treatment.

Diagnosis can be obtained by multiple radiologic studies.

On simple/basic/straightforward radiograph of the abdomen, the visualization of phleboliths is an important diagnostic criterion, that is observed in 26-50% of adult patients, but their absence does not exclude the diagnosis (12). Phleboliths are secondary to venous thrombosis within the tumor, caused by perivascular inflammation and stasis of blood flow (14). Simple abdominal radiographs may also reveal obstruction or evidence of perforation.

Double contrast barium study demonstrates nodular defect, which may change configuration after compression or distention, suggesting a soft and possibly vascular tumor (7, 15, 16). Barium detection studies depend on the size of the hemangiomas and on the active peristalsis of the intestine (9).

A CT is frequently used as a front line tool in the evaluation of abdominal symptoms: the initial choice

is often the radiologic work-up, especially in critical patients. CT scan shows transmural thickening of the wall of the involved bowel loops, with a non homogeneous and persistent enhancement of the lesion (after injection of contrast medium). CT also identifies the phleboliths. In our case the CT proved to be helpful in identifying a non palpable, intraabdominal and exophytic mass of the small intestine. CT should therefore be joined to enteroclysis in the evaluation of small intestine hemorrhage (17, 18).

Magnetic resonance (MRI) shows wall thickening of the involved GI segment and demonstrates heterogeneous bright signal intensity on T2-weighted images, more clearly depicted with fat suppression. Calcifications are usually signal-voided on both T1 and T2 weighted images. Trombosed vessels are depicted as serpiginous structures with high signal intensity on MRI. The advantage of MRI is that it can provide detailed, multiplanar anatomical images, and it can also specifically detect a hemangioma and demonstrate blood flow without the need for contrast medium (19, 20).

On endoscopy, cavernous hemangiomas appear as dilated submucosal varicosities, ranging in color from deep wine to plum, associated with mucosal congestion, that may collapse with air insufflation. Endoscopy of the upper and lower gastrointestinal tract is necessary in the work-up, but frequently this technique only provides a suggestion of a mass lesion, and is limited in evaluating the small intestine.

Angiography shows mural hypervascularity with delayed venous pooling.

The use of radionuclide imaging, performed with tagged red blood cells, may be helpful in patients with intestinal bleeding.

Arteriography with the option of embolization should only be used in cases of highly acute bleeding that cannot be locally suppressed (21, 22).

Capsule endoscopy is a noninvasive tool for imaging the entire small intestine and is used especially for recurrent episodes of digestive bleeding (23).

The final diagnosis is made by resection and direct histologic examination. Treatment of symptomatic patients is laparotomy and resection (24, 25).

The main radiologic differential diagnosis for jejunum submucosal nodular defects includes leiomyo-

ma and metastasis; the final diagnosis is solved only by histological examination of the resected specimen.

## Conclusions

Hemangioma of the small intestine is a rare entity, but important source of GI tract bleeding.

Since the main symptoms of hemangioma are not specific, the clinical diagnosis is often delayed and an early detection implies a proper radiologic diagnostic work-up radiograph, barium enema, and CT (26, 27).

## References

- Boyle L, Lack EE. Solitary cavernous hemangioma of small intestine. Case report and literature review. *Arch Pathol Med Lab* 1993; 117: 939-41.
- Golitz LE. Heritable cutaneous disorders which affect the gastrointestinal tract. *Med Clin North Am* 1980; 64: 829-46.
- Mako EK. Small-bowel hemangiomatosis in a patient with Maffucci's and blue-rubber-bleb-nevus syndromes. *Am J Roentgenol* 1996; 166: 1499-500.
- Wilson CL, Song LM, Chua H, et al. Bleeding from cavernous angiomas of the rectum in Klippel-Trénaunay syndrome: report of three cases and literature review. *Am J Gastroenterol* 2001; 96 (9): 2783-8.
- Bandler M. Hemangiomas of the small intestine associated with mucocutaneous pigmentation. *Gastroenterology* 1960; 38: 641-5.
- Lyon DT, Mantia AG. Large bowel hemangiomas. *Dis Colon Rectum* 1984; 27: 404-14.
- Abrahamson J, Shandling B. Intestinal hemangiomas in childhood and a syndrome for diagnosis: a collective review. *J Pediatr Surg* 1973; 8 (4): 487-95.
- Coppa GF, Eng K, Localio SA. Surgical management of diffuse cavernous hemangioma of the colon, rectum and anus. *Surg Gynecol Obstet* 1984; 159: 17-22.
- Enzinger FM, Weiss SW. Soft tissue tumors. 3rd ed. St. Louis, Mo: Mosby-Yearbook 1995; 679-89.
- Magnano A, Privitera A, Calogero G, Nanfitò L, Basile G, Sanfilippo G. Solitary hemangioma of the small intestine: an unusual cause of bleeding diagnosed at capsule endoscopy. *J Pediatr Surg* 2005; 40(10):25-7.
- Schwartz GD, Barkin JS. Small bowel tumors. *Gastrointest Endosc Clin N Am* 2006; 16 (2): 267-75.
- Tanaka N, Onda M, Seya T, Furukawa K, Kumazaki T. Diffuse cavernous hemangioma of the rectum. *Eur J Surg* 1999; 165: 280-3.
- Blank KI, Abney HT, MacGregor AMC, Hawkins EF. Hemangiomatosis of the colon and anorectum: case report and a review of the literature. *Am Surg* 1974; 40: 626-35.

14. Lappas JC. Benign tumors. In: Gore RM, Levine MS, Laufer I, eds. *Textbook of gastrointestinal radiology*. Philadelphia, PA: Saunders 1994; 892-9.
15. Dachman AH, Ros PR, Shekikta KM, Buck JL, Olmsted WW, Hinton CB. Colorectal hemangioma: radiologic findings. *Radiology* 1988; 167: 31-4.
16. Ghahremani GG, Kangarloo H, Volberg F, Meyers MA. Diffuse cavernous hemangioma of the colon in the Klippel-Trenaunay syndrome. *Radiology* 1976; 118: 673-8.
17. Perez C, Andreu J, Liauger, Valls J. Hemangioma of the rectum: CT appearances. *Gastrointest Radiol* 1987; 12: 347-9.
18. Davy Miallou C, Bellin MF, Bousquet JC, Guinet C, Grellet J. Rectosigmoid hemangioma. Specific aspects in x-ray computed tomography. Apropos of a case. *J Radiol* 1990; 71: 199-202.
19. Maglante DD, Kelvin FM, O'Connor K, Lappas JC, Chernish SM. Current Status of small bowel radiography. *Abdom imaging* 1996; 21: 247-57.
20. Yorozya K, Watanabe M, Hasegawa H, et al. Diffuse cavernous hemangioma of the rectum: report of a case. *Surg today* 2003; 33: 309-11.
21. Mellish RWP. Multiple hemangiomas of the gastrointestinal tract in children. *Am J Surg* 1971; 121: 412-7.
22. Tokiwa k, Iwai N, Michiata T, Kinugasa A. Arteriovenous malformation of the jejunum in a child. *J Pediatr Surg* 1989; 24: 311-2.
23. Gay G, Delvaux M, Rey J-F. The Role of Video Capsule Endoscopy in the Diagnosis of Digestive Diseases: a review of Current Possibilities. *Endoscopy* 2004; 36 (10): 913-20.
24. Cuffy M, Abir F, Longo WE. Management of less common tumors of the colon, rectum, and anus. *Clin Colorectal Cancer* 2006; 5: 327-37.
25. Varela Gutiérrez G, Cervera Servin JA, Fernandez Sobrino G, Rodriguez Delgado NA, Flores Armenta J, Robles C. Cavernous hemangioma of the colon. Case report and review of the literature. *Rev Gastroenterol Mex* 2004; 69: 94-9.
26. Jafri SZ, Bree RL, Glazer GM, Francis IR, Schwab RE. Computed tomography and ultrasound findings in Klippel-Trénaunay-syndrome. *J Comput Assist Tomogr* 1983; 7: 457-60.
27. Gill SS, Heuaman DM, Mihas AA. Small intestinal neoplasm. *J Clin Gastroenterol* 2001; 33: 267-82.

---

Accepted: 24<sup>th</sup> April 2007

Correspondence: Corsi Antonella, MD

Department of Clinical Sciences,

Section of Radiology, University of Parma

Tel. 3333230722

E-mail: antonellacorsi4@libero.it, www.actabiomedica.it