

C A S E R E P O R T

Pseudohypoparathyroidism: a diagnosis to consider once a PTH elevation is detected

Ilaria Brambilla¹, Federico Rossi², Carmelo Pistone¹, Amelia Licari^{1,2}, Maria De Filippo², Martina Votto², Enrico Tondina², Carmen Guarracino¹

¹Pediatric Clinic, Fondazione IRCCS Policlinico San Matteo, Pavia, Italy; ² Department of Clinical, Surgical, Diagnostic and Pediatric Sciences, University of Pavia, Pavia, Italy

Abstract. *Background and aim:* Pseudohypoparathyroidism (PHP) is a rare disease, which can occur in the youth, characterized by hypocalcemia and hyperphosphatemia due to resistance to parathyroid hormone (PTH) in target organs. This condition encompasses different conditions which differ between one another by different clinical, biochemically, and genetic features. *Methods:* Herein we report the clinical history of a boy with PHP1B with an interesting clinical presentation. He came in fact to the attention of the Emergency Department because of a spontaneously resolving epileptic attack, lasting about 15 minutes, characterized by loss of consciousness, fall to the ground, tonic-clonic shocks, and sphincter release. Moreover, the personal history was characterized by congenital long QT syndrome (LQTS), with a documented mutation of the KCNQ1 gene, treated with beta-blockers (nadolol). *Results:* The simultaneous presence of symptomatic acute hypocalcemia and long QT syndrome undoubtedly required particular attention both in the management of the onset and in the more in-depth subsequent diagnostics. In this regard, laboratory tests and molecular analyzes have proved to be crucial in the diagnostic process. *Conclusions:* this case underlines the diagnostic path complexity in patients with PTH elevation and the importance of considering all the possible differential diagnoses in order to undertake a timely and correct course of treatment. (www.actabiomedica.it).

Key words: pseudohypoparathyroidism, pediatric, parathyroid hormone resistance

Introduction

Case presentation

We report the case of a 14-year-old boy, who came to the attention of the Emergency Department because of a spontaneously resolving epileptic attack lasting about 15 minutes, characterized by loss of consciousness, fall to the ground, tonic-clonic shocks, and sphincter release. The boy reported cramp-like muscle pains and occasionally diarrhea for several weeks: no family or personal history of epilepsy. In the emergency room, vital parameters were stable, Glasgow Coma Scale was equal to 14/15. The personal history

was characterized by congenital long QT syndrome (LQTS), with a documented mutation of the KCNQ1 gene, treated with beta-blockers (nadolol).

At the admission, blood tests were performed, and no elevation of the inflammatory indices was found, with an adequate renal function; conversely, it was documented severe hypocalcemia (calcium ion equal to 0.79 mmol/l and total calcium equal to 5.9 mg/dl), hyperphosphatemia (8.2 mg/dl) and an increased alkaline phosphatase value (428 mU/ml). A screening electrocardiogram was performed, with normal findings and no QT prolongation documented. The electroencephalographic record showed findings compatible with the post-critical state and anomalies

attributable to severe hypocalcemia. A brain computed tomography was performed, and no pathological signs were documented. In the emergency room, intravenous hypocalcemia with calcium gluconate was taken. The patient underwent the continuous intravenous infusion of calcium gluconate already set up and, after four days, the maintenance therapy was progressively shifted to an oral replacement therapy with calcium carbonate and calcitriol. After stabilizing the clinical conditions, laboratory investigations were conducted for a better diagnostic definition of the calcium-phosphoric disorder, and reductions in calcium and phosphate values were detected.

Furthermore, markedly increased parathyroid hormone values (386.1 pg/ml) were found, with only a slight insufficiency of vitamin D (25-OH vitamin D equal to 27 ng/ml), tubular reabsorption of phosphates equal to 99.7%, and no signs of hypomagnesemia.

In addition, it was performed an ultrasound of the neck, which did not detect any pathological sign in the parathyroid glands, and complete abdomen ultrasound, which did not detect any alterations in the kidney and urinary tract.

These data allowed us to exclude some of the leading causes of hypocalcemia (tubulopathies, hypercalciuric hypoparathyroidism, deficient rickets, hypomagnesemia, activating mutations of the calcium receptor) and to suspect the pseudohypoparathyroidism.

In this regard, some of the main endocrinopathies associated with pseudohypoparathyroidism were therefore sought (resistance to TSH, glucagon, gonadotropins, ACTH, and GHRH), with the exclusive finding of a slight elevation of the TSH levels (5.8 mIU/L) with normal fT₄, in the absence of symptoms of hypothyroidism.

With the suspicion of PHP, no phenotypic characteristics of Albright's hereditary dystrophy were detected, such as short stature, rounded facies, mental retardation, brachydactyly, or obesity.

The radiological evaluation of the various skeletal segments reported an increased cortex thickness and a slight reabsorption appearance of the bone trabeculae. However, bone densitometry showed a Z-score within the normal limits for the patient's age. The X-ray of the forearm and leg also reported a Madelung deformity and bilateral tibial procurvatum.

The patient was then discharged with the indication to continue replacement therapy with calcium and calcitriol. At the periodic checks during the follow-up started at the Endocrinology Clinic, the laboratory and instrumental tests have always been within the normal limits.

The molecular analysis of the GNAS gene did not reveal any alteration with a pathological correlation, so the genetic study was extended to the regions upstream of this gene, which instead documented a methylation defect of the exon A/B pathogenetic a pseudohypoparathyroidism Ib (PHP 1b). In particular, the genetic analysis reported a methylation index <0.30 (equal to 0.00 in our patient). The subsequent extension of the molecular analysis to the parents and the sister did not reveal any alteration in the methylation of exon A/B, reporting a methylation index of 0.99.

The parents provided written informed consent.

Discussion

Parathyroid disorders are a rare condition in the pediatric population, especially those involving an elevation of PTH (1,2). The case reported here showed that a PTH elevation must be finely analyzed to differentiate more common disorders, such as primary hyperparathyroidism, from more unusual ones, such as pseudohypoparathyroidism. PHP encompasses a group of rare and highly heterogeneous disorders characterized by the peripheral resistance to the action of PTH due to various molecular anomalies that affect the signaling pathway, in which the α -subunit of the stimulatory G protein ($G_s\alpha$) is the genetic defect responsible for this syndrome (3,4). As such, these disorders mimic hypoparathyroidism since many patients experience the symptoms of hypocalcemia and hyperphosphatemia: the first manifestation of our case, as reported above, was, in fact, a seizure attack due to severe hypocalcemia.

Although the similarity with hypoparathyroidism, characterized by the hallmark low level of PTH, PHP manifests high levels of PTH in the absence of vitamin D deficiency or other electrolytes imbalances, which could explain unexpected hypocalcemia, such as hypomagnesemia (5). Since the diverse conditions can be considered under the term pseudohypoparathyroidism,

in 2016, the European consortium for PHP proposed a new classification based on the underlying genetic mechanisms (iPPSD: inactivating PTH/PTHrP signaling disorder) rather than phenotypes, which were historically used to classify these disorders (3).

Moreover, this classification includes six main categories:

- 1) iPPSD1 is characterized by a loss-of-function of PTH receptor (6,7),
- 2) iPPSD2 is characterized by a loss-of-function of the GNAS gene,
- 3) iPPSD3 is characterized by a methylation defect of the GNAS gene (8),
- 4) iPPSD4 is characterized by a mutation of the PRKAR1A gene (9),
- 5) iPPSD5 is characterized by a mutation of the PDE4D gene (10), and
- 6) iPPSD6 is characterized by a mutation of the PDE3A gene (11).

With many disorders considered by this classification, the most relevant in terms of occurrence is certainly iPPSD2 and iPPSD3: the first group encompass PHP1A(12), PHP1C (13,14), pseudo pseudohypoparathyroidism (PPHP) (15), and progressive osseous heteroplasia (POH) (16), and the second group includes PHP1B (8,17). Among these, PHP1 is the most common.

The three disorders included in the PHP1 definition manifest a peripheral PTH resistance. However, they can be distinguished by the tissues involved¹⁸: PHP1A and PHP1C exhibit a broader hormone resistance (renal cortex, thyroid, gonad, and pituitary tissues) compared to the isolated PTH resistance in the kidney of PHP1B.

Even if PHP1A and PHP1C have in common the loss-of-function of the GNAS gene, in PHP1C patients, a normal Gsa activity can be detected in “in vitro” assays (13).

These disorders are phenotypically different. PHP1B, unlike PHP1A and PHP1C, does not express the AHO (Albright hereditary osteodystrophy) phenotype, characterized by short stature, obesity, round face, short neck, brachydactyly, and shortened metatarsals, and frequently below normal intelligence (19). An additional feature associated with PHP1A and PHP1C patients is the several hormone resistanc-

es that could develop during the years, such as TSH, GHRH, and LH/FSH (1).

As noticed, pseudohypoparathyroidism is a group of disorders that slightly differ, so the management and the clinical and molecular characterization vary among these conditions.

As described above, once a calcium-phosphorus imbalance is detected, the biochemical analysis should evaluate if any other alteration can be detected.

Thus, vitamin D metabolites (25OHD and 1,25(OH)₂), PTH, alkaline phosphatase, renal function, urine, and serum electrolytes should be analysed (1,18). This analysis will help to differentiate the different disorders which can encompass hypocalcemia: low PTH could suggest disorders such as gain of function CaSR gene mutations, syndromic disorders (DiGeorge syndrome, Kenny-Caffey syndrome, Sanjad-Sakati syndrome), electrolytes imbalances, such as hypomagnesemia, or acquired conditions, such as granulomatous and infiltrative diseases. On the other hand, an elevation of PTH, following a hypocalcemia detection, is highly suggestive for the pseudohypoparathyroidism (PHP) spectrum of disorders. Along with the biochemical characterization of the hypocalcemia, as our case highlighted, a severe degree of calcium reduction needs an electrocardiogram assessment to evaluate the presence of a prolonged QT interval and, as such, the risk for dangerous arrhythmias. Once the biochemical tests assessed that the PTH elevation is not due to a secondary cause, such as a vitamin D deficiency or secondary hyperparathyroidism (ex. renal failure), the confirmation of a PHP needs: phenotypic and genetic evaluation (1,3).

The EuroPHP network group has classified three major criteria (PTH resistance, ectopic ossification, and brachydactyly type E) and six minor criteria (TSH resistance, other hormonal resistances, such as LH/FSH and IGF-1, motor and cognitive impairment, obesity, round face, and intrauterine and postnatal growth retardation) (3). To suspect a diagnosis of iPPSD is mandatory at least one major criterion among the ones they have proposed. As such, our case presented only one major criterion, the PTH resistance, which has made us suspect the PHP. Thus, as previously mentioned, the several PHP subtypes can be further subdivided genetically: a positive molecular test provides an essential confirmation of the clinical

suspicion, sorting the patient out in the right iPPSD category.

Hence, following the biochemically and phenotypically assessment, our case was tested, with evidence of a loss of methylation at the GNAS locus, confirming the clinical suspicion and diagnosing a PHP1B case (iPPSD3).

To date, no prospective clinical trials have been conducted in inpatient patients with PHP focusing on treating these disorders. Thus, the management of these patients aims to resolve each single biochemical or clinical problem with a specific intervention. Conversely to other disorders of the PHP spectrum, PHP1B shows fewer clinical difficulties. The primary intervention to focus on in this PHP subset is the management of the PTH resistance: very few studies emphasize their analysis on this topic, so the current view is to aggressively treat this biochemical alteration using active vitamin D metabolites (calcitriol) and oral calcium supplements (1,20). This approach aims to reduce the serum level of PTH to the upper part of the reference range, firstly to avoid suppression of PTH, which can be associated with hypercalciuria and renal

calcification, and secondly to avoid the detrimental effects on skeletal mineralization of a constant high PTH concentration. Hence, measurement of PTH, calcium, and phosphorus should be performed regularly to modulate the oral vitamin D and calcium supplement, along with a regular appropriate renal imaging to evaluate nephrocalcinosis (1).

Lastly, early-onset obesity is a critical issue to tackle in PHP1B patients, even if not as severe as in PHP1A patients: regular monitoring of BMI and eating routine control is recommended to prevent detrimental complications such as heart attack disease and impaired glucose metabolism (21-23).

As noted in the previous paragraphs, the disorders that underlie PTH elevation are various and different, and the correct characterization of these disorders always needs genetic confirmation. In Fig. 1, we have visualized a simple flowchart for PHP disorders.

Although this group of disorders is quite rare in the pediatric population, it is essential to consider such conditions once an elevated PTH concentration is revealed. Early recognition is vital for the correct management of these syndromes, especially those that

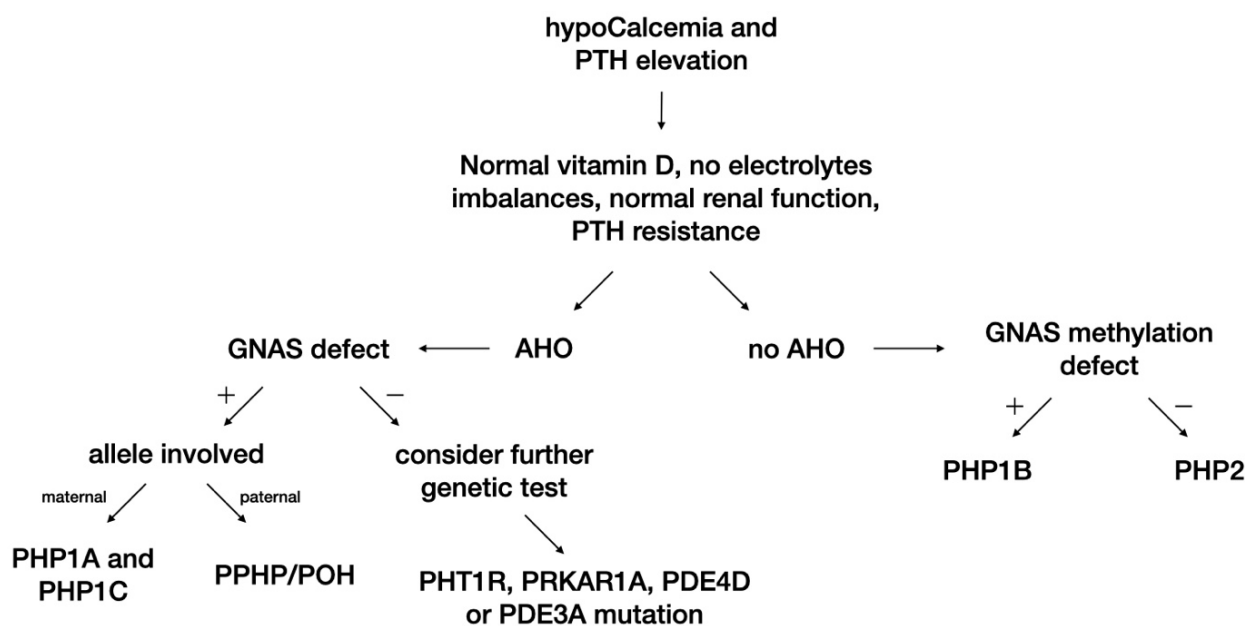


Figure 1. Proposed algorithm for PHP disorders.

PTH: parathyroid hormone, AHO: Albright hereditary osteodystrophy phenotype; GNAS: G protein alpha subunit gene; PHP: pseudohypoparathyroidism; PPHP: pseudopseudohypoparathyroidism; POH: progressive osseous heteroplasia; PTH1R: PTH receptor gene; PRKAR1A: a regulatory subunit of the protein kinase A gene; PDE4D: phosphodiesterases 4D gene; PDE3A: phosphodiesterases 3A gene.

need a periodic and continued evaluation, such as in our case.

Conflict of Interest: Each author declares that they did not have commercial associations that might pose a conflict of interest in connection with the submitted article.

References

- Mantovani G, Bastepe M, Monk D, et al. Diagnosis and management of pseudohypoparathyroidism and related disorders: first international Consensus Statement. *Nat Rev Endocrinol.* 2018;14(8):476-500.
- Belcher R, Metrailler AM, Bodenner DL, et al. Characterization of hyperparathyroidism in youth and adolescents: A literature review. *Int J Pediatr Otorhinolaryngol.* 2013;77(3):318-22.
- Thiele S, Mantovani G, Barlier A, et al. From pseudohypoparathyroidism to inactivating PTH/PTHrP signaling disorder (iPPSD), a novel classification proposed by the EuroPHP network. *Eur J Endocrinol.* 2016;175(6):P1-17.
- Mantovani G, Spada A, Elli FM. Pseudohypoparathyroidism and Gs α -cAMP-linked disorders: Current view and open issues. *Nat Rev Endocrinol.* 2016;12(6):347-56.
- Linglart A, Levine MA, Jüppner H. Pseudohypoparathyroidism. *Endocrinol Metab Clin North Am.* 2018;47(4):865-88.
- Cheloha RW, Gellman SH, Vilardaga J-P, et al. PTH receptor-1 signalling—mechanistic insights and therapeutic prospects. *Nat Rev Endocrinol.* 2015;11(12):712-24.
- Kosugi S, Inoue S, Matsuda A, et al. Novel, Missense, and Loss-of-Function Mutations in the Sodium/Iodide Symporter Gene Causing Iodide Transport Defect in Three Japanese Patients. *J Clin Endocrinol Metab.* 1998;83(9):3365-8.
- Liu J, Litman D, Rosenberg MJ, et al. A GNAS1 imprinting defect in pseudohypoparathyroidism type IB. *J Clin Invest.* 2000;106(9):1167-74.
- Linglart A, Menguy C, Couvineau A, et al. Recurrent PRKAR1A Mutation in Acrodysostosis with Hormone Resistance. *N Engl J Med.* 2011;364(23):2218-26.
- Michot C, Le Goff C, Goldenberg A, et al. Exome Sequencing Identifies PDE4D Mutations as Another Cause of Acrodysostosis. *Am J Hum Genet.* 2012;90(4):740-5.
- Maass PG, Aydin A, Luft FC, et al. PDE3A mutations cause autosomal dominant hypertension with brachydactyly. *Nat Genet.* 2015;47(6):647-53.
- Elli FM, DeSanctis L, Ceoloni B, et al. Pseudohypoparathyroidism Type Ia and Pseudo-Pseudohypoparathyroidism: The Growing Spectrum of GNAS Inactivating Mutations. *Hum Mutat.* 2013;34(3):411-6.
- Brix B, Werner R, Staedt P, et al. Different Pattern of Epigenetic Changes of the GNAS Gene Locus in Patients With Pseudohypoparathyroidism Type Ic Confirm the Heterogeneity of Underlying Pathomechanisms in This Subgroup of Pseudohypoparathyroidism and the Demand for a New Classification. *J Clin Endocrinol Metab.* 2014;99(8):E1564-70.
- Thiele S, de Sanctis L, Werner R, et al. Functional characterization of GNAS mutations found in patients with pseudohypoparathyroidism type Ic defines a new subgroup of pseudohypoparathyroidism affecting selectively Gs-receptor interaction. *Hum Mutat.* 2011;32(6):653-60.
- Turan S, Thiele S, Tafaj O, et al. Evidence of hormone resistance in a pseudopseudohypoparathyroidism patient with a novel paternal mutation in GNAS. *Bone.* 2015;71:53-7.
- Lebrun M, Richard N, Abeguile G, et al. Progressive Osseous Heteroplasia: A Model for the Imprinting Effects of GNAS Inactivating Mutations in Humans. *J Clin Endocrinol Metab.* 2010;95(6):3028-38.
- Linglart A, Gensure RC, Olney RC, et al. A Novel STX16 Deletion in Autosomal Dominant Pseudohypoparathyroidism Type Ib Redefines the Boundaries of a cis-Acting Imprinting Control Element of GNAS. *Am J Hum Genet.* 2005;76(5):804-14.
- Germain-Lee EL. Management of pseudohypoparathyroidism. *Curr Opin Pediatr.* 2019;31(4):537-49.
- Albright F, Burnett CH, Smith PH, et al. Pseudohypoparathyroidism — an example of 'Seabright-Bantam syndrome.' *Endocrinology.* 1942;(30):922-32.
- Bollerslev J, Rejnmark L, Marcocci C, et al. European Society of Endocrinology Clinical Guideline: treatment of chronic hypoparathyroidism in adults. *Eur J Endocrinol.* 2015;(173):G1-20.
- de Lange IM, Verrijn Stuart AA, van der Luit RB, et al. Macrosomia, obesity, and macrocephaly as first clinical presentation of PHP1b caused by STX16 deletion. *Am J Med Genet Part A.* 2016;170(9):2431-5.
- Rahmat N, Venables P. Sinus pauses and high-grade atrioventricular block in Albright's hereditary osteodystrophy with pseudopseudohypoparathyroidism. *Case Reports.* 2013; bcr2013010116.
- Chen M, Gavrilova O, Liu J, et al. Alternative Gnas gene products have opposite effects on glucose and lipid metabolism. *Proc Natl Acad Sci.* 2005;102(20):7386-91.

Received: 29 March 2022

Accepted: 5 April 2022

Correspondence:

Ilaria Brambilla, MD, PhD

Pediatric Clinic, Fondazione IRCCS Policlinico San Matteo

Piazzale Golgi n°19

Pavia, 27100 Italy

Phone: 0382502732

E-mail: i.brambilla@smatteo.pv.i