

Case series of four complex spinal deformities: new frontiers in pre-operative planning

Giulia Facco¹, Rosa Palmisani¹, Massimiliano Pieralisi², Archimede Forcellese², Monia Martiniani³, Nicola Specchia¹, Antonio Gigante¹

¹Department of Clinical and Molecular Sciences, Università Politecnica delle Marche, Ancona, Italy; ²Department of Industrial Engineering and Mathematical Sciences, Università Politecnica delle Marche, Ancona, Italy; ³Clinic of Adult and Paediatric Orthopaedics, Ospedali Riuniti, Ancona, Italy.

Abstract. *Background and aim:* Osseous and medullar anomalies constitute a hard challenge for interpretation of complex vertebral deformities anatomy. To better frame these deformities three-Dimensional (3D) printing represents a new frontier in this field. The aim of this brief report is describing the use of 3D printed models for surgical planning in four complex vertebral deformity cases treatment. *Methods:* Four cases of severe scoliosis were treated between December 2017 and January 2019; patients' mean age was 12,25 years. Two patients underwent neurosurgical intervention for myelomeningocele at the time of birth. Standard and dynamics X-Ray, Computed Tomography (CT) and Magnetic Resonance (MR) of the column were performed pre-operatively. CT files were implemented to build the 3D model of each spine and selected ribs. The models were 3D printed in thermoplastic material, then used to study the deformities and for surgical planning. A survey proposal about 3D models' utility and accuracy has been made to 15 residents and 6 main surgeons. *Results:* Preparation of each 3D models required about 316.5 minutes and printing time was about 108 hours each. The average cost was 183.16 € to produce one 3D printed model, which resulted useful in surgical planning and educational. *Conclusions:* The manufacture of 3D models requires time, resources and multidisciplinary approach, it must be justified by complexity of the case. In this study 3D Printing allowed surgeons to carefully plan and simulate the surgery, ensuring for a better sizing of the implant. (www.actabiomedica.it)

Key words: 3D printing, surgical planning, complex vertebral deformities, spine, 3D model

Introduction

Complex vertebral deformities treatment in young patients is fruitfully discussed in spine surgery. The interpretation of complex vertebral deformities anatomy is challenging due to osseous and medullar anomalies. Congenital anomalies such as defects in vertebral formation and segmentation, welding defect and mixed forms could increase the difficulty. Furthermore, the choice to procrastinate the operative treatment with prolonged conservative treatment, when is ineffective especially in congenital or neuromuscular deformities may cause delay in surgery and deformity worsening. An exhaustive

physical examination, a prescription of standard and dynamics X-Rays, Computed Tomography (CT) and Magnetic Resonance (MR), as well as the gathering of patients' medical history are always necessary steps in order to assess the type of deformity and to plan the right treatment. (1) Moreover, neurophysiologic exams like somatosensory and motor evoked potentials permit to evaluate any peripheral deficit preoperatively. CT and MR can help during pre-operative planning but 2D images are often not enough when anatomy is most distorted. (2) Three-Dimensional (3D) printing represents a new frontier to understand complex anatomies (3, 4) such as spine deformities. (5) Indeed,

3D printing allows to produce patient-specific printed models (6) from CT images. (7) 3D printed model can be a useful instrument to enhance decision-making processes both for surgical planning and for clinical practice (8, 9). It allows to explain deepen the pathology to patients showing itself helpful in communication too. (10) As a matter of fact, 3D Printing has shown itself helpful in the operating room (11, 12) reducing surgery duration and intra-operative blood loss (13); moreover, it has produced better outcomes (13).

In this brief report it's outlined how to produce a 3D printed model and how 3D printing can be useful in order to assess spine complex deformities.

Methods

Case series

Four cases of severe congenital scoliosis treated using 3D printed models for the surgical planning between December 2017 and January 2019 were retrospectively reviewed. The Declaration of Helsinki as well as the Guidelines for Good Clinical Practice were applied: written informed consents for surgery, photos and clinical follow-up were all endorsed by the patient. The protocol, participant education, recruitment materials, and any subsequent modifications were reviewed and approved by the Department of Clinical and Molecular Science Board in accordance with the Policy of Clinical Orthopaedics at the Università Politecnica delle Marche in Ancona, Italy. Medical history has been collected, while physical examination, X-Rays, CT and MRI have been performed in order to assess the type of deformity and to plan the treatment (Fig. 1 a-d). Moreover, somatosensory and motor evoked potentials were performed to preoperatively evaluate any peripheral deficit. 3D printed models of each entire spine were produced and then used to study deformities and surgical planning (Fig. 1 e-f). Posterior approach has been performed in all four cases (Fig. 1 g-i). Patients' data have been collected in Table 1.

Model production

Spine scan was performed in CT machine Somatom Force (IIIrd generation, Siemens Healthineers,

Forcheim, Germany) with a thickness of 0,1 mm. Digital Imaging and COmmunications in Medicine (DICOM) files have been imported on the specific clinical commercial software Syngo.via Frontier (Siemens Healthineers, Forcheim, Germany) in order to create spine geometries. The region of interest (ROI) of each spine has been selected. Segmentation by threshold has been performed selecting range over 200 Hounsfield Unit (HU). In order to make some adjustment, such as the removal and the inclusion of ribs, manual segmentation was executed by a trained orthopaedic resident. At the end of this process, "Smoothing" function was selected at 0.2 and each elbow 3D model was exported in Stereo Lithography interface format (.STL), ready for 3D printing. The models were printed with the fused deposition modelling 3D Printer (Fortus 250 mc Stratasys Ltd., Minnesota, America). They were printed in scale 1:1 in Acrylonitrile Butadiene Styrene Plus (ABSplus - p430). Subsequently 3D printed models were processed to remove soluble support material (SR-30) using SCA-1200HT (PADT Ltd, Tempe, Arizona, USA). Production time in software environment, printing time and material costs of each 3D model have been collected.

A survey proposal about 3D models' utility and accuracy has been made to 15 residents and 6 main surgeons by asking them to split a score from 1 to 5 (1= "low"; 5= "excellent") for each of the different subjective fields: utility of 3D printed model in preoperative planning, utility of 3D printed model in educational, accuracy of 3D printed model, maneuverability of 3D printed model.

Results

Digital production of each 3D models required about 316.5 minutes (min) [minimum 226 min - maximum 483 min], and printing time was about 108 hours (h) each [minimum 41h 33min - maximum 173 h 56 min]. The average material cost to produce a 3D printed model was 183.2€ [minimum 95.5€ - maximum 307.0€].

At survey the 3D printed model resulted useful in surgical planning with a score of 3.8/5 for main surgeons and 4.6/5 for residents. About educational, 3D printed model got a mean of 4.5/5 points from

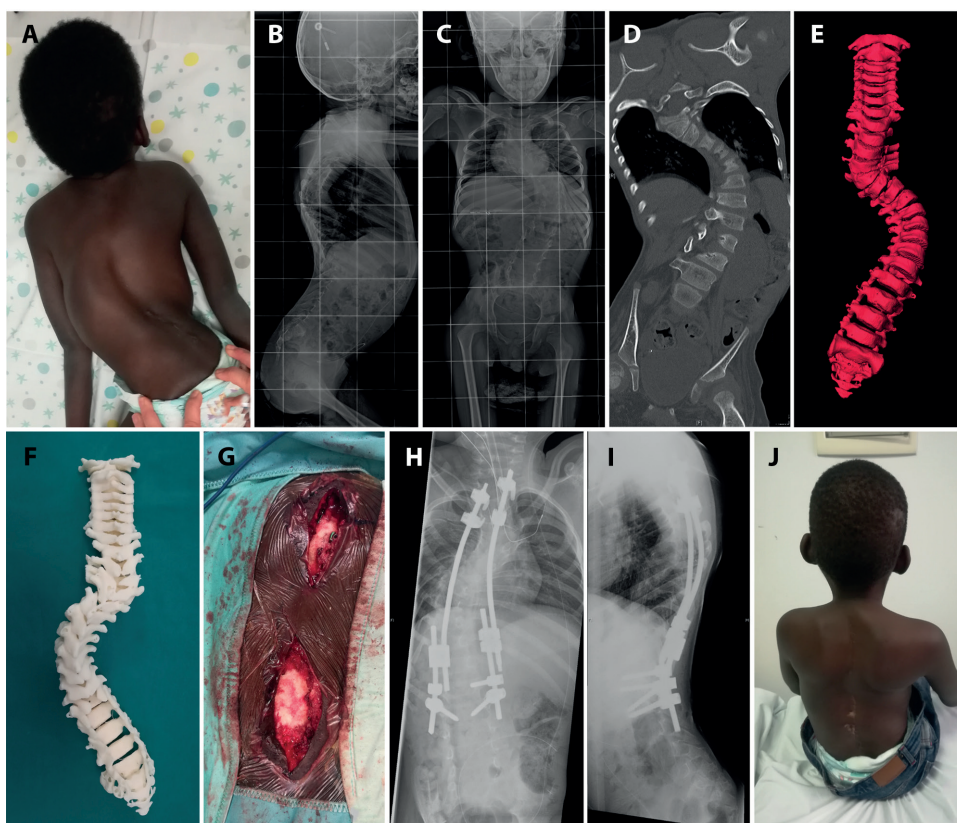


Figure 1. Patient number 2:

- a. the gravity of spine deformity at the clinical examination at presentation
- b. and c. Full-spine Radiographs at presentation
- d. TC coronal slice at presentation
- e. virtual 3D model
- f. 3D printed model
- g. operative treatment: posterior approach with two separate incisions (thoracic and lumbar)
- h. and i. post-operative X-Rays showing fixation of T2-L2 with screws, hooks and subsfacial traditional growing rods and arthrodesis T2-T4 and L1-L2.
- j. clinical outcome with improvement of sitting position.

main surgeons and 4.9/5 from residents. It was accurate (main surgeons: 4.7/5 points, residents: 4.6/5) but low handy (main surgeons: 2.7/5 points, residents: 2.6/5).

Discussion

Charles Hull in 1986 brought the idea of 3D Printing, which was implemented in clinical practice for custom prosthetics and dental implants by the beginning of XXI Century (3). Many improvements in surgical planning were allowed by the introduction of 3D Printing in medicine: applications have

raised, thanks to technologies simplification, opening new possibilities for a successful costs' reduction (14). Unfortunately, 3D printing still requires specific knowledges and high costs, (15) yet entailing several advantages, such as the reduction of blood loss, ionizing radiation, (16) and surgery time (11, 16) and improvement of surgical outcomes (15). The manufacture of 3D models must be justified by complexity of the case like in case of complex vertebral deformities. Approximately 8% of all literature concerning rapid prototyping describes 3D Printing use specifically for spine surgery, thanks to the advancement of this technology (2). Sakai et al. illustrated a surgical planning

Table 1. Patients' history and treatment. T: Thoracic; L: Lumbar.

Patient	1	2	3	4
Age	5	7	11	26
Sex	F	M	F	M
Cobb degree	87°	75°	45°	Dorsal 120°lumbar 100°
Kyphosis	42°	35°	42°	43
Lordosis	22°	24°	40°	50
Risser	0	0	0	5
Curve type	Congenital high thoracic left scoliosis.	Congenital thoraco-lumbar left scoliosis (Fig 1 a-f)	Congenital thoracic left scoliosis	Thoracic right curve and lumbar left curve scoliosis
Osseous anomalies	Hemivertebra T3 Butterfly vertebrae T5, T6, T7, T9 and T11.	T7 pedicle absence T2-T3-T4 congenital bar Hemivertebra T5 Schisis of multiple vertebral posterior arches (Fig 1b-f)	Hemivertebra T9	-
Medullar anomalies	Thoracic meningocele Lumbar syringomyelia Diastematomyelia	Lumbosacral myelomeningocele	-	-
Clinical issues	-	Arnold- Chiari II malformation	-	Kidney failure Saldino Mainzer Syndrome
Surgery	Convex spinal epiphysiodesis T3 and T6 Posterior unilateral arthrodesis T2-T8 using hook instrumentation and 1 rod.	Fixation of T2-L2 with screws, hooks and subfascial traditional growing rods Arthrodesis T2-T4 and L1-L2 (Fig. 1g-i)	Hemivertebra Egg-shell osteotomy, Posterior arthrodesis T8-T10 using hooks, screws and 2 rods system.	Posterior arthrodesis T2-L5 using hooks, screws, Universal camps, 2 rods instrumentation

using 3D printing technology in a 12-year-old boy (referred because of C1–C2 instability due to os odontoideum) in their case report. A preoperative reduction of C1–C2 using the halo vest was performed, with posterior interlaminar fixation which gave good outcomes. (17) Gadiya et al. in their technical note explained how to produce a 3D printed spine model with its pedicle screw templates for a revision pediatric kyphoscoliosis surgery where metal artifacts and “Pseudoforamina” (defects in the CT image due to thin bone for the previous surgery) can make it more difficult to understand the pathology in exam (18). Salazar et al. illustrated the use of a 3D printed model of a complex schwannoma for the preoperative planning before the resection surgery. The success of the operation has been attributed by the surgeon to the additional knowledge derived by observation of the 3D printed model (19). Karlin et al. reported their experience in pediatric preoperative planning in spinal deformity with myelomeningocele using 3D models. The authors compared surgical outcomes of two groups (the first more complex with 3D printed model surgical planning and the second without it). As results: the fluoroscopic use and blood loss were similar between the two groups. 3D modelling introduction permitted to locate altered anatomies which were undiagnosed on traditional imaging and to shape the rods based on the 3D model, thus changing the operative plan as a result of the model and saving operative time (20). In the present case series, 3D Printing helped surgeons in careful surgery planning and simulation, ensuring better results in practice. This technique permitted to appreciate altered anatomy like in patient number 2 where T7 pedicle absence was undiagnosed without the patient’s 3D model. In addition, the necessity of pre-operative CT in order to produce 3D Printed models avoids patients’ exposition to additional studies or ionizing radiations. There were no complications related to implanted systems showed by patients treated using 3D printed model for surgical planning. The complication reported included one case of infection of the surgery wound. Given that it is not concluded whether the 3D printing model improved these parameters or not, a good research enhancement proposal may consist in reaching a better data analysis.

As survey answers pointed out, 3D model was useful and accurate for surgical correction and for

pre-operative planning. Despite of the flaw in the thermoplastic used to build the model (which did not reproduce the elastic response of the spine), 3D printing permitted to deeply understand the spine morphology and train on its model.

Conclusions

In conclusion, 3D printed models obtained by CT revealed themselves extremely useful for preoperative planning, ensuring for a better sizing of the implant and allowing a better understanding of deformities both for main surgeons and residents.

Acknowledgements: The authors would like to thank Health Physics Department, Ospedali Riuniti di Ancona for the support in 3D model production process.

Conflict of interest: Each author declares that he or she has no commercial associations (e.g. consultancies, stock ownership, equity interest, patent/licensing arrangement etc.) that might pose a conflict of interest in connection with the submitted article

References

1. Fessler RG, Sekhar LN. Atlas of Neurosurgical Techniques: Spine and Peripheral Nerves. Thieme; 2006.
2. Sheha ED, Gandhi SD, Colman MW. 3D printing in spine surgery. *Ann Transl Med* 2019;7:S164. <https://doi.org/10.21037/atm.2019.08.88>.
3. Facco G, Masetti D, Coppa V, et al. The use of 3D printed models for the pre-operative planning of surgical correction of pediatric hip deformities: a case series and concise review of the literature. *Acta Bio-Medica Atenei Parm* 2022;92:e2021221. <https://doi.org/10.23750/abm.v92i6.11703>.
4. Facco G, Politano R, Marchesini A, et al. A Peculiar Case of Open Complex Elbow Injury with Critical Bone Loss, Triceps Reinsertion, and Scar Tissue might Provide for Elbow Stability? *Strateg Trauma Limb Reconstr* 2021;16:53–9. <https://doi.org/10.5005/jp-journals-10080-1504>.
5. Guarino J, Tennyson S, McCain G, Bond L, Shea K, King H. Rapid prototyping technology for surgeries of the pediatric spine and pelvis: benefits analysis. *J Pediatr Orthop* 2007;27:955–60. <https://doi.org/10.1097/bpo.0b013e3181594ced>.

6. Parchi PD, Ferrari V, Piolanti N, et al. Computer tomography prototyping and virtual procedure simulation in difficult cases of hip replacement surgery. *Surg Technol Int* 2013;23:228–34.
7. Facco G, Greco L, Mandolini M, et al. Assessing 3-D Printing in Hip Replacement Surgical Planning. *Radiol Technol* 2022;93:246–54.
8. Giannetti S, Bizzotto N, Stancati A, Santucci A. Minimally invasive fixation in tibial plateau fractures using an pre-operative and intra-operative real size 3D printing. *Injury* 2017;48:784–8. <https://doi.org/10.1016/j.injury.2016.11.015>.
9. Bizzotto N, Tami I, Tami A, et al. 3D Printed models of distal radius fractures. *Injury* 2016;47:976–8. <https://doi.org/10.1016/j.injury.2016.01.013>.
10. Mitsouras D, Liacouras P, Imanzadeh A, et al. Medical 3D Printing for the Radiologist. *Radiogr Rev Publ Radiol Soc N Am Inc* 2015;35:1965–88. <https://doi.org/10.1148/rg.2015140320>.
11. Wei Y-P, Lai Y-C, Chang W-N. Anatomic three-dimensional model-assisted surgical planning for treatment of pediatric hip dislocation due to osteomyelitis. *J Int Med Res* 2019;300060519854288. <https://doi.org/10.1177/0300060519854288>.
12. Ozturk AM, Sirinturk S, Kucuk L, et al. Multidisciplinary Assessment of Planning and Resection of Complex Bone Tumor Using Patient-Specific 3D Model. *Indian J Surg Oncol* 2019;10:115–24. <https://doi.org/10.1007/s13193-018-0852-5>.
13. Yang L, Grottkau B, He Z, Ye C. Three dimensional printing technology and materials for treatment of elbow fractures. *Int Orthop* 2017;41:2381–7. <https://doi.org/10.1007/s00264-017-3627-7>.
14. Iobst CA. New Technologies in Pediatric Deformity Correction. *Orthop Clin North Am* 2019;50:77–85. <https://doi.org/10.1016/j.jocl.2018.08.003>.
15. Holt AM, Starosolski Z, Kan JH, Rosenfeld SB. Rapid Prototyping 3D Model in Treatment of Pediatric Hip Dysplasia: A Case Report. *Iowa Orthop J* 2017;37:157–62.
16. Cherkasskiy L, Caffrey JP, Szewczyk AF, et al. Patient-specific 3D models aid planning for triplane proximal femoral osteotomy in slipped capital femoral epiphysis. *J Child Orthop* 2017;11:147–53. <https://doi.org/10.1302/1863-2548-11-170277>.
17. Sakai T, Tezuka F, Abe M, et al. Pediatric Patient with Incidental Os Odontoideum Safely Treated with Posterior Fixation Using Rod-Hook System and Preoperative Planning Using 3D Printer: A Case Report. *J Neurol Surg Part Cent Eur Neurosurg* 2017;78:306–9. <https://doi.org/10.1055/s-0036-1584211>.
18. Gadiya A, Shah K, Nagad P, Nene A. A Technical Note on Making Patient-Specific Pedicle Screw Templates for Revision Pediatric Kyphoscoliosis Surgery with Sublaminar Wires In Situ. *J Orthop Case Rep* 2019;9:82–4. <https://doi.org/10.13107/jocr.2250-0685.1320>.
19. Salazar D, Huff TJ, Cramer J, Wong L, Linke G, Zuniga J. Use of a three-dimensional printed anatomical model for tumor management in a pediatric patient. *SAGE Open Med Case Rep* 2020;8. <https://doi.org/10.1177/2050313X20927600>.
20. Karlin L, Weinstock P, Hedequist D, Prabhu SP. The surgical treatment of spinal deformity in children with myelomeningocele: the role of personalized three-dimensional printed models. *J Pediatr Orthop Part B* 2017;26:375–82. <https://doi.org/10.1097/BPB.0000000000000411>.

Correspondence:

Received: 27 January, 2022

Accepted: 27 February, 2022

Giulia Facco, MD

Department of Clinical and Molecular Sciences, Università Politecnica delle Marche,
Via Tronto 10/a, 60020 Torrette di Ancona – Italy.

Phone: +39.0712206066

Fax: +39.0712206203

E-mail: g.facco@pm.univpm.it