

Buckle removal in retinal detachment surgery: a consecutive case series

Giuseppe Nuzzi, Stefania Rossi

Dept. of Ear, Tooth and Eye Sciences, Unit of Ophthalmology, University of Parma - Italy

Abstract. *Purpose:* To evaluate the outcome after buckle removal in a consecutive series of treated detachments. *Methods:* Segmental and/or encircling buckles were removed in 46 consecutive patients operated upon for rhegmatogenous retinal detachment, showing buckle extrusion, recurrent pain, and diplopia. Patients underwent a preoperative retinal examination, and a six-months postoperative follow-up. *Results:* Cryopexy of retinal breaks was performed in all 46 patients during the primary surgery. At the time of buckle removal none of the patients underwent argon-laser treatment. The removed buckling material was made of MIRAGEL® in 32 cases (74%), silicone sponge in 7 (17%), and silicone band in 4 (9%). The time between the first surgery and buckle removal ranged from 1 to 17 years (8 ± 7.5 , $M\pm SD$). Neither postoperative complications, nor recurrences of retinal detachment developed. Best corrected visual acuity remained unchanged during the follow-up. Diplopia resolved in all 4 eyes after buckle removal with no need for a strabismus operation, prismatic lenses were required in one case only. *Conclusions:* Although the absence of a control group, the adequately applied retinopexy during primary surgery could probably prevent the recurrence of retinal detachment. (www.actabiomedica.it)

Key words: Rhegmatogenous retinal detachment, buckle removal, diplopia, retinopexy, recurrence of retinal detachment

Introduction

The extrusion and infection of materials used for segmental and encircling buckling occurs in 1% of cases (1, 2). This risk increases when more than one element is used, and when the same eye undergoes multiple surgeries (1, 2). In the majority of cases, a buckle removal is sufficient to resolve the clinical situation, with a low risk of recurrence of retinal detachment (between 4% and 33%) (3).

Materials and methods

In our study, the consecutive series of patients who had undergone a scleral buckling operation for rhegmatogenous retinal detachment, were examined

before and after surgery by which the indentation material was removed between 2000 and 2005. The study was performed in accordance to the Declaration of Helsinki's principles, and all the persons gave their informed consent prior to their inclusion in the study.

Fourty-six eyes of 46 patients, had undergone surgery for rhegmatogenous retinal detachment between 1985 and 2001 and the buckle material was removed between September 2000 and November 2005, with a mean time from first surgery of 8 ± 7.5 years ($M\pm SD$). In all cases, the same surgeon (G.N.) had performed the first and second operation.

The patients were examined prior to surgery and at one and six months during follow-up.

The clinical symptoms that led to buckle removal appeared after various intervals of time, ranging from 1 to 17 years after the primary surgery.

Preoperatively and during the follow-up, visual acuity (ETDRS) and intraocular pressure were determined. In addition, in both eyes, extensive examination of ocular motility, and of the anterior and posterior segment with dilation of pupil were performed.

Preoperative drawings, intraoperative notes and clinical records from 1985 to 2001 provided details on: the type of retinal detachment, surgical technique, buckling material and the intra- and postoperative course.

Results

Three patients did not provide a complete follow-up: One patient moved to another city, the others preferred being referred to another specialist. Therefore, the study, the statistical analysis and the charts refer exclusively to the 43 eyes of the 43 patients with a complete follow-up.

The age of the patients studied varied between 24 and 76 years (58.7 ± 17.8 years; Mean \pm DS), 25 patients were female, 18 male. Two patients had suffered from a post-traumatic retinal detachment (severe bulbar contusion). The pre-surgical best corrected visual acuity in the operated eye ranged from counting fingers to 20/16.

Among the patients studied 32 (74%) were phakic, 9 (22%) pseudophakic and 2 (4%) aphakic, corrected with a corneal contact lens. Thirteen eyes (30%) had a myopia greater than 8 diopters with myopic chorioretinal atrophy. In all eyes treated retinopexy presented a sufficient scar around the breaks, the retina was attached in all four quadrants and at the posterior pole prior to removal of the buckle material.

As far as the contralateral eye was concerned, visual acuity ranged from 20/200 to 20/16; in 9 eyes a myopia greater than 8 diopters with myopic chorioretinal atrophy was present, in one eye with an additional area of untreated lattice degeneration. Two patients had suffered retinal detachment in both eyes. The former had undergone scleral buckling with cryopexy in the right eye and one year later segmental buckling, encircling and cryopexy in the left eye. This patient had undergone segmental buckle removal in his left eye four years prior to our study. However, the cutting of

the encircling band without its removal in the same eye belongs to the cases examined in our study. In this case, the culture for bacteria taken from the necrosis beneath the encircling band, revealed *Streptococcus pneumoniae*. The second patient, who was aphakic, had been treated with a segmental buckle and cryopexy in both eyes. Subsequently the buckle had to be removed from the eye which was operated on first.

The findings leading to buckle removal were (Fig. 1):

- a painful eye in 30 of the 43 eyes (70%),
- buckle extrusion in 17 eyes (40%),
- persistent conjunctivitis in 6 eyes (13%),
- diplopia in 4 eyes (9%),
- decrease of visual acuity in 1 eye (2 %). In this case, however, the symptoms the patient complained of were due to the need of a new refraction, at which a partial extrusion of the buckle was detected.

In all patients, the symptoms disappeared a few days after buckle removal.

The buckles removed were made of:

- *MIRAGEL*[®] in 32 eyes (74 %)
- silicon sponge in 7 eyes (17 %)
- silicon band in 4 eyes (9 %)

In 6 eyes (19%), all with *MIRAGEL*[®] buckles, the removal was incomplete, due to technical difficulties and the tendency of the buckle material to fragment. Three of these patients underwent a reoperation, that succeeded in removing all of the *MIRAGEL*[®] buckle material.

In our study no intraoperative nor postoperative complications occurred, and no patient developed a recurrence of retinal detachment during the follow-up.

The interval between primary surgery and buckle removal varied from 1 to 17 years, with an average of 8 ± 7.5 years (Mean \pm SD) (Fig. 2). In particular, it was between 1 and 3 years for silicon sponge buckles, between 5 and 14 years for *Miragel*[®], and between 10 and 17 years for silicon bands.

Visual acuity remained unchanged at 1 month and 6 month follow-up. At the end of follow-up, in the 43 eyes the retina had remained attached without any need for prophylaxis such as cryopexy or argon laser treatment.

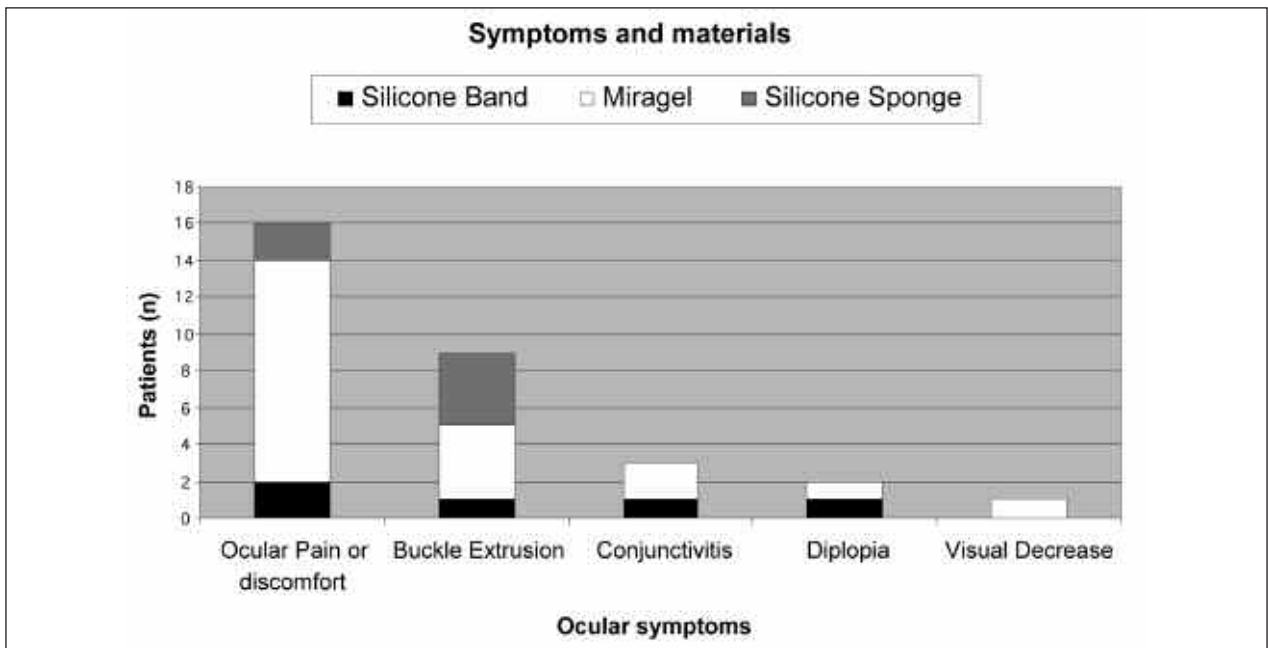


Figure 1. Ocular symptoms leading to buckle removal in relation to buckle material

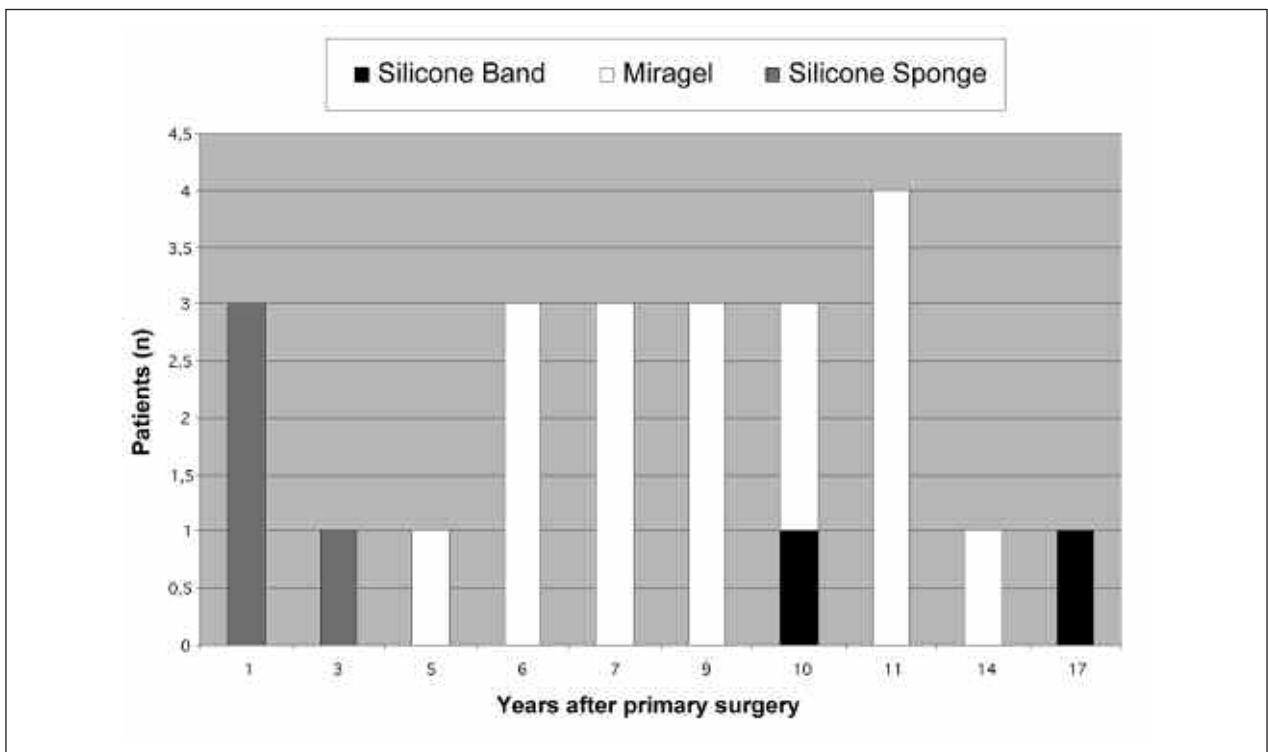


Figure 1. Interval between primary surgery and buckle removal

Discussion

Buckle extrusion, *MIRAGEL*[®] in particular, is widely reported in literature. In one publication the mean latency reported ranged at 8.3 years, varying between 6 months and 14 years [6]. The high risk of extrusion of *MIRAGEL*[®] buckles has been correlated to the great tendency of the material to hydrate, combined with alterations of its microscopic structure (4), progressive increase of volume, subsequent fragmentation and loss of indentation effect.

Of the 43 patients in the study, 32 (74%) eyes had *MIRAGEL*[®] material, 7 (17%) had silicone sponge buckles and 4 (9%) silicone bands. In 8 eyes (19%), the segmental buckle and retinopexy were combined with an encircling band. Only one of these was removed, due to evidence of necrosis.

The findings which led to the indication of buckle removal are in agreement with what is described in the literature, that means eye discomfort or ocular pain, combined with extrusion of the buckle, persistent conjunctivitis, diplopia and decrease of visual acuity (5). Unlike other studies, we did not observe any significant difference in the symptoms in relation to the buckle materials applied (6). Diplopia resolved in all eyes after buckle removal, with no need for subsequent strabismus operation. Only one eye required prisms for correction.

The time elapsing between buckle implanting and its removal varied from 1 to 17 years in our study, with the longest latency for the silicon bands, and the shortest for silicone sponge. Past studies confirm the shorter duration of silicone sponge, but identified *MIRAGEL*[®] as the material with the longest lasting indentation (6, 7). Except for one eye, it was not necessary to remove the encircling buckle combined with the scleral buckle, when present, because it was well tolerated and there were no signs of scleral erosion.

In our study, none of the patients underwent laser “prophylactic” treatment prior to buckle removal and no redetachment was observed. The operative notes show that in all eyes intraoperative cryopexy was routinely performed at the primary surgery. It’s not possible, anyway, to determine whether, in the absence of this treatment, recurrences would have occurred. In

our opinion retinopexy at the time of the primary surgery (intraoperative cryopexy) exactly placed around the break and of correct dosage could safeguard from recurrence of a retinal detachment, if it should necessary to remove the buckle material. The Retinopexy scars provide a sufficient protection against vitreo-retinal tractions on the break when the buckling effect starts to decrease. This is also the case of *MIRAGEL*[®] buckles, that hydrolyse after a few years with a resulting decrease of the indentation effect (4). A well performed cryopexy, i.e. under ophthalmoscopic control and with minimal whitening of the retina, would not increase the risk of postoperative vitreous proliferation (8), and provides an excellent protection against redetachment. At our knowledge, it has not yet been demonstrated that indentation alone can induce a retinopexic scar comparable to that caused by cryopexy or laser treatment. Moreover, at our knowledge, the literature does not indicate a safe time for buckle removal in retinal detachment surgery. The procedure appeared to be a somehow not risky for the eye, combined with a great chance that the symptoms will be resolved.

Acknowledgements

We thank Prof. Ingrid Kreissig (Mannheim, Germany) for her kind assistance during the paper revision and for her precious suggestions.

References

1. Lincoff H. Pre-operative antibiotic soaking of silicone sponges: Does it make a difference? *Ophthalmology* 1984; 91: 1689.
2. Wiznia RA. Removal of solid silicon rubber explants after retinal detachment surgery. *Am J Ophthalmol* 1983; 95: 495.
3. Lindsey PS, Pierce LH. Removal of scleral buckling elements: Causes and complications. *Arch Ophthalmol* 1983; 101: 570.
4. Oshitari K, Hida T, Okada AA. Long term complications of hydrogel buckles. *Retina* 2003; 23: 257-61.
5. Deokule S, Reginald A. Scleral explant removal: the last decade. *Eye* 2003;17: 697-700.
6. Le Rouic JF, Bettembourg O. Late swelling and removal of hydrogel buckles: a comparison with silicone indentations. *Retina* 2003; 23: 641-6.

7. Roldan-Pallares M, del Castillo Sanz JL, Awad-El Susi S, Refojo MF. Long-term complications of silicone and hydrogel explants in retinal reattachment surgery. *Arch Ophthalmol* 1999; 117 (10): 1449.
8. Avitabile T, Bartolotta G, Torrisi B, Reibaldi A. A randomized prospective study of rhegmatogenous retinal detachment cases treated with cryopexy versus frequency-doubled Nd:YAG laser-retinopexy during episcleral surgery. *Retina* 2004; 24 (6): 878-82.

Accepted: 7 July 2008

Correspondence: Giuseppe Nuzzi, MD

Associate Professor of Ophthalmology

Dept. of Ear, Tooth and Eye Sciences - Unit of Ophthalmology

University of Parma

Via Gramsci 14 - 43100 Parma (Italy)

Tel. ++39 0521 70 31 06

Fax ++39 0521 98 30 27

E-mail: nuzzi@unipr.it; www.actabiomedica.it