

Clinical and demographic profile Volkmann's ischemic contracture presenting in Tigray (Ethiopia)

Landino Cugola, Giampaolo Fasolo

Department Of Orthopedia, Kidane Mehret Hospital – Adwa (Tigray, Ethiopia)

Abstract. *Objective:* Volkmann's ischemic contracture (VIC) represents the outcome of a compartment syndrome, not adequately managed during the acute phase. It is still to be found in the developing countries, while it is rarely present in the developed countries. In this report we refer on our African experience on VIC, because we believe might be useful for last generation of Italian orthopaedics which rarely have a chance to see Volkmann's cases. *Materials and Methods:* AA. report their 2-year experience in the treatment of 16 patients aged 7 to 17, presenting various entities of Volkmann, in the Tigray (North-East of Ethiopia). According to Tsuge's classification, cases ranged from mild to moderate and severe. Surgery is the method of choice in cases of fixed and advanced VIC. Our used techniques were graded according to the severity of the deformity and namely: A) Flexor tendons lengthening; B) Superficial pro profundus flexor tendons transfer; C) Extensor tendons transfer pro flexor tendons. In some specific cases treatment was completed by means of ancillary surgery. *Results:* In all patients there has been an acceptable recovery of hand function, although the difficulty to verify the outcomes because of the scarce overlapping of the clinical status and different operations. *Conclusions:* Attentions shall be drawn to the outcomes and a healthcare education is necessary in those villages where cures are entrusted to the so-called "traditional doctors" who are nothing more than "bone-setters". (www.actabiomedica.it)

Key words: Volkmann's contracture, developing countries, tendon transfer

Introduction

Richard von Volkmann, German surgeon, described the "non-infective ischaemic conditions of various fascial compartments in the extremities", as the outcome of an acute compartment syndrome, in 1881. In 1890 Hildebrand used for the first time the term "Volkmann's contracture (VIC)" (1). A similar clinical picture was already known in ancient times, as it can be perceived in the *Corpus Hippocraticum* and in the evidences of Celso and Galeno, gladiators' doctors and even in the bas-reliefs of the pre-Columbian age in America.

In the developed countries, as well as in our hospitals, Volkmann's syndrome is completely or almost absent in the outcome phase, on the contrary it is still frequent in the developing countries. Sharma et al (2)

reported 19 cases in India in a paper dated 2012, Meena et. al. (3) referred to 16 cases in Iran in 2016, while in 2020 Saaiq (4) presented 37 cases of patients treated in the plastic surgery department of Islamabad (Pakistan) in the 3-year period 2016-2019. The last generation of Italian orthopedics might find it just in the texts. We therefore believe our African experience on VIC in Tigray-Ethiopia might be useful. Acute phase (clinical, physiopathology and treatment) will not be described in this presentation, because we believe it is already part of the orthopedics' knowledge. We focus on the clinical outcome and relevant treatment. The contracture (irreversible with an ischaemia longer than 6-12 hours-12-18) depends from the muscle replaced by fibroblastic tissue resulting in adhesions in the interested area. The fibrotic tissue shall reach maturation in 6-12 months, graduating the severity of the con-

tracture, involving the adjacent nerves either by compression or by reducing their blood flow and sliding.

Material and method

All participants provided written informed consent to participate in this study. This study was conducted under the principles of Declaration of Helsinki.

In a two-year period (2018-2019) 14 male adolescents aged 7 to 17 were operated in the hospital of the Salesian Sisters in Adwa. Besides a 28-year-old woman and a 12-year-old boy (fig. 2), snakebite victims, underwent surgery with VIC extensors. The males had fractured forearms (9) wrist (3) and supra-condyloid (2). During the acute phase they had been treated by the “bone-setters” in their villages using traditional methods and namely tight bandaging and/or the application of rudimentary sticks, such as bamboo canes, kept for several days. Patients were all from rural villages, far away from any health care structures and due to economical and/or mentality reasons do not ask for the opinion of health care operators (who normally work in cities distant from the villages).

The wide range of clinical spectrum cannot be adequately classified while it is necessary to underline that Holden divides VIC into two levels:

1. where the insult is proximal to the ischemic/contracture area;
2. the insult is located at the very area of ischemia/contracture.

Tsuge's classification shared by more AA. (Tab. 1) is based on the extension of the muscular necrosis in three different stages: “mild, moderate, severe” (Fig. 1). In our practice we kept the same three adjectives used above.

Chevol-Benkeddacke's classification (Tab. 2) used to indicate the nerves suffering has not been considered, since in the treated cases the nerves involvement was not predominant.

Zancolli's classification (5), was not taken into consideration, as it is based on the involvement of the intrinsic muscles. Literature presents a debate about the treatment timing; in our experience no such dilemma was encountered, since all cases were stabilized for long time.

Table 1. Classification according to Tsuge

MILD: DEEP FLEXOR muscles affected. No NERVE involvement.

MODERATE: the muscle bellies of the DEEP flexors, the LONG FLEXOR of the thumb and in part the SUPERFICIAL flexors are affected. Various degrees of nerve involvement.

SEVERE: degeneration of all FLEXORS with variable involvement of the extensors. Severe nerve impairment.

Table 2. Classification according to Chevrol-Benkeddache related to nerve lesions

STAGE 1 - not affecting nerves

STAGE 2 - recoverable paralysis with treatment

STAGE 3 - with partially recoverable paralysis

STAGE 4 - with final paralysis

STAGE 5 - with complete destruction of nerves

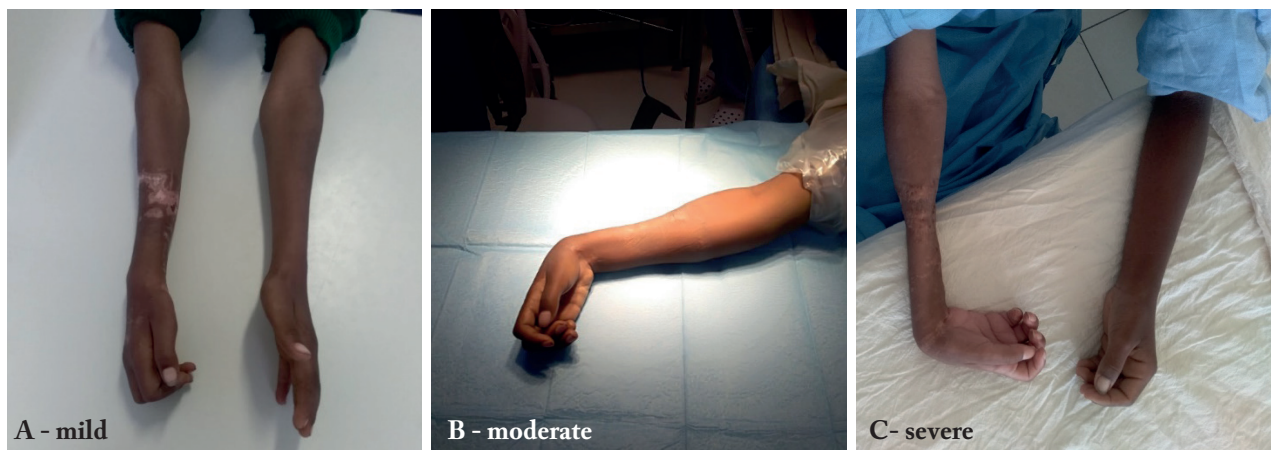


Figure 1. Clinical pictures of 3 degrees according to Tsuge: A-mild, B-moderate, C-severe

The clinic manifested different degree of presentation, with typical appearance of the claw hand, fingers retraction and wrist in flexion, sometimes with forearm in pronation, passively quite mobile, (rigidity was present only in those cases with fracture of the wrist), with a different degree of suffering at the median and ulnar nerves. Only one case with VIC mixed with intrinsic retraction did we find. In some patients with severe symptoms the forearm was even 3, 4 centimeters shorter.

In the two snakebite cases, retraction was evident in the extensor tendons (Fig. 2).

Surgery was performed under plexus anesthesia with standard volar incision and excision of necrotic tissue, if present. Techniques were placed according to the degree of contracture

- Z-type flexor tendons lengthening (in 4 “moderate” patients, Fig. 4);
- proximal heads of the superficial flexors pro distal stumps of profundus flexors transfer (in 8 moderate < > severe cases, Fig. 3);
- transfer of carpi radialis long extensor pro deep flexors fingers and BR pro FLP (2 moderate-severe cases).

In two moderate cases, the treatment had started with epitrochlear muscle dissection, according to Page-Scaglietti’s technique (6-7), without obtaining a

satisfactory release of the contracture, and then flexor lengthening was also performed.

In a 9-year-old patient with severe wrist stiffness, a proximal carpectomy was also performed, and in another 17-year-old patient, wrist arthrodesis was performed for outcomes of a badly consolidated fracture.

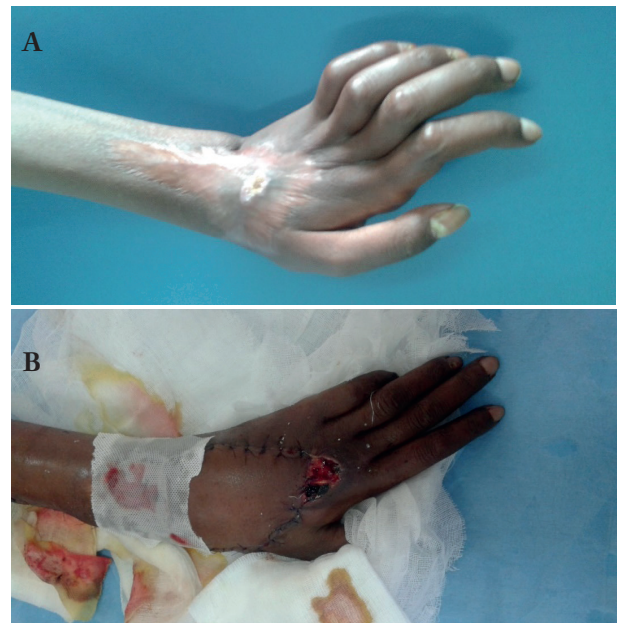


Figure 2. Dorsal VIC: A-clinical presentation; B-after operation with Chinese graft.

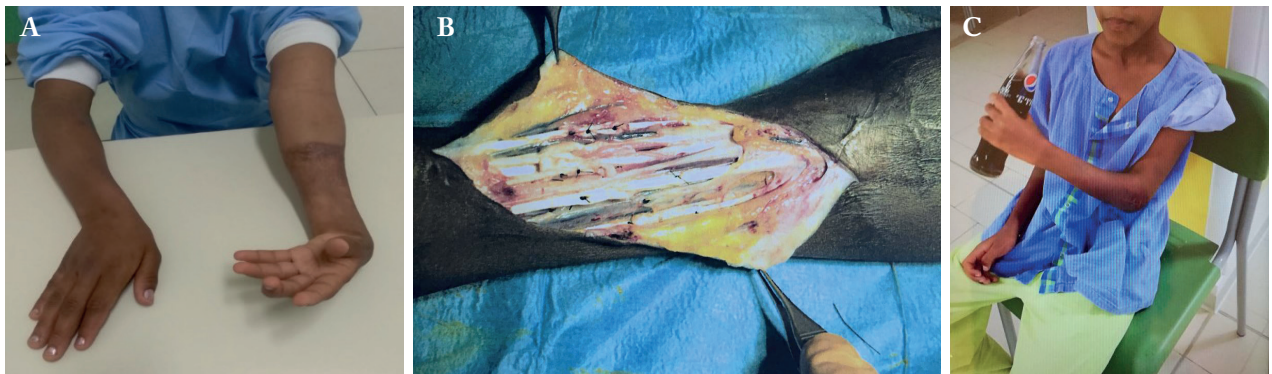

Figure 3. Moderate case treated by FDS pro FDP transfer: A-preoperative, B-intraoper., C-Result.

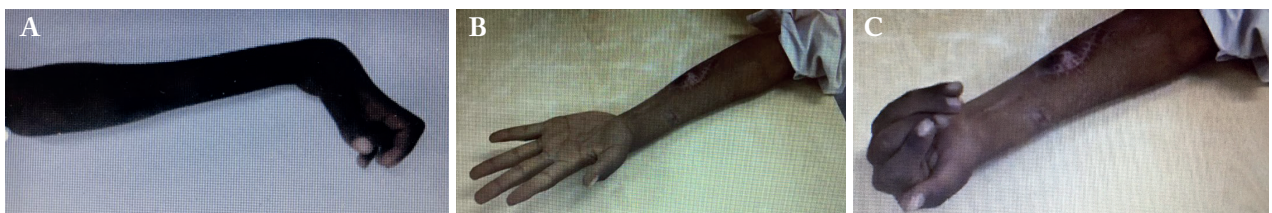

Figure 4. Moderate case treated by FDS and FDP lengthening: A-clinical presentation, result in B and C.

When necessary, the surgical time was completed with ancillary interventions: neurolysis, opening of the carpal tunnel and/or of the round pronator canal or pronator dissection. In the two patients with VIC of the extensor tendons from snakebite, after removal of the skin scar tissue, the extensors were Z-lengthened and covered with Chinese flap (Fig. 2).

The average length of time for interventions was around one and half hour.

Postsurgical plaster was applied on forearm-hand for 3-4 weeks and then re-habilitation, keeping a splint overnight until stabilization of the result. During this period, if no complications intervened, intermediate treatments were not considered.

Results

Although it is difficult to verify the results because of the scarce overlapping of the clinical pictures and the different operations, in all an improving modification of the deformity aspect with an acceptable recovery of the hand function in a useful range of flexion-extension of the fingers and of wrist and grip was encountered (Fig. 3). Sensibility also benefited (which, as mentioned, was never greatly compromised, limiting treatment to neurolysis). These observations were based on patients' statements about their ability to perform daily activities compared with pre-treatment. The preoperative manual dexterity was limited to the ability to perform a hook grip, following the procedures most patient were able to perform almost all grip types. Subjective improvement in dexterity evaluated on the basis of 10 a grade scale amounted to 6.5 (2,3 before operation). In conclusion, outcomes depended on the residual muscle spared from the insult of trauma and the set of treatment procedures combining excision of necrotic tissue, tenolysis and tendon transfers, and surgical operations on the carpal bones. Some patients were not followed as planned and therefore not monitored for a final result, as they lived in villages far from the health facility and did not have adequate means of transport and, it seems, in accordance with the fatality of this population that is still satisfied (or resigned) with an improvement of any entity pre-surgery state.

Discussion

In developing countries, the frequency of VIC is found more in forearm fractures: Grottkau (8) in 2005 reported 74% of forearm fractures compared to 15% of supracondylar fractures. Saaq in 2020 also reports an 84% rate of forearm fractures. While in not recent publications, supracondylar fractures prevail: Mubarak et al. (9) and in the classic texts of Tubiana and Malek (10) (90% vs 5%), and Dimeglio (11) (40% vs 25%). Also Manktelow (12) in a 1991 paper reports 7 cases treated in the Hospital for Sick Children in Toronto. This discrepancy probably relates to improved orthopedic treatments in developed countries for supracondylar fractures, using pins or K-wires and plaster with elbow to 90° (Bae et al. (13), while in developing countries the treatment is done with the rudimentary means available in rural areas, making tight "bandages" that involve intense pain, "stoically" endured, not having alternatives and/or qualified remedies. Patients who had sustained wrist fractures presented a VIC classifiable between moderate and medium, since, it was reported, the bandage did not affect the entire forearm but only distally from the elbow to the hand, thus saving the muscles proximally.

In literature, in each of the techniques some critical elements are reported, such as the Z-lengthening of the flexors, which can lead to the formation of intra-tendinous synechiae, resulting in unsatisfactory results (14). Extensor tendons transfer often do not work because of various complications of graft incorporation in an ischaemic area with considerable scarring. Regarding Page-Scaglietti's technique, several AA. admit the onset of secondary contractures in adolescents still in skeletal development (14, 15) in addition the inevitable deterioration of the already weak collateral blood supply of the ischaemic muscles if an epitrocleotomy is even performed. In vascularized free muscle transplantation (16) there is the necessity of a complicated double procedure, i.e. harvesting a muscle and implanting it with two team in addition to the difficulty of giving adequate tension to enable a good range of motion of the fingers, the occurrence of secondary contractures, a long period of reinnervation and possible atrophy of the muscle belly : technique that in developing countries is difficult to be performed.

There are few references in literature about Francesco Colzi 's technique, modified by Domanasiewicz (17): it consists in shortening the radius at the 3rd proximal and the ulna at the 3rd distal and intramedullary osteosynthesis with Rush's nail, in order to loosen the contracture. Some reference can be found in Fontaine's (18) and Pavanini's papers(19), the last reports a case of an 8-year-old boy with a very satisfactory result. But we in no case used this technique because in literature overall poor outcomes are reported.

In literature it is reported that the number of additional operations and revision procedures ranges between 2.5 and 5.6 per patient; in our experience we have performed only one intervention, conditioned by local contest and in some cases, as mentioned, the patient had accepted the outcome and was satisfied with it.

Conclusions

Our experience on VIC is in line with studies published by authors from other developing countries. The prevalence for the male sex is justifiable by the fact that boys more than females are involved in outdoor activities such as games and services to support family work.

The frequency of VIC in developing countries is rightly considered a catastrophe. Local health institutions and volunteer physicians in these countries should inform local health services about this problem and create effective education to ensure proper treatment of upper limb trauma mostly for the youth population.

Conflicts of interest: Each author declares that he or she has no commercial associations (e.g. consultancies, stock ownership, equity interest, patent/licensing arrangement etc.) that might pose a conflict of interest in connection with the submitted article.

Ethical statement: This paper does not require ethics committee approval.

References

1. Jepson P. Ischaemic contracture. Experimental study. *Ann Surg* 1926; 84(6): 785-93.
2. Sharma P, Swamy MK. Results of the Page muscle sliding operation for the treatment of Volkmann's contracture of forearm. *J Orthop Traumatol* 2012; 13: 189-96.
3. Meena DK, Thalanki S, Patni P, Meena RK, Bairawa D, Bhatia C. Results of neurolysis in established upper limb Volkmann's ischemic contracture. *Indian J Orthop* 2016; 50: 602-9.
4. Saaq M. Clinical and demographic profile of Volkmann's ischemic contracture presenting national institute of rehabilitation medicine, Islamabad, Pakistan. *World J Plast Surg* 2020 may; 9(2): 166-73.
5. Zancolli E. Classification of established Volkmann's ischemic contracture and the program for its treatment. In: Zancolliu E, editor. *Structural and Dynamic Bases Of Hand Surgery*. Philadelphia: JB Lippincot; 1979.
6. Page CM. An operation for relief of flexion contracture in the forearm. *J Bone Joint Surgery* 1923; 5: 233-4.
7. Scaglietti O. Sindromi cliniche immediate e tardive da lesioni vascolari nelle fratture degli arti. *Riforma Med* 1957; 71: 749-55.
8. Grottkau BE, Epps HR, Di Scala C. Compartment syndrome in children and adolescent. *J Pediatric Surg* 2005; 40: 678-82.
9. Mubarak SJ, Carroll NC. Volkmann's contracture in children: aetiology and prevention. *JBJS* 1979; 61B: 285-93.
10. Tubiana R, Malek R. Syndrome de Volkmann. *Enc Med Chir Appareil Locomoteur* 31812-44440, 1978.
11. Dimeglio A. *Ortopedia Pediatrica* 1993; 103-9. Verduci Ed.
12. Manktelow R, Egerszegi EP, Manktelow RT, McLeod A, Candlish S. Volkmann's ischemic contracture in Children: the results of free vascularized muscle transplantation. *Microsurgery* 1991; 12: 341-5.
13. Bae DS, Kadiyala RK, Waters PM. Acute compartment syndrome in children: contemporary diagnosis, treatment and outcome. *J Pediatric Orthop* 2001; 21: 680-8.
14. Mahmood H, Hussain A. Volkmann ischemic contracture due to traditional practice. *Eur J Trauma Emerg Surg* 2009 Jun; 35(3): 314-7.
15. Holden CE. The pathology and prevention of Volkmann's ischemic contracture. *J Bone Joint Surg Br* 1979; 61B: 296-300.
16. Chuang DC. Functioning free-muscle transplantation for the upper extremity. *Hand Cl.* 1997; 13: 279-89.
17. Domanasiewicz A, Jabłęcki J, Kocieba R, Syрко M. Modified Colzi method in the management of established Volkmann's contracture-the experience of Trzebnica Limb Replantation Center. *Ortopedia Traumatologia Rehabil* Jan-Febr 2008; 10(1): 12-25.
18. Fontaine R, Muller JN, Montorsi W. Diaphyseal resection of the forearm in the therapy of inveterate Volkmann's syndrome in children and adults: eight cases. *Rev Chir Or-*

- thop Reparatrice Appar Mat 1953; 39 (1): 120-37.
19. Pavanini G, Volpe A. Diaphysary resection using Colzi's method in the treatment of Volkmann's syndrome. Clin Orthop 1975; 26: 287-92
 20. Chevrol-Benkeddache Y. In : Tubiana Red, Traité de Chirurgie de la Main. Tome 5. Paris: Masson, 1995: 94-103.
 21. Tsuge K. Treatment of established Volkmann's contracture. J Bone Joint Surg Am 1975; 57: 925-9.

Received: 15 November 2021

Accepted: 23 December 2021

Correspondence:

Landino Cugola, MD

Clinica S. Francesco

Via Monte Ortigara, 23

Verona, 37129, Italy

Phone: 3491588751

E-mail: landino.c@hotmail.it