

R E V I E W

Osteolytic bone lesions in patients with primary myelofibrosis: A systematic review

Naim Ghazi Battikh¹, Elrazi Ali¹, Mohamed A Yassin²

¹Internal Medicine Department, Hamad Medical Corporation, Doha (Qatar); ²Department of Medical Oncology Hematology section, NCCCR, Hamad Medical Corporation, Doha (Qatar)

Abstract. Philadelphia negative myeloproliferative neoplasms (MPNs) are classically characterized by excess production of terminal myeloid cells in the peripheral blood. They include polycythemia vera, essential thrombocythemia, and primary myelofibrosis. Among this group, primary myelofibrosis is the least common and usually carries the worst prognosis. Bone involvement in primary myelofibrosis has many forms; it affects bone marrow leading to bone marrow fibrosis, it can cause periostitis, in addition to bone and joint pain. A common radiologic finding in primary myelofibrosis is the presence of osteosclerotic lesions. However, the presence of osteolytic lesions in bone imaging was described in few reports. In this review, we searched English literature using the PRISMA guidelines looking for patients with Primary myelofibrosis who had osteolytic bone lesions to assess the impact of such findings on the disease and its effect on prognosis. We found the vast majority of lesions were painful affecting most commonly the vertebral column, pelvis, and ribs, and were detected in patients above 50 years of age with no gender preference, unfortunately they represented advanced disease stages, resulting in inadequate treatment response and poor outcome. (www.actabiomedica.it)

Key words: Chronic idiopathic myelofibrosis, myelofibrosis, primary myelofibrosis, osteolytic lesion, lytic bone lesion, MPNs

Introduction

In 1879 Dr. Gustav Heuck reported the first case of myelofibrosis, Heuck described two cases of generalized osteosclerosis with remarkable hepatosplenomegaly, anemia, hyperplastic lymph nodes and extreme leukocytosis, which he called “splenic-medullary leukemia” and “pure splenic leukemia” respectively depending on his laboratory and post mortem observations (1). Later on, and exactly in 1951 Dr. William Dameshek formally classified primary myelofibrosis within myeloproliferative disorders (MPD) (2). Over a century of time, many nomenclatures have been used to describe the same entity, as agnogenic myeloid metaplasia, chronic idiopathic myelofibrosis, and osteosclerosis with splenomegaly (3), until the World

Health Organization (WHO) utilized the name of primary myelofibrosis in 2008 (4).

PMF is a monoclonal stem cell proliferation (myeloid type) that results in bone marrow fibrosis. As per the WHO 2016 classification of hematopoietic malignancies, PMF categorized within Myeloproliferative Neoplasms (MPN) (5), PMF grouped together with Polycythemia vera (PV) and Essential thrombocythemia (ET) under the name of ‘JAK2-MPNs’ to ratify the relation among those disorders, where 15 % of ET and PV patients can end up with PMF like type, called as a post-ET or post-PV myelofibrosis (6,7). PMF has male predominance with the most affected age groups between 60s to 70s (8).

According to WHO 2016 guidelines PMF divided in two subtypes, pre-fibrotic and overt fibrotic,

patients have to meet all the 3 major criteria with at least one minor criteria for diagnosis table 1 (9), in case of post-PV or post-ET myelofibrosis the criteria from the International Working Group for MPN Research and Treatment (IWG-MRT) should be followed table 2 (10).

Clinical manifestations

Fatigue represents the most common complaint (11); other symptoms like fever, weight loss, bone pain, night sweats, and pruritus are also reported (12). Classically splenomegaly presents in more than 90 % of cases, although the symptoms due to spleen

enlargement like vague pain in the left upper quadrant and early satiety are quite less common (13), remarkable hepatomegaly with or without portal hypertension noticed as well (14).

Extra-medullary hematopoiesis can take place at any stage of the disease and notably can involve any organ; for example central nervous system involvement can lead to increased intracranial pressure, altered mental status, and cord compression (15,16) similarly can lead to pleural effusion (17), and ascites (18), lymphadenopathy is not uncommon and skin manifestations have also reported (19), bone also can be affected and many reviews in the literature have described the different types of bone pathology, and concluded that osteosclerosis is the most common radiological feature, which

Table 1. 2016 World Health Organization diagnostic criteria for primary myelofibrosis

| <i>Primary myelofibrosis (PMF)</i> | | |
|------------------------------------|--|---|
| | Prefibrotic/early PMF (pre-PMF) | Overt PMF |
| Major criteria | | |
| 1 | Megakaryocytic proliferation and atypia ^b , without reticulin fibrosis > grade 1 ^c , accompanied by increased age-adjusted BM cellularity, granulocytic proliferation and often decreased erythropoiesis | Megakaryocyte proliferation and atypia ^b accompanied by either reticulin and/or collagen fibrosis (grade 2 or 3) |
| 2 | Not meeting WHO criteria for <i>BCR-ABL1</i> + CML, PV, ET, MDS, or other myeloid neoplasm | Not meeting WHO criteria for <i>BCR-ABL1</i> + CML, PV, ET, MDS or other myeloid neoplasm |
| 3 | Presence of <i>JAK2</i> , <i>CALR</i> , or <i>MPL</i> mutation or in the absence of these mutations, presence of another clonal marker ^d or absence of minor reactive BM reticulin fibrosis ^e | Presence of <i>JAK2</i> , <i>CALR</i> , or <i>MPL</i> mutation or in the absence, the presence of another clonal marker ^d or absence of evidence for reactive BM fibrosis ^f |
| Minor criteria | | |
| 1 | Presence of one or more of the following, confirmed in two consecutive determinations: | Presence of one or more of the following confirmed in two consecutive determinations: |
| | • Anemia not attributed to a comorbid condition | • Anemia not attributed to a comorbid condition |
| | • Leukocytosis $\geq 11 \times 10^9/L$ | • Leukocytosis $\geq 11 \times 10^9/L$ |
| | • Palpable splenomegaly | • Palpable splenomegaly |
| | • LDH level above the upper limit of the institutional reference range | • LDH level above the upper limit of the institutional reference range |
| | | • Leukoerythroblastosis |

Legend and notes: Table adapted from: Barbui T, et al. Blood Cancer J. 2015; 5:e337, and Arber DA, et al. Blood 2016;127:2391–2405. BM, bone marrow; CML, chronic myeloid leukemia; MDS, myelodysplastic syndrome; LDH, serum lactate dehydrogenase. ^b Small-to-large megakaryocytes with aberrant nuclear/cytoplasmic ratio and hyperchromatic and irregularly folded nuclei and dense clustering. ^c In cases with grade 1 reticulin fibrosis, the megakaryocyte changes must be accompanied by increased BM cellularity, granulocytic proliferation, and often decreased erythropoiesis (that is, pre-PMF). ^d In the absence of any of the three major clonal mutations, the search for the most frequent accompanying mutations (*ASXL1*, *EZH2*, *TET2*, *IDH1/IDH2*, *SRSF2*, *SF3B1*) are of help in determining the clonal nature of the disease. ^e Minor (grade 1) reticulin fibrosis secondary to infection, autoimmune disorder or other chronic inflammatory conditions, hairy cell leukemia or other lymphoid neoplasm, metastatic malignancy, or toxic (chronic) myelopathies. ^f BM fibrosis secondary to infection, autoimmune disorder, or other chronic inflammatory conditions, hairy cell leukemia, or other lymphoid neoplasm, metastatic malignancy or toxic (chronic) myelopathies.

Table 2. IWG-MRT recommended criteria for post-PV MF and post-ET MF

| <i>Criteria for post-polycythemia vera myelofibrosis</i> | |
|--|--|
| Required criteria: | |
| 1 | Documentation of a previous diagnosis of polycythemia vera as defined by the WHO criteria ¹ |
| 2 | Bone marrow fibrosis grade 2–3 (on 0–3 scale) ³ or grade 3–4 (on 0–4 scale) ^{4, a} |
| Additional criteria (two are required): | |
| 1 | Anemia ^b or sustained loss of requirement of either phlebotomy (in the absence of cytoreductive therapy) or cytoreductive treatment for erythrocytosis |
| 2 | A leukoerythroblastic peripheral blood picture |
| 3 | Increasing splenomegaly defined as either an increase in palpable splenomegaly of >5 cm (distance of the tip of the spleen from the left costal margin) or the appearance of a newly palpable splenomegaly |
| 4 | Development of >1 of three constitutional symptoms: >10% weight loss in 6 months, night sweats, unexplained fever (>37.5°C) |
| <i>Criteria for post-essential thrombocythemia myelofibrosis</i> | |
| 1 | Documentation of a previous diagnosis of essential thrombocythemia as defined by the WHO criteria ¹ |
| 2 | Bone marrow fibrosis grade 2–3 (on 0–3 scale) ³ or grade 3–4 (on 0–4 scale) ^{4, a} |
| Additional criteria (two are required): | |
| 1 | Anemia ^b and a >2mg ml ⁻¹ decrease from baseline haemoglobin level |
| 2 | A leukoerythroblastic peripheral blood picture |
| 3 | Increasing splenomegaly defined as either an increase in palpable splenomegaly of >5 cm (distance of the tip of the spleen from the left costal margin) or the appearance of a newly palpable splenomegaly |
| 4 | Increased LDH (above reference level) |
| 5 | Development of >1 of three constitutional symptoms: >10% weight loss in 6 months, nights sweat, unexplained fever (>37.5°C) |

Abbreviations: IWG-MRT: International Working Group for Myelofibrosis Research and Treatment; LDH: lactate dehydrogenase; post-ET MF: post-essential thrombocythemia myelofibrosis; post-PV MF: post-polycythemia vera myelofibrosis.

appears either as a diffuse hyperlucent lesions or less commonly as patches of sclerosis (20). In this review, we shed the light on the exceptional association between osteolytic bone lesions and primary myelofibrosis.

Risk stratification

Before the era of molecular and genetic studies, the outcome was poorly identified. Nowadays, with the utilization of the new cytologic technology, the door has been opened for advanced prognostic scoring systems which can stratify patient's risk from day one of

diagnosis. GIPSS (genetically inspired prognostic scoring system) is the most common risk estimation tool which categorizes patients into low, intermediate, and high risk, validated to predict overall survival and leukemia-free survival; the other predication tool and the more complicated one is MIPSS70+ v2.0 (mutation-enhanced international prognostic scoring system plus karyotype, 70+, version 2.0) which incorporates the clinical findings with the cytologic studies, it is advised as a two-step approach for better risk discrimination in patients with intermediate risk on GIPSS score (21,22).

Treatment usually depends on the risk stratification of each case. For high-risk patients: a bone marrow

transplant is a good option (23), whereas medications like JAK2 inhibitors (24) and hydroxyurea can be considered in low and moderate cases.

Methods

We performed a systematic review following the Preferred Reporting Items for Systematic Reviews and Meta-Analyses (PRISMA) guidelines. We searched the English literature (Google Scholar, PubMed, and SCOPUS) for studies, reviews, case series, and case reports about patient with myelofibrosis who develop lytic bone lesion. We used

the terms in combination: “Myelofibrosis” or “Primary myelofibrosis” OR “chronic idiopathic myelofibrosis” OR “agnogenic myeloid metaplasia” and “Osteolytic bone lesion”, “Osteolytic lesion”, “lytic bone lesion”. The review included patients with primary myelofibrosis confirmed by biopsy, and declining all cases with any possible secondary causes of myelofibrosis. The reference lists of the included studies were scanned for any additional articles. The search included all articles published up to 10th April 2021. Two independent reviewers screened the titles and abstracts of the records independently and papers unrelated to our inclusion criteria were excluded. A total of 10 articles were included in the review (Figure 1).

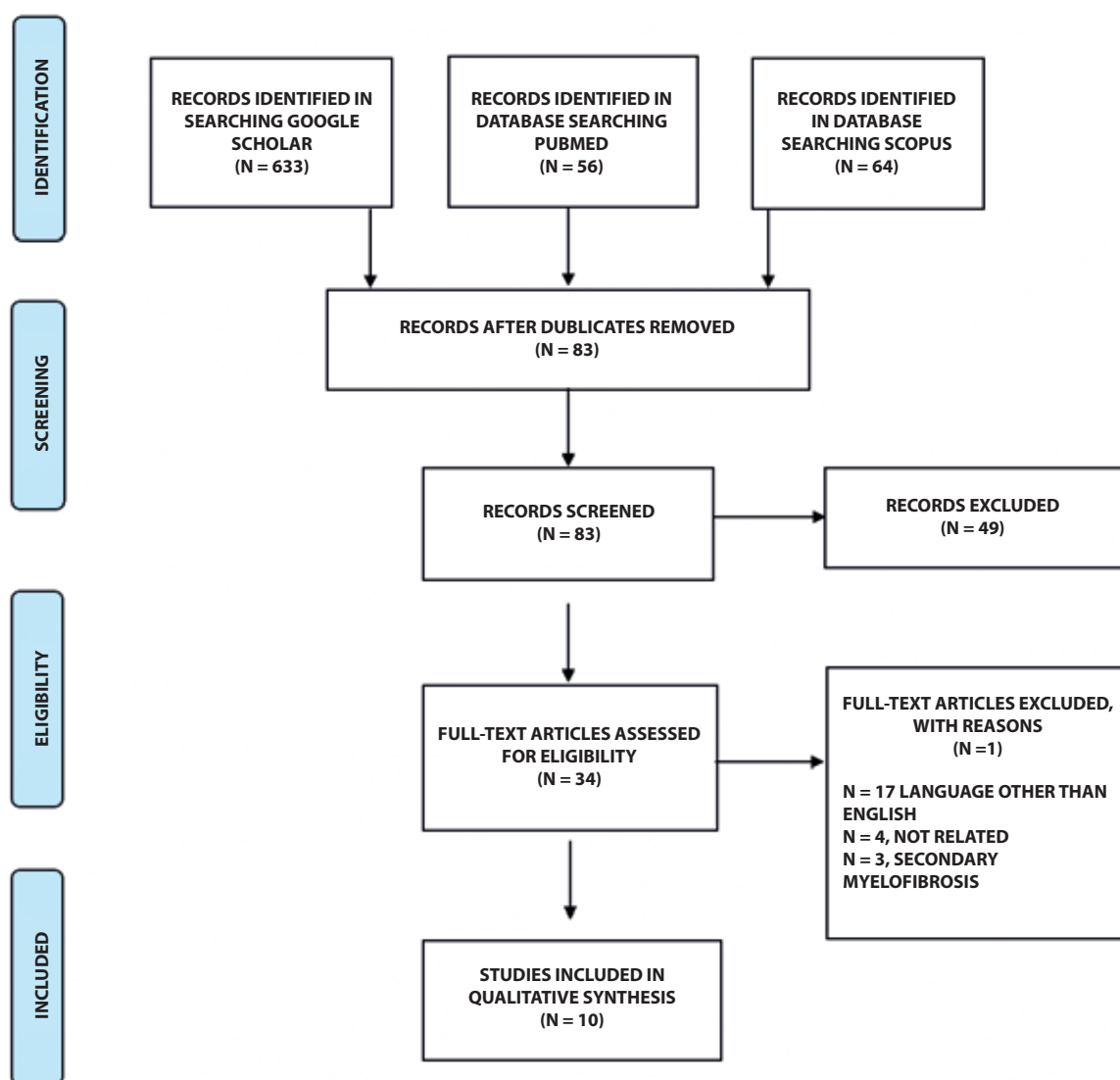


Figure 1. The PRISMA flow diagram detailing the patients with myelofibrosis who developed osteolytic bone lesion.

Results

Clinical information for each patient is summarized in (Table 3). A total number of 10 patients were included in the review. Six patients out of 10 were females, the male:female ratio almost equal to 1:1. The mean age at time of diagnosis was 56.3 year, only two cases were diagnosed at young age, however the majority have osteolytic bone lesion at age above 40 years (8/10) of cases.

The mean time between the diagnosis of primary myelofibrosis until the osteolytic bone lesion capturing was approximately 10.1 years. Seven out of 10 patients had painful bone lesion. Others were incidental findings during a scan for other reasons. All patients have significant splenomegaly. All patients had the lytic lesion detected on X-ray, and 2 patients had confirmed findings on magnetic resonance imaging (MRI). The most commonly affected

bones were the vertebrae, pelvis, ribs, humerus then the scapula, femur and skull and less frequently wrist bones and calcaneus. The shape, the extension and the numbers of lesion were variable, some showed cortical sparing and others come with cortical destruction. Two cases were positive for JAK2 mutation. Two patients had received ruxolitinib (one of them before bone marrow transplantation), two patients were treated with busulfan, one patient received radiotherapy, one patient had thalidomide and another one thioguanine with cytosine arabinoside. The rest of patients received non-specific treatments like erythropoietin analogues or supportive blood transfusion. Few cases responded well to treatment, only one patient survived one year after the detection of bone lesions. Our search also detected three patients with myelofibrosis secondary to polycythemia vera who also developed lytic lesions table 2 (patients no. 10-13).

Table 3. Clinical characteristics, treatment received and outcome of patients with myelofibrosis secondary to polycythemia vera.

| Author | Age of PMF diagnosis and gender Presenting symptoms | Age (years) when the lytic lesion detected Lesion of osteolytic lesions | Lesion bx and JAK2V617F mutation | Treatment | Treatment response and outcome |
|---|---|---|----------------------------------|---|--|
| 1. Burnham, et al. Cureus 2020; 12 (3):e7475. | 60 M Left lateral hip and thigh pain | 63 Proximal left femur then right hip and femur. Rt calcaneus | Myelofibrosis Positive | Bone Marrow transplant then ruxolitinib | Improved Died after 10 months from the first osteolytic lesion |
| 2. Bucelli et al. Chemotherapy 2018; 63:340-4. | 33 F Left upper limb pain | 59 Left humerus | Grade 3 fibrosis positive | Hydroxyurea then ruxolitinib 15 mg bid for 12 months | Full resolution Aive after 1 year |
| 3. Merry and Aronowitz. J Hosp Med 2010;5:E27-8. | 7g M Weakness>>fall>>hand fracture | 83 Left hand, wrist, and forearm | Not done N/A | Thalidomide and darbepoetin | N/A Died after 1 month |
| 4. Clutterbuck et al. J Clin Pathol 1995;48:867-8. | 26 M Pneumonia, flaccid paralysis of left foot | 5.9 Left femur | Hematopoietic cells N/A | N/A | N/A Died due to septicemia after 6 months |
| 5. Gruber et al. Med Oncol Tumor Pharmacother 1987;42: 107-9. | 64 F Back pain with HF sx | 64 Ribs and the pelvis. Skull and scapula, spinal column | Hematopoietic cells N/A | Thioguanine and cytosine arabinoside then busulfan for lytic lesion | Partial response Died after 6 years from first symptomatic lytic lesion |

Table 3 (Continued)

Table 3. Clinical characteristics, treatment received and outcome of patients with myelofibrosis secondary to polycythemia vera. (continued)

| Author | Age of PMF diagnosis and gender Presenting symptoms | Age (years) when the lytic lesion detected Lesion of osteolytic lesions | Lesion bx and JAK2V617F mutation | Treatment | Treatment response and outcome |
|--|---|---|---|---|---|
| 6. Case records of the Massachusetts General Hospital. Case 39-1974 Nengl J Med 1974;291:721-30. | 66 F Fatigue and anorexia | 70 Clavicles, left. Scapula and humerus then ribs | N/A N/A | Busulfan | Mild improvement Died within a year due to sepsis |
| 7. Rudders et al. Am J Clin Pathol 1974;61:673-9. | 72 F Right chest pain | 72 Right ribs, femur, pelvis and skull | Rib: Hematopoietic elements N/A | Transfusion with. No treatment | No response Died in the same year |
| 8. French et al. South Med J 1970;63:387-91. | 67 M Lower limbs swelling with left hip pain | 67 1, 2 vertebra and right 8 th rib | Rib: fibrous replacement of the marrow N/A | Radiotherapy with testosterone enanthate 600 mg IM q week | Worsening Died within 6 months |
| 9. Theodore et al. Radiology 1967;89:941-6. | 55 F Chest pain | 68 Ribs, clavicles, scapula and humerus | Hematopoietic stem cells front rib N/A | Transfusion with. No treatment | N/A Died in the same year |
| 10. Case records of the Massachusetts General Hospital. Case 65-1963 N ENgI J Med 1963;269:854-63. | 44 F Abdominal pain | 62 Calvarium, ribs spine all bones, except tibia and fibula | N/A N/A | Fluoxymestone and conjugated estrogen | No response Died in one year due to pneumonia |
| 11. Sideris et al. Ann Hematol 2006;85:555-6. | 71 M Lower back pain with LL weakness | 72 Ribs, sternum, vertebrae, pelvis, and calcaneus | Myeloid metaplasia N/A | N/A | N/A Died after 1 year |
| 12. Kosmidis et al. Cancer 1980;46:2263-5. | 69 F Acute pleuritic chest pain | 71 All bones (ribs and long bones) | Myelofibrosis N/A | N/A | N/A Died after 6 months |
| 13. Leimert et al. Am J Clin Pathol 1978;70:706-8. | 47 M Knee and ankle pain | 49 Distal femurs, proximal tibias and fibulas, pelvis, and lumbar spine | Hematopoietic cells with fibrosis N/A | Radiotherapy | No response Died within a year due to staphylococcal septicemia |

Legend: NSA: not available

Discussion

Since primary myelofibrosis has been reported, many theories describing the underlying mechanism have come to light; up to date, the pathophysiology

of myelofibrosis is still not clear (Figure 2). However, the new targeted sequencing methods improved our understanding of the somatic mutation's role in PMF phenotype. Likewise, the karyotypic studies did show the implication of chromosomal abnormalities in the

disease development and prognosis, as a result the auto-activated gene in muted megakaryocyte or lymphocyte brings on a wide spectrum of cytokines and growth factors production leads to irregular clonal cell proliferation and fibroblasts stimulation. This constitutive activation of fibroblasts fills the bone marrow with reticuline and collagen leading to ineffective hematopoiesis (25, 26).

The studies have showed that almost 60 % of PMF patients carry clonal karyotypic abnormalities, and the most common ones are deletion of a segment of the chromosomes (13q-) and (20q-) respectively (27, 28).

Although only 50 % of PMF patients have JAK2 mutation, activation of the JAK2-STAT pathway has a tremendous effect in cell proliferation and survival (29), the other mutations include the calreticulin gene (CALR) and the thrombopoietin receptor (MPL) are

reported in 35 % and 5 % respectively in JAK2V617F-negative MF patients (30–32).

All these factors eventually result in a fibrous bone marrow that incapable of providing the tissues with blood cells. Subsequently, other organs like the liver and spleen take over the steering wheel to keep an adequate production of blood cells to ensure proper body function. This phenomenon is called extramedullary hematopoiesis, which is a defense mechanism from the embryonic phase that the body develops to maintain the hemostasis. It can explain the extra-osseous manifestations of myelofibrosis like hepatosplenomegaly, lymphadenopathy, and others (33, 34).

The hyperdynamic ineffective bone marrow can have a negative impact on the bone structure resulting in different types of bone pathology including lytic and sclerotic lesions. Studies have shown that 30–70

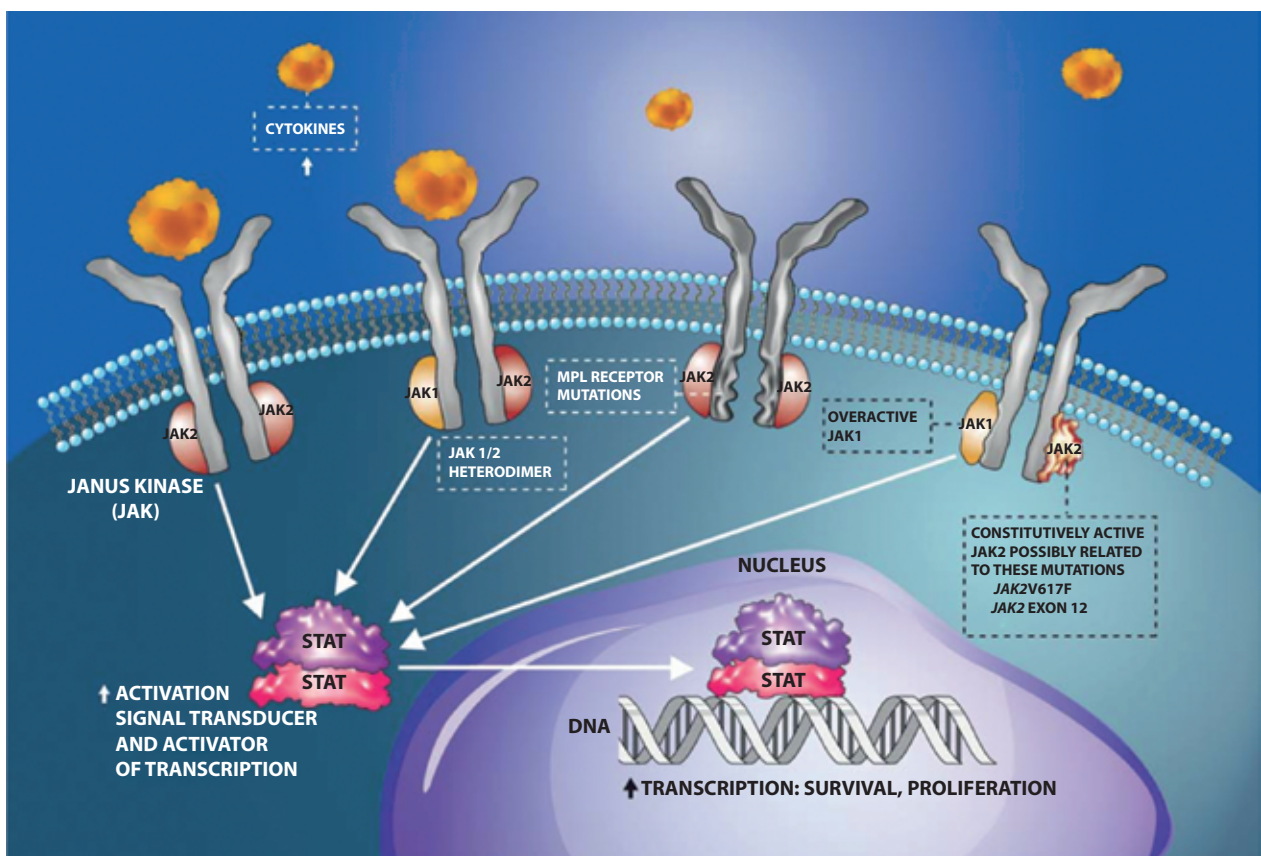


Figure 2. JAK-STAT pathway. Ligand binding to cytokine and growth factor receptors activates JAKs, which are receptor tyrosine kinases that subsequently phosphorylate STAT transcription factors. Activated STATs translocate to the nucleus to stimulate the transcription of genes involved in cell proliferation and survival. The JAK-STAT pathway is dysregulated in MF, making JAKs targets for therapeutic intervention. (Reproduced with permission from Incyte Corp. JAK: Janus-associated kinase; MPL: Myeloproliferative leukemia virus (oncogene); STAT: Signal transducer and activator of transcription).

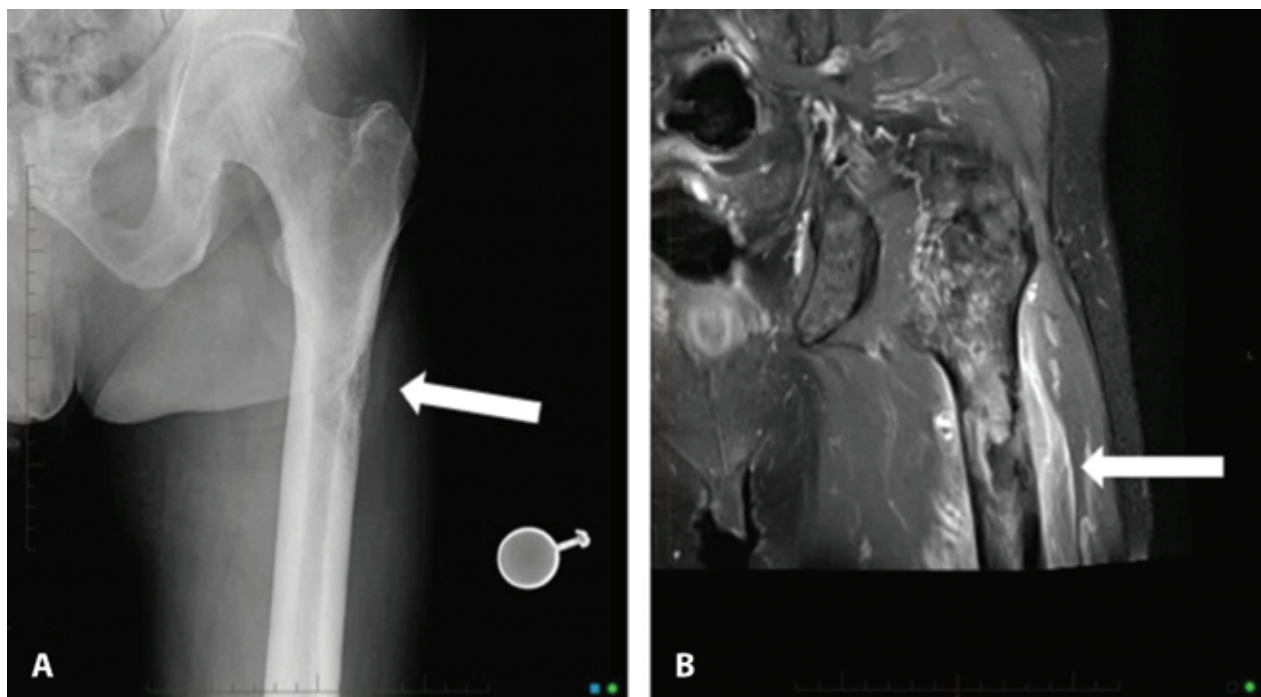


Figure 3. Left femur imaging. A plain radiograph of the left proximal femur identifies a sub-trochanteric permeative, lytic bone lesion with cortical destruction (A), which is also documented after T2-weighted fat-saturated MRI of the left proximal femur with notable intramedullary fibrosis, marked heterogeneity of the marrow, and associated soft tissue edema surrounding the proximal femur (B) (From ref. 47; Reproduced with permission of Editor).

% of bone changes are osteosclerotic lesions, those changes can be observed in the long bones due to endosteal sclerosis which obliterates the margin between the cortical and medullary bone (Figure 3). However, in the vertebral column a mixed picture of condense alternatively with hyperlucent areas have been encountered (35), while in the ribs it is more homogenous and gives a view like the 'jail bars', later on, in the advanced stages we can notice the complete destruction and obliteration of medullary space with preserved cortex out borders (36).

The exact mechanism beyond developing lytic lesion is not fully studied, the observation from the above mentioned cases and post mortem reports suggest the following etiologies.

First, Raia et al. (37) noticed in his case after autopsy multiple nodules arising from the bone and the soft tissue around, compressing the adjusting bone causing area of lucency, similarly in Kosmidis et al. (38) case where he noticed areas of necrosis due to the extensive fibrotic tissue expansion toward the cortex.

The second theory is the inflammatory theory in which lytic lesions manifest as a result of local bone destruction by tumor necrosis factor due to leukemic transformation of myelofibrosis (39).

In primary myelofibrosis there is slight male dominance, the searched literature showed that osteolytic lesions tend to happen in equal distribution between genders. Obviously, we need larger sample size to tell if there is difference between gender. Looking at patients' characteristics, the patients with lytic bone lesions have mean age of 56 years at the presentation. This means that patient who developed lytic bone lesions are slightly younger compared to the other patients diagnosed with MF as the usual age of presentation for patients with MF is usually average 67 years (40).

It is easy to notice that most of the patients were in advanced stages when the lytic lesions discovered, this observation can be explained by the time needed to generate extramedullary hematopoiesis and subsequent effect on bone structure revealing the lytic

lesions. PMF is associated with a median overall survival of around six years, and our patients had the lytic lesions detected after average 8.8 years. However, 7 patients had the osteolytic lesion detected within three years of PMF diagnosis and most patients who were young developed the osteolytic lesions after longer time compared to elder patients. This variation in age and the time to development of lytic lesion could be due to a long asymptomatic, indolent phase of the disease, in which patient can survive for decades without even knowing he or she is ill (41) or it can be due to age related factors. Because of the few number of reported patients, it is difficult to conclude if the lytic lesions are by themselves a sign of poor prognosis or they are a sign of advanced disease.

The majority of the lesions were painful and pain was the chief complaint that pushed people to seek medical advice. Since the bone is a highly innervated tissue and the nerve endings are distributed between the bone marrow trabeculae and the periosteum area, this fact can explain the pain even before detecting any bone destruction or periosteum inflammation (42). However, 3 patients came with asymptomatic lesions, this can be linked to the early presentation due to other complaints (fall, pneumonia and profound fatigue) (43,44). It is not surprising to perceive that the most affected bones are the same bones responsible for hematopoiesis. Since the initial response will be as a compensatory hyperfunctioning of the bone marrow, and once it fail the process will be continued in other organs.

The JAK/STAT pathway and its role in oncogenesis becomes well-established in the last decade (45). And more importantly after 2008 when the WHO guidelines highlighted the diagnostic value of JAK2 mutation in the diagnosis of PMF (46), this explains the reason why only 2 patients had JAK2 test as other cases were reported much earlier. In the same context, those two patients were treated with JAK inhibitor (Ruxolitinib) an FDA approved medication with proved efficacy in controlling (PMF) symptoms and improving overall survival. However, the case described by Burnham et al. (47) died within the first year of treatment due to renal failure related complications.

Our group is studying the unmet clinical needs in Myeloproliferative neoplasms and CML like cost effective analysis for second generations TKIs when used as

upfront (48), the association of tuberculosis with CML (49), the reactivation of hepatitis B with CML (50), ophthalmic manifestations as initial presentation in patients with CML (51), Effects of intermittent fasting on CML (52), autoimmune hemolytic anemia and its association with different therapies in CML (53), priapism (54,55) and male fertility (56), obesity (57) and obesity related surgeries in patients with CML (58) as well as effects of environmental factors in MPNs(59).

Conclusion

Osteolytic bone lesions in patients with primary myelofibrosis is extremely rare finding, and noticed shortly after diagnosis in elderly and after longer duration in young patients. The lytic lesion seems to have a bad prognostic value as we can notice 11 out of 13 patients have died within one year of detection.

Conflicts of interest: Each author declares that he or she has no commercial associations (e.g. consultancies, stock ownership, equity interest, patent/licensing arrangement etc.) that might pose a conflict of interest in connection with the submitted article.

References

1. Heuck G. Zwei Fälle von Leukämie mit eigenthümlichem Blut- resp. Knochenmarksbefund. Arch für Pathol Anat und Physiol und für Klin Med [Internet]. 1879;78:475–96. Available from: <https://doi.org/10.1007/BF01878089>.
2. Dameshek W. Some speculations on the myeloproliferative syndromes. Blood 1951;6:372-5.
3. Jackson Jr H, Parker Jr F, Lemon HM. Agnogenic myeloid metaplasia of the spleen: a syndrome simulating other more definite hematologic disorders. N Engl J Med 1940; 222:985-94.
4. Yassin MA, Taher A, Mathews V, Hou HA, Shamsi T, Tuğlular TF, Xiao Z, Kim SJ, Depei W, Li J, Rippin G. MERGE: a multinational, multicenter observational registry for myeloproliferative neoplasms in Asia, including Middle East, Turkey, and Algeria. Cancer medicine. 2020 Jul;9(13):4512-26.
5. Arber DA, Orazi A, Hasserjian R, et al. The 2016 revision to the World Health Organization classification of myeloid neoplasms and acute leukemia. Blood 2016;127:2391-405.
6. Tefferi A. Primary myelofibrosis: 2021 update on diagnosis, risk-stratification and management. Am J Hematol 2021;96:145-62.

7. Barbui T, Thiele J, Gisslinger H, Carobbio A, Vannucchi AM, Tefferi A. Diagnostic impact of the 2016 revised who criteria for polycythemia vera. *Am J Hematol* 2017;92:417-9.
8. Mesa RA, Silverstein MN, Jacobsen SJ, Wollan PC, Tefferi A. Population-based incidence and survival figures in essential thrombocythemia and agnogenic myeloid metaplasia: an Olmsted County Study, 1976-1995. *Am J Hematol* 1999;61:10-5.
9. Barbui T, Thiele J, Gisslinger H, et al. The 2016 WHO classification and diagnostic criteria for myeloproliferative neoplasms: document summary and in-depth discussion. *Blood Cancer J* 2018;8(2):15.
10. Barosi G, Mesa RA, Thiele J, et al. International Working Group for Myelofibrosis Research and Treatment (IWG-MRT). Proposed criteria for the diagnosis of post-polycythemia vera and post-essential thrombocythemia myelofibrosis: a consensus statement from the International Working Group for Myelofibrosis Research and Treatment. *Leukemia* 2008;22:437-8.
11. Smith RE, Chelmsowski MK, Szabo EJ. Myelofibrosis: a review of clinical and pathologic features and treatment. *Crit Rev Oncol Hematol* 1990;10:305-14.
12. Tefferi A. Myelofibrosis with myeloid metaplasia. *N Engl J Med* 2000;342:1255-65.
13. O'Reilly RA. Splenomegaly in 2,505 patients in a large university medical center from 1913 to 1995. 1913 to 1962: 2,056 patients. *West J Med* 1998;169:78-87.
14. Wanless IR, Peterson P, Das A, Boitnott JK, Moore GW, Bernier V. Hepatic vascular disease and portal hypertension in polycythemia vera and agnogenic myeloid metaplasia: a clinicopathological study of 145 patients examined at autopsy. *Hepatology* 1990;12:1166-74.
15. Lundh B, Brandt L, Cronqvist S, Eyrich R. Intracranial myeloid metaplasia in myelofibrosis. *Scand J Haematol* 1982;28:91-4.
16. Koch BL, Bisset GS 3rd, Bisset RR, Zimmer MB. Intracranial extramedullary hematopoiesis: MR findings with pathological correlation. *AJR Am J Roentgenol* 1994;162:1419-20.
17. Bartlett RP, Greipp PR, Tefferi A, Cupps RE, Mullan BP, Trastek VF. Extramedullary hematopoiesis manifesting as a symptomatic pleural effusion. *Mayo Clin Proc* 1995;70:1161-4.
18. Knobel B, Melamed E, Virag I, Meytes D. Ectopic medullary hematopoiesis as a cause of ascites in agnogenic myeloid metaplasia. Case report and review of the literature. *Acta Haematol* 1993;89:104-7.
19. Loewy G, Mathew A, Distenfeld A. Skin manifestation of agnogenic myeloid metaplasia. *Am J Hematol* 1994;45:167-70.
20. Oon SF, Singh D, Tan TH, et al. Primary myelofibrosis: spectrum of imaging features and disease-related complications. *Insights Imaging*. 2019;10: 1-4.
21. Tefferi A, Guglielmelli P, Nicolosi M, et al. GIPSS: genetically inspired prognostic scoring system for primary myelofibrosis. *Leukemia* 2018;32:1631-42.
22. Tefferi A, Guglielmelli P, Lasho TL, et al. MIPSS70+ Version 2.0: Mutation and Karyotype-Enhanced International Prognostic Scoring System for Primary Myelofibrosis. *J Clin Oncol* 2018; 36:1769-70.
23. Ballen KK, Shrestha S, Sobocinski KA, et al. Outcome of transplantation for myelofibrosis. *Biol Blood Marrow Transplant* 2010;16:358-67.
24. Gangat N, Tefferi A. Myelofibrosis biology and contemporary management. *Br J Haematol* 2020;191:152-70.
25. Reeder TL, Bailey RJ, Dewald GW, Tefferi A. Both B and T lymphocytes may be clonally involved in myelofibrosis with myeloid metaplasia. *Blood* 2003;101:1981-3.
26. Tefferi A, Vaidya R, Caramazza D, Finke C, Lasho T, Pardanani A. Circulating interleukin (IL)-8, IL-2R, IL-12, and IL-15 levels are independently prognostic in primary myelofibrosis: a comprehensive cytokine profiling study. *J Clin Oncol* 2011;29:1356-63.
27. Reilly JT, Snowden JA, Spearing RL, et al. Cytogenetic abnormalities and their prognostic significance in idiopathic myelofibrosis: a study of 106 cases. *Br J Haematol* 1997;98:96-102.
28. Tefferi A, Mesa RA, Schroeder G, Hanson CA, Li CY, Dewald GW. Cytogenetic findings and their clinical relevance in myelofibrosis with myeloid metaplasia. *Br J Haematol* 2001;113:763-71.
29. Pikman Y, Lee BH, Mercher T, et al. MPLW515L is a novel somatic activating mutation in myelofibrosis with myeloid metaplasia. *PLoS Med* 2006; 3(7):e270.
30. Nangalia J, Massie CE, Baxter EJ, et al. Somatic CALR mutations in myeloproliferative neoplasms with nonmutated JAK2. *N Engl J Med* 2013;369:2391-2405.
31. Klampfl T, Gisslinger H, Harutyunyan AS, et al. Somatic mutations of calreticulin in myeloproliferative neoplasms. *N Engl J Med* 2013;369:2379-90.
32. Pardanani AD, Levine RL, Lasho T, et al. MPL515 mutations in myeloproliferative and other myeloid disorders: a study of 1182 patients. *Blood* 2006;108:3472-6.
33. Yamamoto K, Miwa Y, Abe-Suzuki S, et al. Extramedullary hematopoiesis: Elucidating the function of the hematopoietic stem cell niche (Review). *Mol Med Rep* 2016;13:587-91.
34. Koch CA, Li CY, Mesa RA, Tefferi A. Nonhepatosplenic extramedullary hematopoiesis: associated diseases, pathology, clinical course, and treatment. *Mayo Clin Proc* 2003;78:1223-33.
35. Guerzani A, de Kerviler E, Cazals-Hatem D, Zagdanski AM, Frija J. Imaging findings in patients with myelofibrosis. *Eur Radiol* 1999;9:1366-75.
36. Pettigrew JD, Ward HP. Correlation of radiologic, histologic, and clinical findings in agnogenic myeloid metaplasia. *Radiology* 1969;93:541-8.
37. Raia TJ Jr, Hentz EC, Theros EG. An exercise in radiologic-pathologic correlation. *Radiology* 1967;89:941-6.
38. Kosmidis PA, Palacas CG, Axelrod AR. Diffuse purely osteolytic lesions in myelofibrosis. *Cancer* 1980;46:2263-5.

39. Jurisic V, Terzic T, Pavlovic S, Colovic N, Colovic M. Elevated TNF-alpha and LDH without parathormone disturbance is associated with diffuse osteolytic lesions in leukemic transformation of myelofibrosis. *Pathol Res Pract* 2008;204:129-32.
40. Varki A, Lottenberg R, Griffith R, Reinhard E. The syndrome of idiopathic myelofibrosis. A clinicopathologic review with emphasis on the prognostic variables predicting survival. *Medicine (Baltimore)* 1983;62:353-71.
41. Visani G, Finelli C, Castelli U, et al. Myelofibrosis with myeloid metaplasia: clinical and haematological parameters predicting survival in a series of 133 patients. *Br J Haematol* 1990;75:4-9.
42. Maryanovich M, Takeishi S, Frenette PS. Neural Regulation of Bone and Bone Marrow. *Cold Spring Harb Perspect Med* 2018;8(9):a031344.
43. Clutterbuck DJ, Morrison AE, Ludlam CA. Osteolytic bone lesions in a patient with idiopathic myelofibrosis and bronchial carcinoma. *J Clin Pathol* 1995;48:867-8.
44. Kaufman SD, Putsch WGJ. Case 39-1974. *N Engl J Med* 2010;291:721-30.
45. Levy DE, Darnell JE Jr. Stats: transcriptional control and biological impact. *Nat Rev Mol Cell Biol* 2002;3:651-62.
46. Thiele J, Kvasnicka HM. The 2008 WHO diagnostic criteria for polycythemia vera, essential thrombocythemia, and primary myelofibrosis. *Curr Hematol Malig Rep* 2009;4:33-40.
47. Burnham RR Jr, Johnson B, Lomasney LM, Borys D, Cooper AR. Multi-focal Lytic Lesions in a Patient with Myelofibrosis: A Case Report. *Cureus* 2020;12(3):e7475.
48. Adel A, Abushanab D, Hamad A, Abdulla M, Izham M, Yassin M. Assessment of Dasatinib Versus Nilotinib as Upfront Therapy for Chronic Phase of Chronic Myeloid Leukemia in Qatar: A Cost-Effectiveness Analysis. *Cancer Control* 2021;28:10732748211001796.
49. Iqbal P, Soliman A, De Sanctis V, Yassin MA. Association of tuberculosis in patients with chronic myeloid leukemia: a treatment proposal based on literature review. *Expert Rev Hematol* 2021;14:211-7.
50. Atteya A, Ahmad A, Daghstani D, Mushtaq K, Yassin MA. Evaluation of Hepatitis B Reactivation Among Patients With Chronic Myeloid Leukemia Treated With Tyrosine Kinase Inhibitors. *Cancer Control* 2020;27(1):1073274820976594.
51. Yassin MA, Ata F, Mohamed SF, et al. Ophthalmologic manifestations as the initial presentation of chronic myeloid leukemia: A Review. *Surv Ophthalmol* 2021; S0039-6257(21)00144-2.
52. Yassin MA, Ghasoub RS, Aldapt MB, et al. Effects of Intermittent Fasting on Response to Tyrosine Kinase Inhibitors (TKIs) in Patients With Chronic Myeloid Leukemia: An Outcome of European LeukemiaNet Project. *Cancer Control* 2021;28:10732748211009256.
53. Hamamyh T, Yassin MA. Autoimmune hemolytic anemia in chronic myeloid leukemia. *Pharmacology* 2020;105:630-8.
54. Ali E, Soliman A, De Sanctis V, Nussbaumer D, Yassin M. Priapism in Patients with Chronic Myeloid Leukemia (CML): A Systematic Review. *Acta Biomed* 2021;92(3):e2021193.
55. Ali EA, Nashwan AJ, Yassin MA. Essential thrombocythemia with (type2) calreticulin presented as stuttering priapism case report and review of literature. *Clinical Case Reports* 2021; 9:399-404.
56. Yassin MA, Soliman AT, De Sanctis V. Effects of tyrosine kinase inhibitors on spermatogenesis and pituitary gonadal axis in males with chronic myeloid leukemia. *J Cancer Res Ther* 2014;2:116-21.
57. Abdulla MA, Chandra P, Akiki SE, Aldapt MB, Sardar S, Chapra A, Nashwan AJ, Sorio C, Tomasello L, Boni C, Yassin MA. Clinicopathological Variables and Outcome in Chronic Myeloid Leukemia Associated With BCR-ABL1 Transcript Type and Body Weight: An Outcome of European LeukemiaNet Project. *Cancer Control*. 2021 Aug 1;28:10732748211038429.
58. Yassin MA, Kassem N, Ghassoub R. How I treat obesity and obesity related surgery in patients with chronic myeloid leukemia: An outcome of an ELN project. *Clin Case Rep* 2021; 9:1228-34.
59. Allahverdi N, Yassin M, Ibrahim M. Environmental Factors, Lifestyle Risk Factors, and Host Characteristics Associated With Philadelphia Negative Myeloproliferative Neoplasm: A Systematic Review. *Cancer Control*. 2021 Jan-Dec;28:10732748211046802. doi: 10.1177/10732748211046802. PMID: 34645293; PMCID: PMC8521755.

Correspondence:

Received: 10 September 2021

Accepted: 1 October 2021

Dr. Mohamed A Yassin

Senior Consultant Hematologist

National Center for Cancer Care and Research

Hamad Medical Corporation

Doha (Qatar)

Associate Professor of Medicine

College of Medicine Qatar University

E-mail: yassinmoha@gmail.com