

## C A S E R E P O R T

# An unusual approach for a cervical mass: sternotomy for the treatment of a giant cervico-thoracic lipoma

Gerardo Petruzzi<sup>1</sup>, Lucrezia Trozzi<sup>2</sup>, Silvia Moretto<sup>1</sup>, Armando De Virgilio<sup>3,4</sup>, Enrico Melis<sup>5</sup>, Filippo Tommaso Gallina<sup>5</sup>, Barbara Pichi<sup>1</sup>, Flaminia Campo<sup>1</sup>, Francesco Facciolo<sup>5</sup>, Raul Pellini<sup>1</sup>

<sup>1</sup>Department of Otolaryngology and Head and Neck Surgery, IRCCS Regina Elena National Cancer Institute, Rome, Italy; <sup>2</sup>Unità Operativa Complessa di Otorinolaringoiatria, Fondazione Policlinico Universitario A. Gemelli, IRCCS, Rome, Italy; <sup>3</sup>Humanitas University, Pieve Emanuele (MI), Italy; <sup>4</sup>Department of Otorhinolaryngology Head and Neck Surgery, IRCCS Humanitas Clinical and Research Center, Rozzano (MI), Italy; <sup>5</sup>Thoracic Surgery Unit, Experimental Clinical Oncology Department, IRCCS Regina Elena National Cancer Institute, Rome, Italy

**Abstract.** *Background and aim:* Lipoma is a benign mesenchymal tumor. It is a very common tumor and in 13% of cases occurs in head and neck. Giant lipomas are extraordinary and cervical involvement with mediastinal extension is an exceedingly rare presentation. Only a few cases of thoracic extension are reported in literature. *Methods:* We describe the case of a 62-years-old man with a giant cervico-mediastinic lipoma which required a combined approach through cervicotomy and sternotomy to ensure surgical radicality. Differential diagnoses could be thymolipoma, liposarcoma or familiar lipomatosis. *Results:* The mass was removed en-bloc with thymus and locoregional lymph nodes. The patient recovered uneventfully. *Conclusions:* The aim of this report is to discuss potential pitfalls of differential diagnosis and implementation of the therapeutic treatment. Focus on the relevance of performing fluorescence in situ hybridization (FISH) for MDM2 amplification is reported, a necessary technique for the differential diagnosis. ([www.actabiomedica.it](http://www.actabiomedica.it))

**Key words:** Sternotomy, Lipoma, Combined approach, Liposarcoma, Mediastinum.

## Introduction

Lipomas are benign neoplasms originating from mesenchymal tissues, characterized by a slow growing pattern and uncommon presence of symptoms. Lipomas mostly occur in the 5th-6th decade of life, almost thirteen percent of the cases are localized in the head and neck, usually in the posterior region of the neck (1-3). Anterior neck is rarely involved, and thoracic extension is even rarer (4-8). According to our knowledge, only a few cases of lipomas of the anterior region of the neck and mediastinal involvement are described (6-13). In differential diagnosis, several lipomatous diseases can be evaluated, as systemic lipomatosis

(14,15) and thymolipoma (16,17). In contrast to thymomas, thymolipomas are benign tumors. The most important neoplasm to exclude in the differential diagnosis is liposarcoma. The malignant evolution of lipomas into liposarcomas is rare but described in the literature (11,12,18).

Treatment options for lipomatous masses could range from observation to minimally invasive procedures, up to invasive surgery. Thoracoscopic approach to manage caudal extension of cervical lipomas has proven to be effective and less burdensome than open surgery (1,3,17).

If mediastinal lipomas become symptomatic, debulking could be enough to manage the pathology, but

if there is strong suspicion of malignancy, en bloc surgical resection is recommended. The aim is to reach complete excision of the lesion, in order to prevent recurrence and local invasion (10). Here we report a case of a sixty-two years old man with right anterior neck lipoma with massive thoracic extension, who required open combined surgery due to involvement of major blood vessels, in order to ensure a safe and complete excision of the mass.

### Case report

A 62-years old man presented in July 2020 with a progressively growing right cervical mass, complaining about pain during neck extension and mild dysphagia. Dyspnea, vascular or nervous compressive symptoms were not reported. He is a life-long non-smoker and has a past medical history of occasional arrhythmia and dyslipidemia.

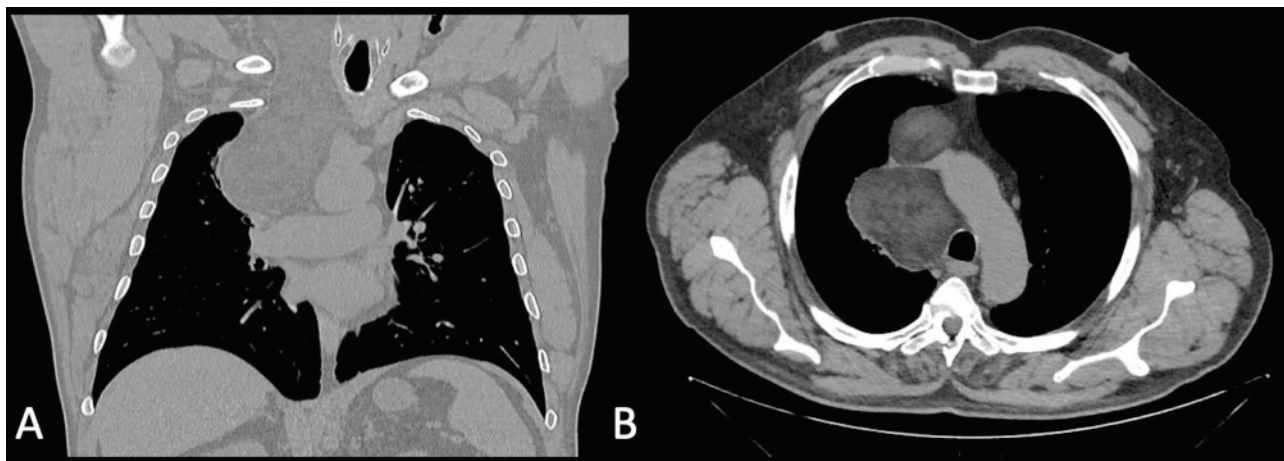
### Investigations

Ultra-sonogram was firstly performed, identifying a huge mass, whose caudal extension was not fully assessable. Therefore, CT scan of the chest and torso was performed and revealed a giant mass (18 x 8,3 x 7 cm) with fat density in the right cervical region, posteriorly to sternocleidomastoid muscle, deviating right

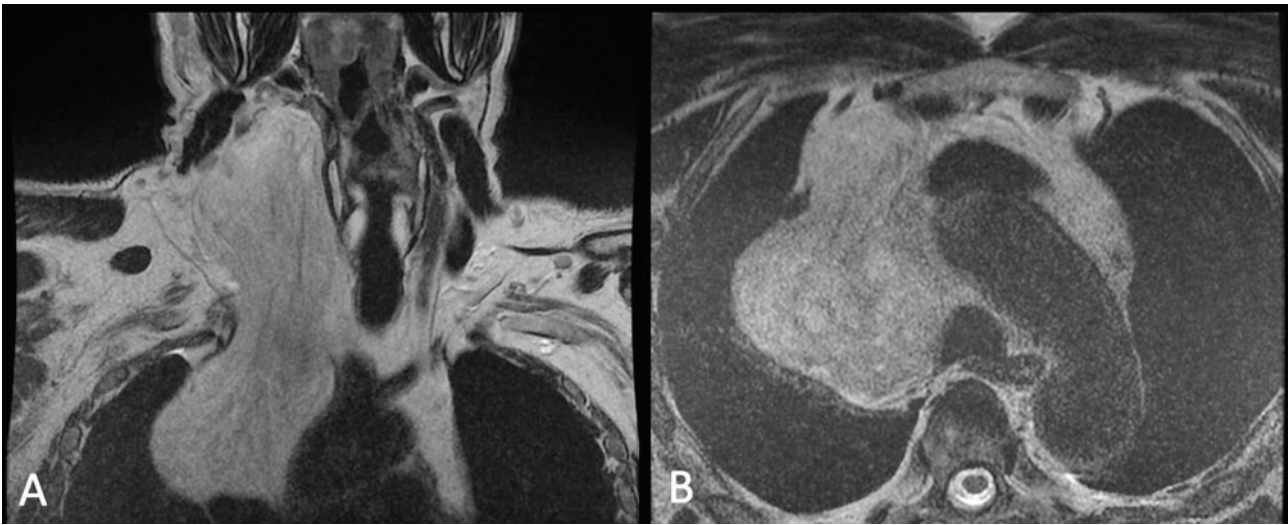
upper pharynx and trachea to the left and displacing the interior jugular vein anteriorly and laterally and the common carotid artery posteriorly and medially. The right thyroid lobe was compressed. Posteriorly, the mass was in contact with the lateral esophageal wall, without compression. The right innominate and subclavian arteries were dislocated posteriorly and the subclavian vein anteriorly (Fig. 1).

MRI was performed to reveal the mass's relationship with soft tissue and vascular structures. Imaging detected a large, hyper intense formation in the T1 and T2 weighted sequences. There were no signs of infiltration of the surrounding tissues. The dislocation of the right jugular vein and carotid artery, right thyroid lobe, trachea, larynx and hyoid bone were confirmed. At the mediastinal level, in addition to the contralateral dislocation of the trachea, stenosis of azygos vein, superior vena cava and of both brachiocephalic trunks was documented. No suspected adenopathy was reported. The findings of the MRI suggested as a first hypothesis a lipoma/lipoma-like formation (Fig. 2).

The patient underwent a combined evaluation by head-neck and thoracic surgeons and addressed to open surgical approach, due to the inferior extension of the mass, the involvement of the superior vena cava with compression phenomena, and to exclude de-differentiation in liposarcoma.



**Figure 1.** TC performed preoperatively. The mass shows a lower density than muscles. a) coronal; b) axial.



**Figure 2.** MRI performed preoperatively. The mass appears hyper intense at T1 time of acquisition. Relationship with major vessels at mediastinal level is shown. a) coronal; b) axial.

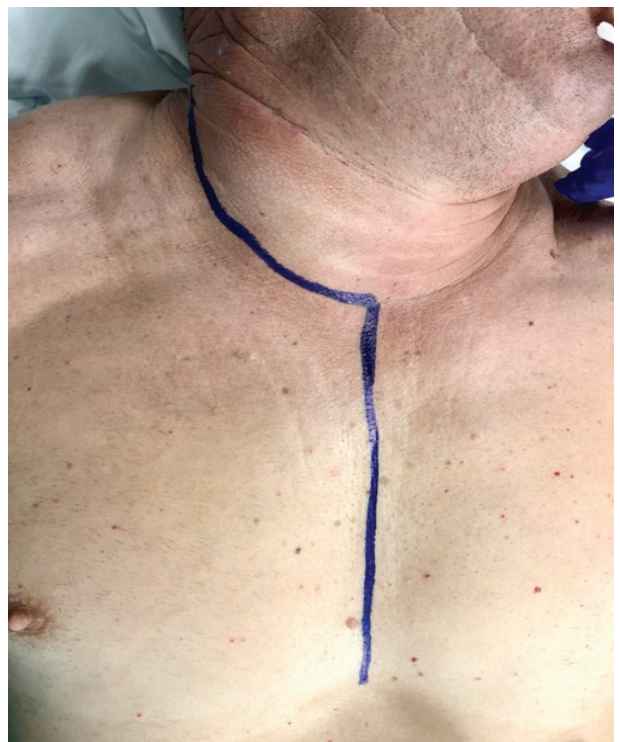### Treatment

The patient was operated under general anesthesia. Cervical incision and sternotomy were performed to allow an extensive exposure of the lesion at the thoracic level (Fig. 3).

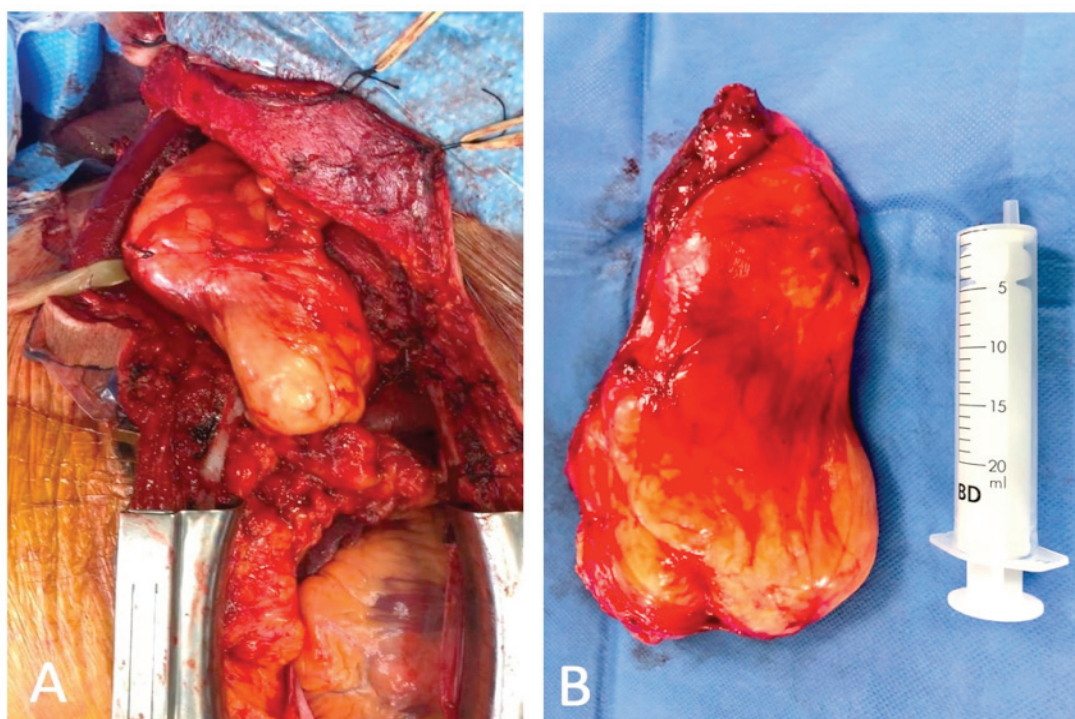
The surgeons performed a dissection of the right neck from level IIA to the mediastinum, preserving the eleventh cranial nerve, the recurrent laryngeal nerve and major vessels. Both pleural spaces are widely opened to perform a complete exploration and evaluation of the extent of the tumor as well as individuation of the phrenic nerves to prevent their damage. The pericardium was opened in order to safeguarding the superior vena cava. Therefore, the lesion was removed en-bloc with the thymus (Fig. 4).

A huge fatty mass measuring 15 x 11 x 7 cm and weighing 1260 gr was removed, together with the thymus and 22 lymph nodes. No areas of necrosis, hemorrhage or degeneration were macroscopically found. Histopathological examination demonstrated spindle cells in a loose stromal tissue and wide adipose areas. Thymus and all the lymph nodes appeared free from disease. Staining for *murine double minute 2* (MDM2) do not showed a strong nuclear reactivity for this marker. Conclusive diagnosis was spindle cell lipoma. Patient recovered uneventfully.

The three-month clinical follow-up at the end of surgery was negative for local or systemic complications.



**Figure 3.** Surgical incision planning, major vessels at mediastinal level is shown. a) coronal; b) axial.



**Figure 4.** Surgical specimen. a) Lesion in situ; b) Lesion excised.

## Discussion

Lipomas are slow growing fatty masses, generally asymptomatic until causing compression or reaching huge dimensions. Lipomas that reach width greater than 10 cm and weigh more than 1000 gr are defined “giant” (3,7,18). The present case can be classified as a giant cervico-mediastinal lipoma.

Regarding differential diagnosis, particular attention to liposarcoma should be paid. It has a fast pattern of growth and the most frequent sites are the soft tissues, the mediastinum, the retroperitoneum, the buttock. Atypical cells, scattered lipoblasts, and infiltrative growth pattern differentiate liposarcomas from lipomas (19). However, even on histological examination it is difficult to distinguish between a lipoma and a well-differentiated liposarcoma (WDLPS). WDLPS shows risk of local recurrence but no potential for metastasis, so radical excision is mandatory but follow up can be focused on the primary site of occurrence (19). Additional molecular analyses as identification of *murine double minute 2* (MDM2) oncogene amplification

are crucial for differential diagnosis (19,20). This cytotype is characterized by amplifications in the chromosomal region 12q13-15; these amplifications constantly affect MDM2, that is consequently reliable for differential diagnosis (19-21). In case of absence of MDM2 staining positivity, diagnosis of WDLPS can be excluded.

From a brief review of English literature, we found a few cases of cervico-mediastinal lipomatous masses (4-6,8,16,22,23). Three of the cases described were children. One case was affected by cervico-thoracic lipoma, treated without the need of thoracotomy, and two of them presented a cervico-mediastinal thymolipoma: an eleven years old boy underwent to median sternotomy, the 4 yo girl was treated by thoracoscopic approach only. Median age of the other cases reported was  $51,6 \pm 21$  years old. Two of the patients underwent to combined cervicotomy and median sternotomy, one was treated by cervicotomy alone and one needed cervicotomy and thoracoscopic debulking of the mass. Rieker et. al reported nine cases of thymolipomas:

treatment of choice for seven of them was median sternotomy and thoracotomy in two cases (17).

Giant lipoma, although rare, is a neoplasm that can occur in the head and neck area. The treatment, for curative purposes, may sometimes require invasive approaches with a high risk of surgical complications. The cervical mediastinal extension presented in this case is one of the rare conditions that required this combined approach (16,24,25).

## Conclusion

We describe a rare case of a giant lipoma treated with an unusual combined cervico-thoracic approach. Median sternotomy, even if represents an invasive and burdensome procedure, is the gold standard to approach large mediastinal masses. In this case we opted for an invasive surgical technique, in order to best manage vascular and nervous structures. Radical excision was mandatory for the presence of compression phenomena of superior cava. Our choice was driven also by differential diagnosis as mediastinum is a typical site of occurrence of liposarcoma. The removal of the entire mass allowed both to control the disease at local level and provide a complete histological specimen for a careful and accurate analysis of possible signs of malignancy.

**Author's contribution:** Gerardo Petruzzi, Lucrezia Trozzi, Flaminia Campo, Armando de Virgilio conceived and designed the study. Enrico Melis, Raul Pellini, Barbara Pichi, Gerardo Petruzzi and Francesco Facciolo planned and performed the surgical treatment, supervised the project, analyzed the data and encourage to investigate the specific aspect of the work. Filippo Tommaso Gallina, Lucrezia Trozzi and Silvia Moretto wrote the manuscript. All the authors contributed to the final version of the manuscript. All authors read and approved the final version of the manuscript.

**Conflict of Interest:** Each author declares that he or she has no commercial associations (e.g. consultancies, stock ownership, equity interest, patent/licensing arrangement etc.) that might pose a conflict of interest in connection with the submitted article

## References

1. El-Monem MH, Gaafar AH, Magdy EA. Lipomas of the head and neck: presentation variability and diagnostic work-up. *J Laryngol Otol.* 2006;120(1):47-55.
2. Som PM, Scherl MP, Rao VM, Biller HF. Rare presentations of ordinary lipomas of the head and neck: a review. *AJNR Am J Neuroradiol.* 1986;7(4):657-664.
3. Medina CR, Schneider S, Mitra A, Spears J, Mitra A. Giant submental lipoma: Case report and review of the literature. *Can J Plast Surg.* 2007;15(4):219-222.
4. Sharma BK, Khanna SK, Bharati M, Gupta A. Anterior neck lipoma with anterior mediastinal extension - a rare case report. *Kathmandu Univ Med J (KUMJ).* 2013;11(41):88-90.
5. Eryılmaz MA, Yücel A, Yücel H, Arıcıgil M. Cervico-Thoracic Giant Lipoma in a Child. *Turk Arch Otorhinolaryngol.* 2016;54(2):82-85.
6. Venkatramani H, Ramani V, Sabapathy SR. Giant cervico-thoracic lipoma as a manifestation of human immunodeficiency virus-associated lipodystrophy. *Plast Reconstr Surg.* 2010;126(6):316e-318e.
7. Cutilli T, Schietroma M, Marcelli VA, Ascani G, Corbacelli A. Giant cervico-mediastinal lipoma. A clinical case. *Minerva Stomatol.* 1999;48(1-2):23-28.
8. Ganesh Y, Yadala V, Nalini Y, Dal A, Raju AD. Huge mediastinal mass with minimal symptoms: thymolipoma. *BMJ Case Rep.* 2011;2011:bcr0520102984.
9. Choi HJ, Kim SH. Symptomatic Giant Lipoma Under the Latissimus Muscle. *J Craniofac Surg.* 2016;27(7):e599-e600.
10. Pellini R, Ruggieri M, Pichi B, Covello R, Danesi G, Spriano G. A case of cervical metastases from temporal bone carcinoid. *Head Neck.* 2005;27(7):644-647.
11. Petruzzi G, Zocchi J, Moretto S, et al. Transoral robotic retropharyngeal lymph node dissection in a recurrent head and neck carcinoma. *Head Neck.* 2019;41(11):4051-4053.
12. Dei Tos AP. Liposarcoma: new entities and evolving concepts. *Ann Diagn Pathol.* 2000;4(4):252-266.
13. Mazzola F, Tomasoni M, Mocellin D, et al. A multicenter validation of the revised version of the Milan system for reporting salivary gland cytology (MSRSGC). *Oral Oncol.* 2020;109:104867.
14. Tadisina KK, Mlynek KS, Hwang LK, Riazi H, Papay FA, Zins JE. Syndromic lipomatosis of the head and neck: a review of the literature. *Aesthetic Plast Surg.* 2015;39(3):440-448.
15. Singh K, Sen P, Musgrove BT, Thakker N. Facial infiltrating lipomatosis: A case report and review of literature. *Int J Surg Case Rep.* 2011;2(7):201-205.
16. Tan TW, Kim DS, Wallach MT, Mangray S, Luks FI. Thoracoscopic resection of a giant thymolipoma in a 4-year-old girl. *J Laparoendosc Adv Surg Tech A.* 2008;18(6):903-905.
17. Rieker RJ, Schirmacher P, Schnabel PA, et al. Thymolipoma. A report of nine cases, with emphasis on its association with myasthenia gravis. *Surg Today.* 2010;40(2):132-136.

18. Woo SJ, Hong KY, Chang H. Giant Ventral Lipoma of the Neck. *J Craniofac Surg.* 2020;31(5):e501-e503.
19. Kammerer-Jacquet SF, Thierry S, Cabillic F, et al. Differential diagnosis of atypical lipomatous tumor/well-differentiated liposarcoma and dedifferentiated liposarcoma: utility of p16 in combination with MDM2 and CDK4 immunohistochemistry. *Hum Pathol.* 2017;59:34-40.
20. Zhang H, Erickson-Johnson M, Wang X, et al. Molecular testing for lipomatous tumors: critical analysis and test recommendations based on the analysis of 405 extremity-based tumors. *Am J Surg Pathol.* 2010;34(9):1304-1311.
21. Clay MR, Martinez AP, Weiss SW, Edgar MA. MDM2 Amplification in Problematic Lipomatous Tumors: Analysis of FISH Testing Criteria. *Am J Surg Pathol.* 2015;39(10):1433-1439.
22. Patel RV, Evans K, Sau I, Huddart S. Paediatric giant cervicomediastinal thymolipoma. *BMJ Case Rep.* 2014;2014:bcr2014203585.
23. Gupta A, Palkar A, Narwal P, Kataria A. Mediastinal lipoma as a cause of dyspnea. *Respir Med Case Rep.* 2019;27:100828. Published 2019 Mar 25.
24. Julian OC, Lopez-Belio M, Dye WS, Javid H, Grove WJ. The median sternal incision in intracardiac surgery with extracorporeal circulation; a general evaluation of its use in heart surgery. *Surgery.* 1957;42(4):753-761.
25. Salam GA. Lipoma excision. *Am Fam Physician.* 2002;65(5):901-904.

---

**Correspondence:**

Received: 30 September 2021

Accepted: 3 October 2021

Gerardo Petruzzi, MD

Department of Otolaryngology and Head and Neck Surgery,

IRCCS Regina Elena National Cancer Institute, Via Elio

Chianesi 53, 00144, Rome, Italy.

Telephone Number: +390652665065

Fax: +390652662015

E-mail: petruzzigerardo@gmail.com