

Kounis syndrome: from an unexpected case in the Emergency Room to a review of the literature.

Erika Poggiali¹, Irene Benedetti¹, Valeria Vertemati¹, Luca Rossi², Alberto Monello², Manuela Giovini³, Andrea Magnacavallo¹, Andrea Vercelli¹

¹ Emergency Department, “Guglielmo da Saliceto” Hospital, Piacenza, Italy; ² Division of Cardiology, Department of Cardiovascular and Emergency, “Guglielmo da Saliceto” Hospital, Piacenza, Italy; ³ Intermediate Care Unit, Emergency Department, “Guglielmo da Saliceto” Hospital, Piacenza, Italy. * the authors equally contributed to this work.

Abstract. Kounis syndrome (KS) is a coronary syndrome in the setting of allergic/anaphylactic reactions and can be classified in three variants: vasospastic allergic angina (type I), allergic myocardial infarction (type II) and stent thrombosis (type III). The early diagnosis is of paramount importance for the correct management and the prognosis, being KS a life-threatening emergency condition. KS is not uncommon, but it is frequently unrecognized or undiagnosed in virtue of its broad clinical manifestations. The diagnosis should be based on the combination of cardiovascular and allergic/anaphylactic clinical symptoms and signs, as well as on laboratory, electrocardiographic, echocardiographic, and angiographic evidence. ECG monitoring, cardiac enzymes and troponin are mandatory to confirm or exclude KS in a patient with subclinical or clinical, acute, or chronic allergic reactions. Nevertheless, the treatment is a real challenge for the emergency clinicians because guidelines have not been established yet, and the therapy is based on the variant type. We herein report the case of type I KS in a woman with no prior history of allergy, admitted to our emergency department for abdominal pain, nausea and hematochezia. Starting from this case we conducted a systematic search of the following databases: PubMed, Google Scholar, Science Direct, Medline, using the keywords of “Kounis syndrome”, “coronary spasms”, “cardiac arrest”, “sudden death”, “allergy”, and “anaphylaxis”. The main purpose of this review is to remind emergency clinicians to keep a high index of suspicion regarding KS when dealing with patients with allergic reactions or anaphylaxis to promptly identify and correctly manage KS. (www.actabiomedica.it)

Keywords: Kounis syndrome, cardiac arrest, allergy, anaphylaxis, coronary disease.

Case report

An 80-year-old woman presented to our Emergency Department (ED) complaining of hematochezia, nausea, and acute increasing diffuse abdominal pain. She had a history of hypertension, overweight and colon diverticulosis diagnosed by colonoscopy few years before. On admission she was afebrile with dry skin and mucous membranes, and a blood pressure, heart and respiratory rate of 170/100 mmHg, 90 bpm and 20 breaths/min, respectively. Heart auscultation findings were normal. Her abdomen was mild distended with

marked rebound tenderness on palpation of the left quadrant and suprapubic region and absent peristalsis. On chest exam bibasilar fine crackles were found. The digital rectal exploration revealed bright red blood without hemorrhoids. Electrocardiogram (ECG) showed sinus rhythm, AV block I degree, and incomplete right bundle branch block (RBBB) (figure 1). Point-of-care ultrasonography documented bilateral B lines in the middle and basal fields, gastrectasis and dilated bowel loops with absent peristalsis. Shortly after physical examination, the patient presented a sudden episode of vomiting with nausea and severe abdominal

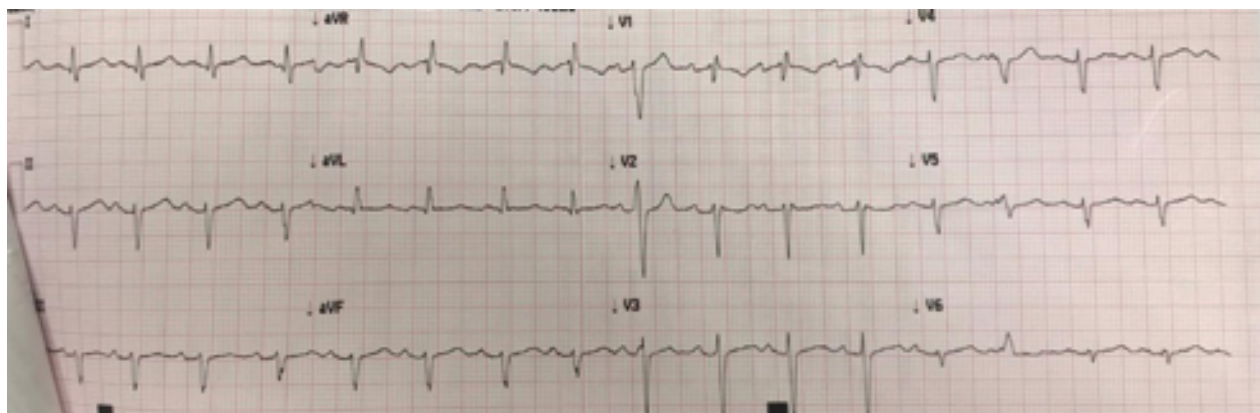


Figure 1. ECG at admission showed sinus rhythm, AV block 1 degree and incomplete RRBB.

pain, with partial relief after placement of the nasogastric tube and intravenous acetaminophen. Venous blood gas analysis showed increased hemoglobin and hematocrit levels (respectively, 14 g/dL and 43%), and mild hyperlactatemia (15 mg/dL, normal value 5-15). On laboratory tests, white blood cells ($19.58 \times 10^3/\mu\text{L}$), neutrophils ratio (87.4 %), lactate dehydrogenase (423 U/L, normal value 0-248), C-reactive protein (19.84 mg/dL, normal value 0-0.05) and procalcitonin (1.6 ng/mL, normal value <0.5) were significantly increased. Platelet count, kidney and liver function, lipase and coagulation tests were all within normal limits. A RT-PCR nasopharyngeal swab for SARS-CoV-2 resulted negative. After hydration with crystalloids, hemoglobin and hematocrit levels decreased to 11 g/dL and 33.5%, respectively. Urgent abdominal CT scan with contrast confirmed the clinical suspicion of acute diverticulitis, documenting widespread signs of pancolic diverticulosis with edematous imbibition of the pericolic cell tissue in the hepatic and splenic flexure and fluid layers along the lateral bands. Since she has no history of allergy, an empiric broad-spectrum intravenous antibiotic therapy with piperacillin/tazobactam was initiated in the emergency room, but after a few minutes, the patient started coughing with an abrupt sense of smothering or gasping, followed by a subsequent pulseless electrical activity (PEA) cardiac arrest. She regained spontaneous circulation (ROSC) after 3 cycles of cardiopulmonary resuscitation (CPR) without the administration of adrenaline. Post-ROSC ECG showed ST segment elevation of

more 2 mm in DII, DIII and aVF leads (figure 2), and subsequently complete AV block. Based on this findings, anti-ischemic therapy with lysine acetylsalicylate was started. During CPR, the patient developed a diffuse maculopapular erythema and rash on her neck. In the hypothesis of anaphylactic shock, treatment was started with parenteral corticosteroids and intravenous volume replacement, antihistamine, and ephedrine. In addition, intravenous amiodarone was administered for the onset of atrial fibrillation. The patient was intubated and immediately transferred to the coronary care unit (CCU). In the CCU, the ischemic ECG changes were absent and ECG monitoring confirmed the well-known AV block grade I and incomplete RBBB, suggesting an acute heart damage as vasospastic angina. The echocardiographic study showed an overall normal systolic function without segmental motility abnormalities or valvular disease. An urgent coronary angiography was performed showing the absence of thrombotic occlusions and the evidence of a unique critical (95%) stenosis of the mid-segment of the right coronary artery, and TIMI (Thrombolysis in Myocardial Infarction) grade 3 flow. Based on the recent diverticular bleeding and the absence of thrombosis or unstable plate, angioplasty was not performed. A diagnosis of vasospastic angina during an anaphylactic reaction was done. Blood tests performed 12 hours after the cardiac arrest documented elevated troponin I (290 ng/mL, normal value < 31) and tryptase levels (13.8 $\mu\text{g/L}$, normal value < 11). Creatine phosphokinase and creatine kinase-MB were normal. IgE were not tested.

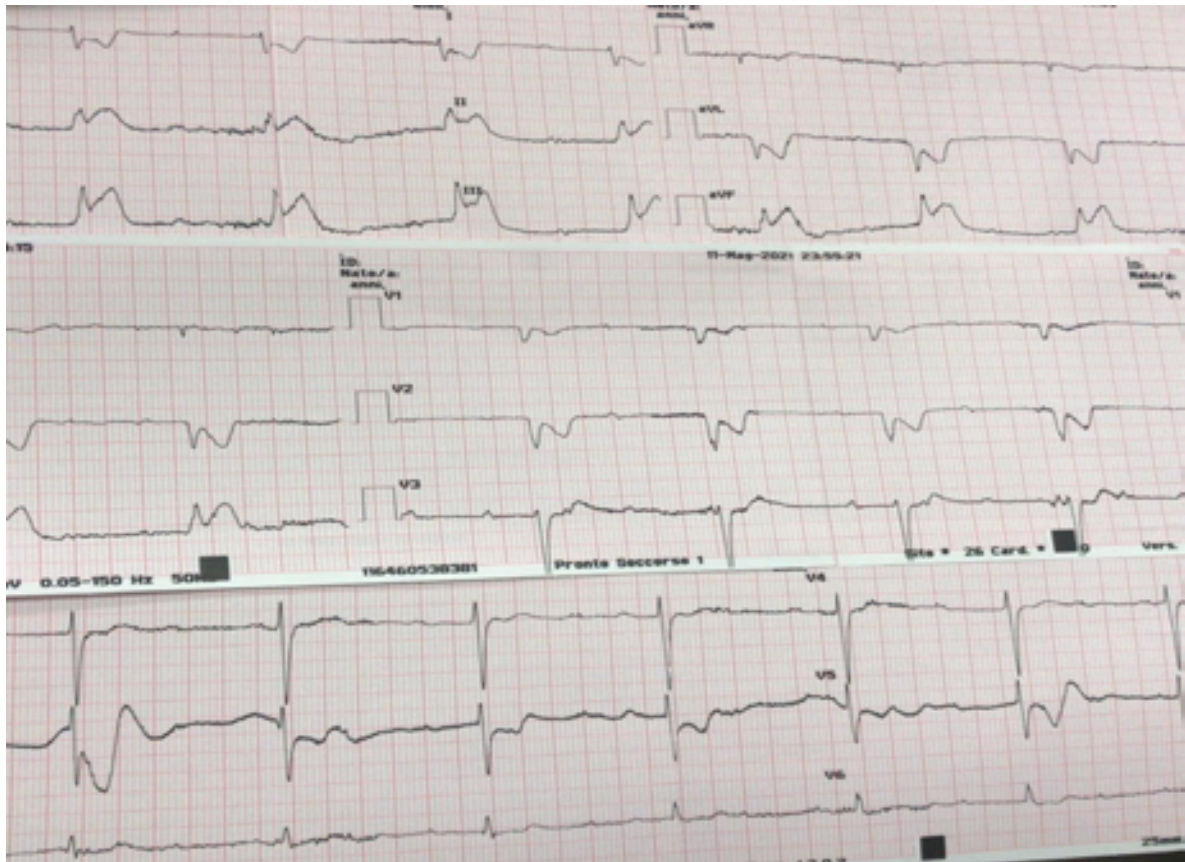


Figure 2. Post-ROSC ECG showed ST segment elevation of more 2 mm in DII, DIII and aVF leads (posterior STEMI).

The patient showed prompt response to the therapy, with a complete resolution of the allergic reaction in a few hours. The signs of ischemia and ECG changes disappeared along with the signs of allergic reaction, confirming the diagnosis of type I Kounis syndrome (KS). The patient was extubated after 24 hours, and she is still hospitalized in good clinical conditions in subintensive care unit.

Discussion

KS is a life-threatening emergency defined as acute coronary syndrome (ACS), including coronary spasm, acute myocardial infarction, and). KS can be induced stent thrombosis, in the setting of allergic, hypersensitivity, anaphylactic or anaphylactoid reactions (1,2) by several triggers, especially drugs used widely in daily clinical practice, such as non-steroidal

anti-inflammatory drugs (NSAIDs) and analgesics (3), antibiotics (4-6), anti-neoplastics (7), proton-pump inhibitors (8,9), contrast media (10-12), corticosteroids (13-15), anti-hypertensive medications (16), and others (17-19), but also environmental exposure (20), insect stings (21-27), foods (28-33), and stents (34-37). As reported in literature, drugs represent the most common cause of KS. In a meta-analysis by Raschi *et al.* (38) in 142 articles, drugs were considered responsible for KS; in 89 cases KS was triggered by non-pharmacological agents, and in 21 reports KS was stent related.

KS must be considered not a rare but a ubiquitous disease, that can affect any race, sex, and age (39), even children (40-42) and adolescents (43-47). A retrospective study by Helbling *et al.* (48) estimated an incidence of 7.9-9.6 per 100,000 inhabitants per year, but the diagnosis is certainly underestimated due to missed, unrecognized and/or undiagnosed cases.

The International Pharmacovigilance Agency (VigiBase™) have reported 51 cases of KS in the period 2010–2014, most of them due to NSAIDs and occurred in the USA (49). In the last two decades, the cases of KS have been encountered worldwide, mainly for the increased awareness of physicians of the existence of KS (50).

The diagnosis of KS is not easy in the ED by reason of its broad spectrum of clinical manifestation, and it should be based on the combination of cardiovascular and allergic or anaphylactic clinical symptoms and signs, as well as on laboratory, electrocardiographic, echocardiographic, and angiographic evidence.

The background. The first case of KS has been reported in 1950 in a 49-year-old man, who developed an acute myocardial infarction associated with urticaria under treatment with penicillin in oil (51). Other cases have been afterward described as “allergic cardiac reactions” or “serum acute carditis” due to serum sickness and tetanus antitoxin (52–54). In 1991, Kounis and Zavras firstly described the pathophysiology of the disease as an “histamine-induced angina syndrome” due to endothelial dysfunction or microvascular angina (55). In some cases, the allergic reaction can promote plaque rupture by the action of some mediators released from the inflammatory cells, particularly mast-cells (56), or can induce vasospastic angina (57). As reported by Lippi *et al.* (58), the troponin I levels resulted higher in patients admitted to the ED with a diagnosis of anaphylaxis, angioedema, urticaria and urticaria-angioedema, compared to healthy controls, suggesting the coronary arteries as primary targets of severe allergic reactions. In another study by Cha *et al.* (59), between 300 anaphylaxis cases occurred in the ED, myocardial injury, including KS and Takotsubo cardiomyopathy, was present in 7.3% of patients.

The pathogenesis. KS can be classified as an ACS related to mast cell-associated disorders and inflammatory cell interactions. Inflammatory mediators released during the allergic insult, e.g., histamine, platelet-activating factor, arachidonic acid products, neutral proteases, cytokines, and chemokines (60), can activate inflammatory cells, including mast cells (61–62), macrophages, and T-lymphocytes (63–64). The activation–degranulation of mast cells via several mechanisms (63,65–66) is the primary mechanisms

in the pathogenesis of KS, with the production and release of inflammatory mediators in the heart tissue and in the systemic circulation. The mediators released include histamine, platelet activating factor, cytokines, and neutral proteases as well as tryptase, chymase and cathepsin D, which can induce coronary vasoconstriction directly as histamine (67), or via angiotensin II as chymase and cathepsin D (68) or can promote platelet activation and plaque disruption or rupture (69), and the activation of the coagulation cascade (70). All these inflammatory mediators can cause coronary artery spasm, which can progress to acute myocardial damage, or immediate coronary or stent thrombosis (71), which are the three main clinical manifestations of KS (72). Furthermore, KS must be considered not a single-organ arterial disorder, but a complex multisystem disease, which can involve the skin, respiratory, and vascular systems (73). Mast cells can in fact penetrate all human tissues, as consequence KS can affect all the entire arterial system as well as the cerebral (74) and mesenteric arteries (75). The brain does not suffer from allergic reactions, because IgE antibodies cannot cross the blood–brain barrier, but during anaphylactic reactions, the mast cells resident within the cerebral vasculature can release their vasoactive mediators, inducing cerebral artery spasm and promoting blood–brain barrier damage, brain oedema, prolonged extravasation and even haemorrhage (76). Indeed, platelet-activating factor can reduce cerebral blood flow leading to post-ischemic hypoperfusion (77). As consequence, cerebral ischemic lesions are the result of low cerebral blood pressure or direct proinflammatory and/or vasoconstrictive mediator action in the cerebral arterial system (77), causing a severe and irreversible condition that leads to a fatal hypoxic-ischemic encephalopathy in KS (78,79).

The clinical symptoms. Patients with KS can be admitted to the ED suffering from cardiac symptoms, such as typical ischemic chest pain, chest discomfort, dyspnea, and syncope due to coronary vasospasm, angina pectoris, myocardial infarction, or acute cardiac failure, associated with subclinical or clinical, acute, or chronic allergic reactions, including skin itching and rash, or pruritus. Acute allergic skin manifestations, e.g., urticaria, rash, erythema, and angioedema, can be helpful in the diagnosis, even if some patients can

present delayed skin reactions due to vasoconstriction induced by reduced cardiac output and hypotension during rapidly progressive anaphylaxis. On the other hand, KS can be caused by chronic urticaria itself (80). Emergency clinicians should always remember that the lack of skin manifestations is not an exclusion criterion of KS, but on the contrary a sign of severe shock (81): the cardiac collapse dramatically may indeed reduce the venous return and delay the released anaphylactic mediators to reach and exert their action in skin areas (82). Some patients can also complain of headache, general malaise, nausea, vomiting, and faintness. Diaphoresis, cold extremities, pallor, palpitations, hypotension, tachycardia, or bradycardia are common clinical signs of KS. If untreated, KS can cause cardiorespiratory arrest or sudden death. Cardiac dysfunction is independent from the reaction severity and according to the current classification, KS can be divided in three variants: vasospastic angina (type I), acute coronary thrombosis (type II) and stent thrombosis (type III) (50,83). Patients with type I variant have normal coronary arteries, and the acute allergic reaction induces coronary artery spasm as manifestation of endothelial dysfunction or microvascular angina. In type II variant patients have a pre-existing atheromatous disease, and the acute allergic reactions can induce plaque erosion or rupture and an acute myocardial infarction. Type III variant has been introduced in 2010 for patients with hypersensitivity reaction following implantation of drug-eluting stents and stent thrombosis with thrombi infiltrated by mast cells and eosinophils (83,84).

As brain can be involved in anaphylaxis, patients with KS can suffer from headache, tiredness, somnolence or altered neurological status, that can be misinterpreted as “normal” after an allergic reaction when they are symptoms of anaphylaxis because of reduced brain perfusion (85). Magnetic resonance imaging (MRI) can show hyperintensity on T2-weighted imaging and hypointensity on T1-weighted imaging, corresponding to swelling of the brain due to anaphylactic shock (86).

The diagnosis. The suspicion of KS should be always postulated for patients with systemic allergic reactions associated with clinical, electrocardiographic, echocardiographic, or angiographic, and laboratory

findings of acute myocardial ischemia. A careful history of previous atopy and allergic reactions is of paramount importance in the diagnostic process. Serum tryptase (87), IgE antibodies, cardiac enzymes, e.g., CK and CK—MB, and troponin should be tested in all cases to confirm or exclude the diagnosis of KS. As suggested by Kounis NG (88), tryptase should be measured half an hour after the initial symptoms and every 30 minutes thereafter during the following 2 hours. Emergency physicians should focus their attention on the possible cardiac damage resulting in troponin raising and anaphylactic cardiac shock (58,59). For this reason, troponin measurement should be always performed in all the patients admitted to the ED for acute allergic or anaphylactic reactions, to detect and treat immediately potential myocardial injury. ST-elevation or depression, or any degree of heart block and cardiac arrhythmias can be present on electrocardiogram (ECG) (89), even if in type I patients, cardiac enzymes and coronary angiography can be normal, and ECG changes transient (90). As consequence, ECG-monitoring is crucial to early and promptly identify KS. ECG monitoring is diagnostic when a correlation between allergic/anaphylactic reaction and an electrocardiographic abnormality is detected. In type I variant coronary angiography shows normal coronary arteries, while cardiac SPECT (91) and cardiac MRI (92) are useful to reveal severe myocardial ischemia and sub-endothelial damage, or in cases of diagnostic uncertainty, such as KS and myocarditis (92).

The treatment. KS is a life-threatening medical emergency that requires a rapid treatment (93). The management of these patients is a real challenge for the emergency clinicians since no guidelines have been established yet (94). Type I patients should be treated with intravenous corticosteroids such as hydrocortisone at a dose of 5 mg/kg/day. Vasodilators such as calcium channel blockers and nitrates can abolish the vasospasm. Intravenous or sublingual nitroglycerin can be administered with caution if the blood pressure is satisfactory (1). Type II patients must be treated for the acute coronary events together with corticosteroids. Nitrates and calcium channel blockers can be given if necessary. On the contrary, epinephrine, the drug of choice for anaphylaxis, can worsen ischemia and coronary vasospasm, as also beta-blockers. Sulphite-free

epinephrine is preferable to be given intramuscularly at doses 0.2-0.5 mg (1:1000), but it can result ineffective in patients already on beta-blockers. In this case, glucagon can be infused with the following dosing schedule: 1-5 mg, intravenously over 5 min, followed by infusion 5-15 µg/min (95). Morphine should be avoided, since it can induce massive mast cell activation and degranulation and aggravate the allergic reaction (96). Fentanyl can be a good alternative, while paracetamol (acetaminophen) is not recommended, because it can cause severe hypotension due to reduction of cardiac output (97). Type III patients need an urgent aspiration of intrastent thrombus, and its histological examination with staining for eosinophils and mast cells. Liu *et al.* (98) reported a case of a 48-year-old man with KS type III who presented persistent elevated levels of immunoglobulin E and chronic urticaria after appropriate antithrombotic, antihistamine, and reperfusion strategies. Upon administration of omalizumab (Xolair®), the authors observed an improvement of chronic urticaria, a decrease in immunoglobulin E levels, and resolution of the ischemic attacks.

Conclusion

KS is not a rare disease, rather it is a rarely diagnosed disease with a high mortality for cardiac arrest or sudden death. The underdiagnosis is related to its broad spectrum of clinical manifestations, and its etiology with continuously increasing of new causes, including drugs, contrast media, foods, insect stings, and stents. Emergency physicians should always consider KS when dealing with any kind or degree of allergic reaction, in order to make a proper and timely diagnosis of KS, take immediate decisions, and administer an effective therapy, as misdiagnosis of this disease can be fatal. ECG monitoring and troponin are crucial to promptly diagnose and define KS, particularly in type I variant.

Contributions: EP, IB and AV collected details of the case. EP and IB drafted the manuscript. IB, VV, LR, AM and MG cared for the patient. LR, AM e AV critically revised the manuscript. All authors approved the final version and stated the integrity of the whole work.

Conflicts of interest: This work was not supported by any grant.

Availability of data and materials: All data underlying the findings are fully available.

Ethics approval and consent to participate: As this was a descriptive case report and data was collected without patient identifiers, ethics approval was not required under our hospital's Institutional Review Board guidelines.

Acknowledgements: The authors thank Francesco Mariani for his valuable help in the difficult management of this case, and Prof Gianfranco Cervellin for his precious advice and constructive criticism.

References

1. Kounis NG. Kounis syndrome: an update on epidemiology, pathogenesis, diagnosis and therapeutic management. *Clin Chem Lab Med* 2016;54:1545-59.
2. Nikolaidis LA, Kounis NG, Grandman AH - Allergic angina and allergic myocardial infarction: a new twist on an old syndrome. *Can J Cardiol* 2002;18:508-11.
3. Hangouche AJE, Lamliki O, Oukerraj L, et al. Kounis syndrome induced by oral intake of aspirin: case report and literature review. *Pan Afr Med J* 2018;30:301.
4. Viana-Tejedor A, Espinosa MÁ, Cuesta J, Núñez A, Bueno H, Fernández-Avilés F. Kounis syndrome secondary to amoxicillin use in an asthmatic patient. *Int J Cardiol* 2011;150(3):e113-5.
5. Leibe C, Getachew B, Ehmann MR. Vancomycin-induced Kounis Syndrome. *Am J Emerg Med* 2019;37:1806.
6. Kounis NG, Koniari I. Ampicillin/sulbactam-induced Kounis syndrome with cardiogenic shock. *Anatol J Cardiol* 2017;17:154-155.
7. Tambe V, Tambe A, Goodman A, Shepherd Z. Carboplatin-Induced Kounis Syndrome. *Am J Ther* 2020;27(6):e647-e652.
8. Vlahos NP, Vavilis GK, Giannelou AG, Georgopoulou CN, et al. Hypersensitivity to proton pump inhibitors: lansoprazole-induced Kounis syndrome. *Int J Cardiol* 2009;134(3):e94-6.
9. Canpolat U, ahiner L, Aytemir K, Oto A. Allergic reaction to proton pump inhibitor: pantoprazole induced Kounis syndrome. *Int J Cardiol* 2012;159(2):e27-8.
10. Kounis NG, Koniari I, Tsigkas G, et al. Gadolinium-induced Kounis syndrome including electrocardiographic considerations. *Proc (Bayl Univ Med Cent)*. 2020;33:474-476.
11. van Ginkel AG, Sorgdrager BJ, de Graaf MA, Karalis I, Ajmone Marsan N. ST-segment elevation associated with

- allergic reaction to echocardiographic contrast agent administration. *Neth Heart J* 2013; 15:725-726.
12. Kounis NG, Koniari I, Tsigkas G, Davlouros P. Rectosigmoid ischemia and cerebral coma following gadolinium-induced anaphylaxis: A new manifestation of Kounis syndrome presented as devastating complication. *Ann Ital Chir* 2020;91:442-444.
 13. Kounis NG, Koniari I, Soufras GD, Chourdakis E. Anaphylactic shock with methylprednisolone, Kounis syndrome and hypersensitivity to corticosteroids: a clinical paradox. *Ital J Pediatr* 2018;44(1):143.
 14. Porcaro F, Paglietti MG, Diamanti A, et al. Authors' reply - anaphylactic shock with methylprednisolone, Kounis syndrome and Hypersensitivity to corticosteroids: a clinical paradox. *Ital J Pediatr* 2019;45(1):5.
 15. Okumura W, Nakajima M, Tateno R, Fukuda N, Kurabayashi M. Three cases of vasospastic angina that developed following the initiation of corticosteroid therapy. *Intern Med* 2014;53: 221-225.
 16. Josefsson J, Fröbert O. Losartan-induced coronary artery spasm. *BMJ Case Rep*: pii: bcr2012006252, 2012.
 17. Herrera-Lasso V, Dordal MT, Alonso G, Camprubí I, Lleonart R. Kounis Syndrome Due to Urapidil. *J Investig Allergol Clin Immunol* 2020 Sep 28:0.
 18. Palacios-Zabalza I, Camino-Rodríguez E, Aguirre C. Kounis syndrome induced by ranitidine. *Med Clin (Barc)*. 2018 Nov 9;151(9):e51-e53.
 19. Rodrigues MC, Coelho D, Granja C. Drugs that may provoke Kounis syndrome. *Braz J Anesthesiol* 2013;63:426-8.
 20. Kounis NG, Giannopoulos S, Soufras GD, Kounis GN, Goudevenos J. Foods, Drugs and Environmental Factors: Novel Kounis Syndrome Offenders. *Intern Med* 2015;54:1577-82.
 21. Puttegowda B, Chikkabasavaiah N, Basavappa R, Khateeb ST. Acute myocardial infarction following honeybee sting. *BMJ Case Rep* 2014;2014:bcr2014203832.
 22. Karadeniz M, Akyel A, Celik IE, Cankurt T, Bari VÖ, Murat SN. An unusual etiology of Kounis syndrome; warble fly. *Indian Heart J* 2013;65:358-9.
 23. Cross B, Choudhury TR, Hindle M, Galasko G. Wasp sting induced STEMI with complete coronary artery occlusion: a case of Kounis syndrome. *BMJ Case Rep* 2017;bcr2017221256.
 24. Ioannidis TI, Mazarakis A, Notaras SP, et al. Hymenoptera sting-induced Kounis syndrome: effects of aspirin and beta-blocker administration. *Int J Cardiol*;121:105-8.
 25. Ng BH, Tan HX, Vijayasingham S. Kounis syndrome following solenopsis (fire ant) bite. *Med J Malaysia* 2019;74:344-346.
 26. Katsanou K, Tsiafoutis I, Kounis NG. Timeo apis mellifera and dona ferens: bee sting-induced Kounis syndrome. *Clin Chem Lab Med* 2018;56:e197-e200.
 27. Ralapanawa DM, Kularatne SA. A case of Kounis syndrome after a hornet sting and literature review. *BMC Res Notes* 2014;7:867.
 28. Dogan V, Çelik O, Özlek B, et al. Allergic myocardial infarction: Type I Kounis syndrome following blue crab consumption. *Acta Clin Belg* 2019;74:375-377.
 29. Vaina S, Chrysohoou C, Bonfanti L, et al. Anaphylactic cardiovascular collapse manifesting as myocardial infarction following salad consumption. A case of Kounis variant type I syndrome. *Acta Biomed* 2020;91:134-138.
 30. Tzanis G, Bonou M, Mikos N, et al. Early stent thrombosis secondary to food allergic reaction: Kounis syndrome following rice pudding ingestion. *World J Cardiol* 2017;9:283-288.
 31. Ridolo E, Martignago I, Senna G, Ricci G. Scombroid syndrome: it seems to be fish allergy but... it isn't. *Curr Opin Allergy Clin Immunol* 2016;16:516-21.
 32. Mejía-Rentería HD, Viana-Tejedor A, Sánchez-Enrique C, et al. Kounis syndrome after ingestion of undercooked fish: new role of intracoronary imaging techniques. *Int J Cardiol* 2014;177:e58-60.
 33. Guler Y, Kalkan S, Esen AM. An extremely rare trigger of Kounis syndrome: *Actinidia chinensis*. *Int J Cardiol* 2014;172:e324-5.
 34. Chen JP, Hou D, Pendyala L, Goudevenos JA, Kounis NG. Drug-eluting stent thrombosis: the Kounis hypersensitivity-associated acute coronary syndrome revisited. *JACC Cardiovasc Interv* 2009;2:583-93.
 35. Kounis NG, Koniari I, Roumeliotis A, et al. Thrombotic responses to coronary stents, bioresorbable scaffolds and the Kounis hypersensitivity-associated acute thrombotic syndrome. *J Thorac Dis* 2017;9:1155-1164.
 36. Velasco E, Díaz E, Avanzas P, Rubín JM. Acute stent thrombosis due to Kounis syndrome. *Int J Cardiol* 2014;177:698-700.
 37. Kounis NG, Soufras GD, Mazarakis A. Coronary stents attract like magnet inflammatory cells and induce stent thrombosis and Kounis syndrome. *Turk Kardiyol Dern Ars* 2013;41:180-1.
 38. Raschi E, Fertonani Affini L, Antonazzo IC, Diemberger I, Poluzzi E, De Ponti F. Drug-induced Kounis syndrome: A matter of pharmacovigilance. *Int J Cardiol* 2019;274:381.
 39. Abdelghany M, Subedi R, Shah S, Kozman H. Kounis syndrome: A review article on epidemiology, diagnostic findings, management and complications of allergic acute coronary syndrome. *Int J Cardiol* 2017;232:1-4.
 40. Biteker M, Duran NE, Biteker FS, et al. Allergic myocardial infarction in childhood: Kounis syndrome. *Eur J Pediatr* 2010;169:27-9.
 41. Giovannini M, Alletto A, Koniari I, et al. Kounis Syndrome: a pediatric perspective. *Minerva Pediatr* 2020;72:383-392.
 42. Biteker M, Duran NE, Biteker FS, et al. Kounis syndrome secondary to amoxicillin/clavulanic acid use in a child. *Int J Cardiol* 2009;136:e3-5.
 43. Biteker M, Duran NE, Biteker FS, et al. Allergic myocardial infarction in childhood: Kounis syndrome. *Eur J Pediatr* 2010;169:27-9.
 44. Tripathi S, Kulikowska A, Patel PM, Hassan NE. Acute Myocardial Ischemia Following Bee Sting in an Adolescent Male: A Case Report. *Am J Case Rep* 2020;21:e922120.
 45. Terlemeş S, Eryılmaz U, Tokgöz Y, Uysal P, Co an A, Bulut Y. Kounis syndrome caused by metronidazole--a case of 14 year-old boy. *Int J Cardiol* 2015;179:222-4.

46. Ilhan E, Akbulut T, Gürsürer M. An underdiagnosed syndrome; Kounis syndrome secondary to amoxicillin/clavulanic acid use in a 16 year-old child. *Int J Cardiol* 2013;167:e90-1.
47. Ishikura M, Endo A, Sakamoto T, Tanabe J, et al. Clarithromycin-induced Coronary Vasospasms Caused Acute Coronary Syndrome in a 19-year-old Male Patient. *Intern Med* 2021;60:281-285.
48. Helbling A, Hurni T, Mueller UR, Pichler WJ. Incidence of anaphylaxis with circulatory symptoms: a study over a 3-year period comprising 940,000 inhabitants of the Swiss Canton Bern. *Clin Exp Allergy* 2004;34:285-90.
49. Renda F, Landoni G, Trotta F, et al. Kounis Syndrome: an analysis of spontaneous reports from international pharmacovigilance database. *Int J Cardiol* 2016;203:217-20.
50. Biteker M. Current understanding of Kounis syndrome. *Exp Rev Clin Immunol* 2010;6:777-88.
51. Pfister CW, Plice SG. Acute myocardial infarction during a prolonged allergic reaction to penicillin. *Am Heart J* 1950;40: 945-7.
52. Clark E. Serum carditis: morphologic cardiac alterations in man associated with serum disease. *J Am Med Assoc* 1938;110: 1098-100. Wadsworth GM, Brown CH. Serum reaction complicated by acute carditis. *J Pediatr* 1940;17:801-5.
53. Rich AR, Gregory JE. Experimental evidence that lesions with basic characteristics of rheumatic carditis can result from anaphylactic hypersensitivity. *Bull Johns Hopkins Hosp* 1943;73:239-64.
54. Czickeli H. Contribution to the problem of the allergic etiology of angina pectoris and myocardial infarct. *Klin Med Osterr Z Wiss Prakt Med* 1950;5:364-7. 6. Schultheiss E. Clinical aspects of allergic heart diseases. *Dtsch Med J* 1964;15:15-8.
55. Kounis NG, Zavras GM. Histamine-induced coronary artery spasm: the concept of allergic angina. *Br J Clin Pract* 1991;45:121-8.
56. Constantinides P. Infiltrates of activated mast cells at the site of coronary atheromatous erosion or rupture in myocardial infarction. *Circulation* 1995;92:1083.
57. Brawnwald E. Unstable angina. An etiologic approach to management. *Circulation* 1998;98:2219-22.
58. Lippi G, Buonocore R, Schirosa F, Cervellin G. Cardiac troponin I is increased in patients admitted to the emergency department with severe allergic reactions. A case-control study. *Int J Cardiol* 2015;194:68-9.
59. Cha YS, Kim H, Bang MH, et al. Evaluation of myocardial injury through serum troponin I and echocardiography in anaphylaxis. *Am J Emerg Med* 2015.
60. Kounis NG. Coronary hypersensitivity disorder: the Kounis syndrome. *Clin Ther* 2013;35:563-71.
61. Galli SJ, Nakae S, Tsai M - Mast cells in the development of adaptive immune responses. *Nat Immunol* 2005;6: 135-142. 7.
62. Galli SJ, Kalesnikoff J, Grimaldeston MA, et al. Mast cells as "tunable" effector and immunoregulatory cells: recent advances. *Annu Rev Immunol* 2005;23:749-786.
63. Sedgwick JD, Holt PG, Tunner KJ. Production of a histamine releasing lymphokine by antigen - or mitogen-stimulated human peripheral T cells. *Clin Exp Immunol* 1981;45:409-418.
64. Miyazaki D, Nakamura T, Toda M, Cheung-Chau KW, Richardson RM, Ono SJ. Macrophage inflammatory protein-1a as a costimulatory signal for mast cell mediated immediate hypersensitivity reactions. *J Clin Invest* 2005;115:434-42.
65. Ishizaka T, Ishizaka K. Activation of mast cells for mediator release through IgE receptors. *Prog Allergy* 1984;34:188-235.
66. Liu MC, Proud D, Lichtenstein LM, et al. Human lung macrophage-derived histamine-releasing activity is due to IgE-dependent factors. *J Immunol* 1986;136:2588-2595.
67. Genovese A, Spadaro G. Highlights in cardiovascular effects of histamine and H1-receptor antagonists. *Allergy* 1997;52(suppl 34):67-78.
68. Carl-McGrath S, Gräntzdörffer I, Lendeckel U, Ebert MP, Röcken C. Angiotensin II-generating enzymes, angiotensin converting enzyme (ACE) and mast cell chymase (CMA1), in gastric inflammation may be regulated by H. pylori and associated cytokines. *Pathology* 2009;41:419-27.
69. Johnson JL, Jackson CL, Angelini GD, George SJ. Activation of matrix-degrading metalloproteinases by mast cell proteases in atherosclerotic plaques. *Arterioscler Thromb Vasc Biol* 1998;18:1707-15.
70. Kounis NG, Tsigkas G, Almpanis G, Kouni SN, Kounis GN, Mazarakis A. Anaphylaxis-induced hyperfibrinolysis and the risk of Kounis syndrome: the dual action of tryptase. *Am J Emerg Med* 2011;29:1229-30.
71. Kounis NG, Giannopoulos S, Tsigkas GG, Goudevenos J. Eosinophilic responses to stent implantation and the risk of Kounis hypersensitivity associated coronary syndrome. *Int J Cardiol* 2012; 156: 125-132.
72. Saylan B, Cevik A, Firat C. Kounis syndrome, a cause of chest pain to keep in mind, may be associated with E148Q mutation. *Hong Kong J Emerg Med* 2012;19:278-82.
73. Kounis NG, Koniari I, Velissaris D, Tzani G, Hahalis G. Kounis Syndrome — not a Single-organ Arterial Disorder but a Multisystem and Multidisciplinary Disease. *Balkan Med J* 2019;36:212-221.
74. González-de-Olano D, Alvarez-Twose I, Matito A, Sánchez-Muñoz L, Kounis NG, Escribano L. Mast cell activation disorders presenting with cerebral vasospasm-related symptoms: a "Kounis-like" syndrome? *Int J Cardiol* 2011; 150:210-211.
75. Goto M, Matsuzaki M, Fuchinoue A, et al. Chronic atherosclerotic mesenteric ischemia that started to develop symptoms just after anaphylaxis. *Case Rep Gastroenterol* 2012; 6:300-308.
76. Lindsberg PJ, Strbian D, Karjalainen-Lindsberg ML. Mast cells as early responders in the regulation of acute blood-brain barrier changes after cerebral ischemia and hemorrhage. *Journal of Cerebral Blood Flow and Metabolism* 2010; 30:689-702.
77. Davidson J, Zheng F, Tajima K, et al. Anaphylactic shock decreases cerebral blood flow more than what would be

- expected from severe arterial hypotension. *Shock* 2012; 38:429–35.
78. Peláez-Pérez JM, Sánchez Casado M, Álvarez-Twose I, Kounis NG. Amoxicillin-clavulanic acid-induced type II Kounis syndrome during general anaesthesia complicated with hypoxic-ischaemic encephalopathy. *Rev Esp Anestesiol Reanim* 2021;68:161-164.
79. Anastogiannis H, Litsardopoulos P, Anastopoulou GG, et al. Irreversible diffuse hypoxic-ischemic encephalopathy, secondary to type I Kounis syndrome. *Int J Neurosci* 2020;130:746-748.
80. Erxun K, Wei L, Shuying Q. Kounis syndrome caused by chronic autoimmune urticaria: A Case Report. *J Emerg Med* 2016;50:37-40.
81. Adachi H, Ihara M, Nojima Y, Kurimoto T, Nanto S. Kounis syndrome caused by anaphylaxis without skin manifestations after cefazolin administration. *J Allergy Clin Immunol Pract* 2019;7:317-9.
82. Kounis NG, Cervellin G, Koniari I, et al. Anaphylactic cardiovascular collapse and Kounis syndrome: systemic vasodilation or coronary vasoconstriction? *Ann Transl Med* 2018;6:332.
83. Biteker M. A new classification of Kounis syndrome. *Int J Cardiol* 2010;145:553.
84. Kogias JS, Papadakis EX, Tsatiris CG, et al. Kounis syndrome: a manifestation of drug-eluting stent thrombosis associated with allergic reaction to contrast material. *Int J Cardiol* 2010;139:206-9.
85. Vetander M, Helander D, Lindquist C, et al. Classification of anaphylaxis and utility of the EAACI Task force position paper on anaphylaxis in children. *Pediatric Allergy and Immunology* 2011;22:369–73.
86. Soufras GD, Kounis GN, Kounis NG. Brain injury due to anaphylactic shock: broadening manifestations of Kounis syndrome. *Int Endod J* 2014;47(4):309-13.
87. Khan S. Mast cell tryptase level should be checked in all patients with suspected Kounis syndrome. *Eur Heart J* 2020;41:3018.
88. Kounis NG. Serum tryptase levels and Kounis syndrome. *Int J Cardiol* 2007;114:407- 8.
89. Kounis NG. Kounis syndrome: an update on epidemiology, pathogenesis, diagnosis and therapeutic management. *Clin Chem Lab Med* 2016;54:1545-59.
90. Lopez PR, Peiris AN. Kounis syndrome. *South Med J* 2010;103:1148-55.
91. Goto K, Kasama S, Sato M, Kurabayashi M. Myocardial scintigraphic evidence of Kounis syndrome: what is the aetiology of acute coronary syndrome? *Eur Heart J* 2016;37:1157.
92. Okur A, Kantarci M, Karaca L, et al. The utility of cardiac magnetic resonance imaging in Kounis syndrome. *Postepy Kardiol Interwencyjnej* 2015;11:218-23.
93. Cervellin G, Lippi G, Kounis NG. Allergic Inflammation Is Associated With Coronary Instability and a Worse Clinical Outcome After Acute Myocardial Infarction. *Circ Cardiovasc Interv* 2015;8:e003166.
94. Fassio F, Losappio L, Antolin-Amerigo D, et al. Kounis syndrome: A concise review with focus on management. *Eur J Intern Med* 2016;30:7-10.
95. Cevik C, Nugent K, Shome GP, Kounis NG. Treatment of Kounis syndrome. *Int J Cardiol* 2010;143:223-6.
96. Akgullu C, Eryilmaz U, Gungor H, et al. Myocardial infarction secondary to morphine-induced Kounis syndrome. *Herz* 2014;39:874-6.
97. Chiam E, Bellomo R, Churilov L, Weinberg L. The hemodynamic effects of intravenous paracetamol (acetaminophen) vs normal saline in cardiac surgery patients: A single center placebo controlled randomized study. *PLoS One* 2018;13:e0195931.
98. Liu Y, Lu C, Guo Q. Recurrent Type III Kounis Syndrome: Will Anti-Immunoglobulin E Drug Be Another Option? *Can J Cardiol* 2020;36:e5-966.

Correspondence:

Received: 25 May 2021

Accepted: 12 June 2021

Erika Poggiali, Emergency Department,
“Guglielmo da Saliceto” Hospital,
Via Giuseppe Taverna 49, Piacenza, Italy.

Tel.: +39 0523 303044.

E-mail: poggiali.erika@gmail.com