

R E V I E W

Platypnea-Orthodeoxia Syndrome after SARS-CoV-2 interstitial pneumonia: an overview and an update on our patient

Nicola Zanoni, Chiara Longo, Annalisa Frizzelli, Francesco Longo, Rocco Accogli, Alfredo Chetta

Department of Medicine and Surgery, Respiratory Disease and Lung Function Unit, University of Parma, Parma, Italy

Abstract. Platypnea-Orthodeoxia Syndrome (POS) is a clinical entity defined as positional dyspnoea (platypnea) and arterial desaturation (orthodeoxia) that occurs when sitting or standing up and usually resolves by lying down. Up to April 25th 2021, eleven cases of POS after SARS-CoV-2 pneumonia have been reported on Pubmed. Accordingly, SARS-CoV-2 infection may be considered as an emergent cause of POS due to an increase in ventilation/perfusion (V/Q) mismatch. In this article we provide an update on the patient with POS after fibrotic evolution of SARS-CoV-2 interstitial pneumonia, which we previously reported and we discuss the case reports of POS due to SARS-CoV-2 infection. (www.actabiomedica.it)

Key words: Platypnea-Orthodeoxia Syndrome, Platypnea, Orthodeoxia, Pulmonary Fibrosis, SARS-CoV-2

Introduction

Platypnea-Orthodeoxia Syndrome (POS) is a clinical entity defined as positional dyspnoea (platypnea) and arterial desaturation that occurs when sitting or standing up (orthodeoxia) and usually resolves by lying down. The drop in oxygen saturation is considered as significant, when PaO₂ falls greater than 4 mmHg or SaO₂ than 5% from supine to an upright position (1). Although not yet well clarified, the cause of the syndrome is theorized to be the blend of de-oxygenated venous blood into the oxygenated arterial blood via a pathologic shunt (1). POS causes are classified by the shunt causes: intracardiac abnormalities (the vast majority of cases), extracardiac abnormalities (mostly pulmonary) and miscellaneous etiologies (1). Recently, some case report of POS following the SARS-CoV-2 infection have been reported in the literature and the increase in ventilation/perfusion (V/Q) mismatch due to SARS-CoV-2 interstitial pneumonia

may be considered as an emergent pulmonary abnormality causing POS (2-5). In this article we provide an update on the patient with POS after fibrotic evolution of SARS-CoV-2 interstitial pneumonia which we previously reported (5), and we discuss the case reports of POS due to SARS-CoV-2 infection.

Our Case

In our centre we only found one case of not reversible POS following COVID-19 pneumonia (5). In March 2020 a 76-year-old woman presented to our hospital's ER complaining of fever, cough and dyspnoea. Her medical history included only a mild aortic and tricuspid insufficiency and hiatal hernia. She never smoked. Her arterial blood gas (ABG) analysis on room air revealed hypocapnic hypoxaemia (PaO₂ 59 mmHg, PaCO₂ 32 mmHg and pH 7.49) and a nasopharyngeal swab resulted positive for SARS-CoV-2.

A chest high-resolution computed tomography (HRCT) scan revealed a bilateral interstitial pneumonia with disease extension around 35% (Figure. 1).

She was hospitalized and was treated with Hydroxychloroquine, Darunavir/Cobicistat and oxygen therapy. After a week because of the worsening of respiratory failure, she performed a second chest CT with contrast fluid, which showed a bilateral segmental Pulmonary Embolism (PE) and an increased extension score of 60% (Figure. 2).

During the hospital stay she was also treated with anticoagulant, empirical antibiotic, intravenous steroids and Continuous Positive Airway Pressure (CPAP). A single dose of Tocilizumab was also administered. A control CT scan done after two weeks showed an almost complete resolution of the pulmonary embolism and the onset of interstitial pneumonia's initial fibrotic evolution (Figure. 3).

The patient was then transferred to our Unit, where she progressively complained of breathlessness while sitting or standing upright, even with

supplemental oxygen (Platypnea) and showed Orthodeoxia (SpO₂ 99% on 4 l/min O₂ by nasal cannula in the supine position vs SpO₂ 84% on 4 l/min O₂ by nasal cannula in the seated position). Bubble-contrast echocardiography in recumbent, sitting and upright positions revealed no intracardiac or intrapulmonary shunts. A ventilation/perfusion (V/Q) scan was then performed both in supine and sitting position and when the patient switched to the sitting position, a reduction in kc/s both of the ventilation (~90%) and the perfusion (~60%) was observed. The patient was then treated for four weeks with high doses of steroids, which were then gradually reduced. A control chest TC after five weeks showed presence of pneumomediastinum, a parenchymal fibrotic pattern with basal subpleural predominance and traction bronchiectasis (Figure. 4).

At discharge, the patient still complained of Platypnea and Orthodeoxia (SpO₂ 97% on 2 l/min O₂ by nasal cannula in the supine position vs SpO₂ 87% on 2 l/min O₂ by nasal cannula while in the

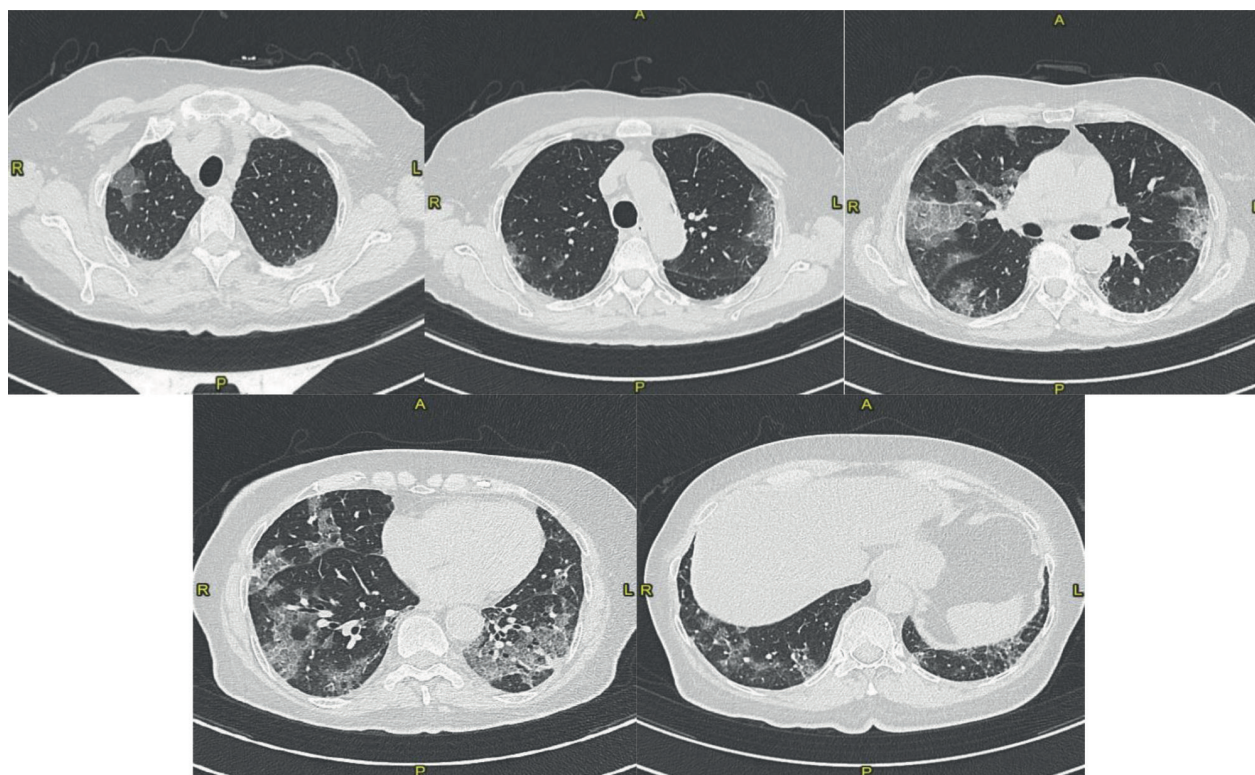


Figure 1. CT at the 1st hospitalization (March 2020): Bilateral ground glass opacities with patchy distribution - visual score of 35%.

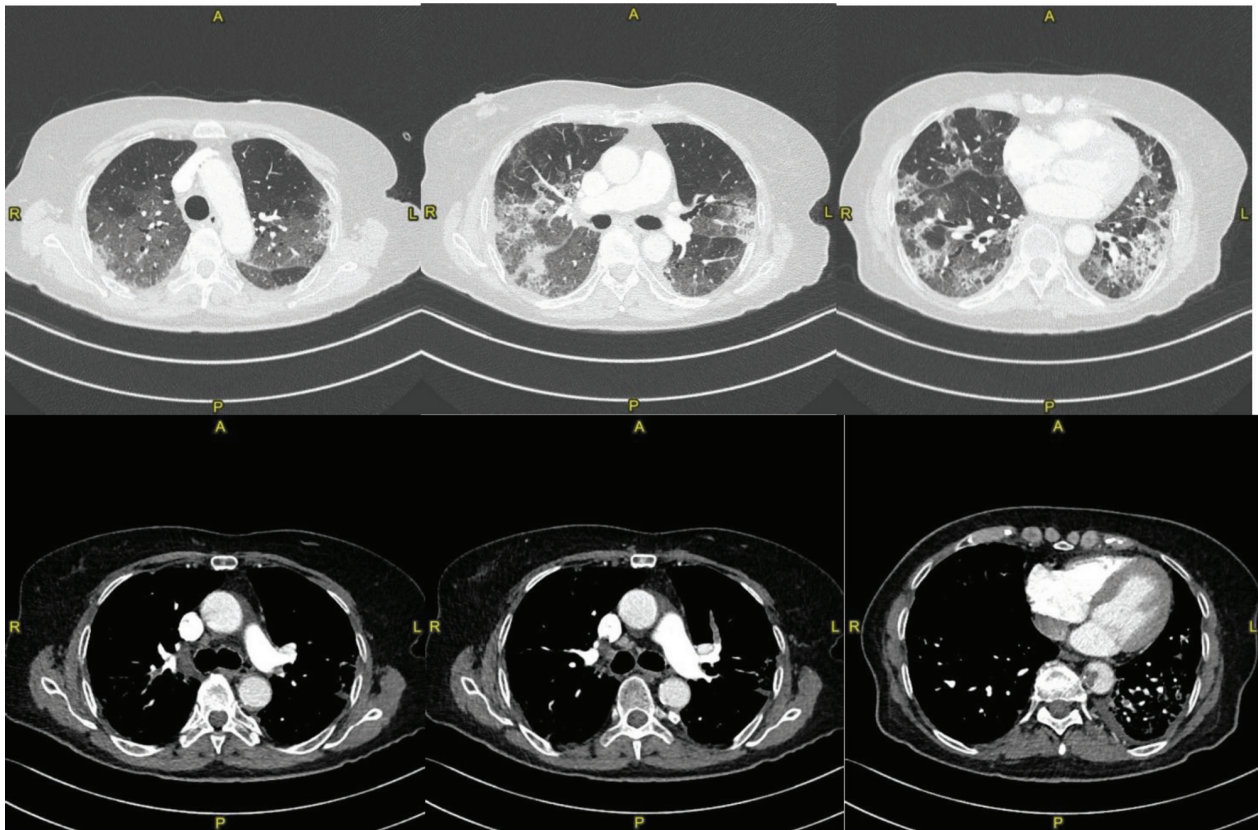


Figure 2. CT scan after worsening gas exchange (April 2020): Bilateral segmental pulmonary embolism involving the branch for the posterior segment of the right upper lobe, anterior segmental branch of the left upper lobe and the branch for the dorsal segment of the left lower lobe. Worsening of ground glass opacities (visual score of 60%).

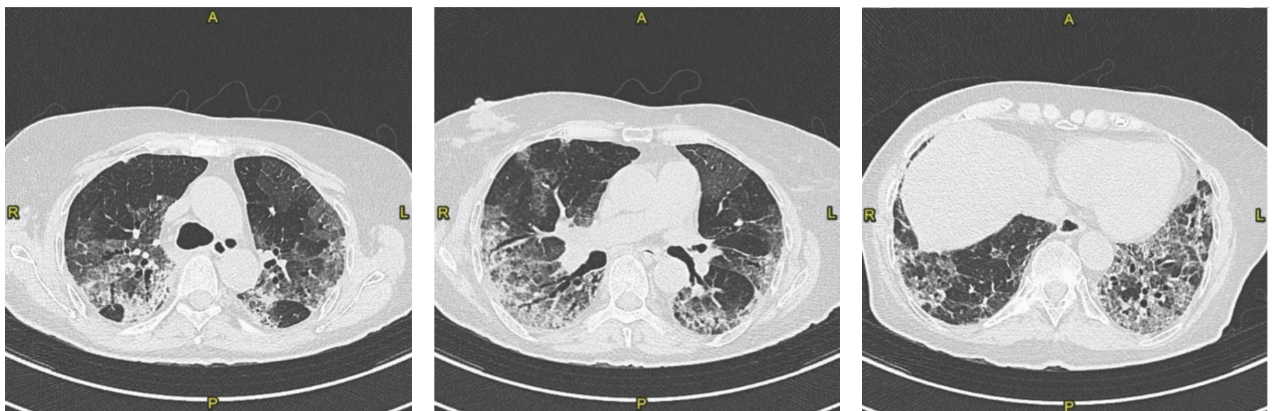


Figure 3. CT scan after 2 weeks from the previous one (April 2020): Fibrotic evolution of interstitial pneumonia. Decrease of the ground glass opacities with peribronchial consolidating areas of organized appearance with contextual traction bronchiectasis. Visual score of 60%.

seated position). She was discharged with long term oxygen therapy, anticoagulant treatment, diuretic and low dose azithromycin every other day.

After two months of clinical stability, the patient went to the ER of our hospital complaining of worsening dyspnoea while resting or doing minimal physical efforts.

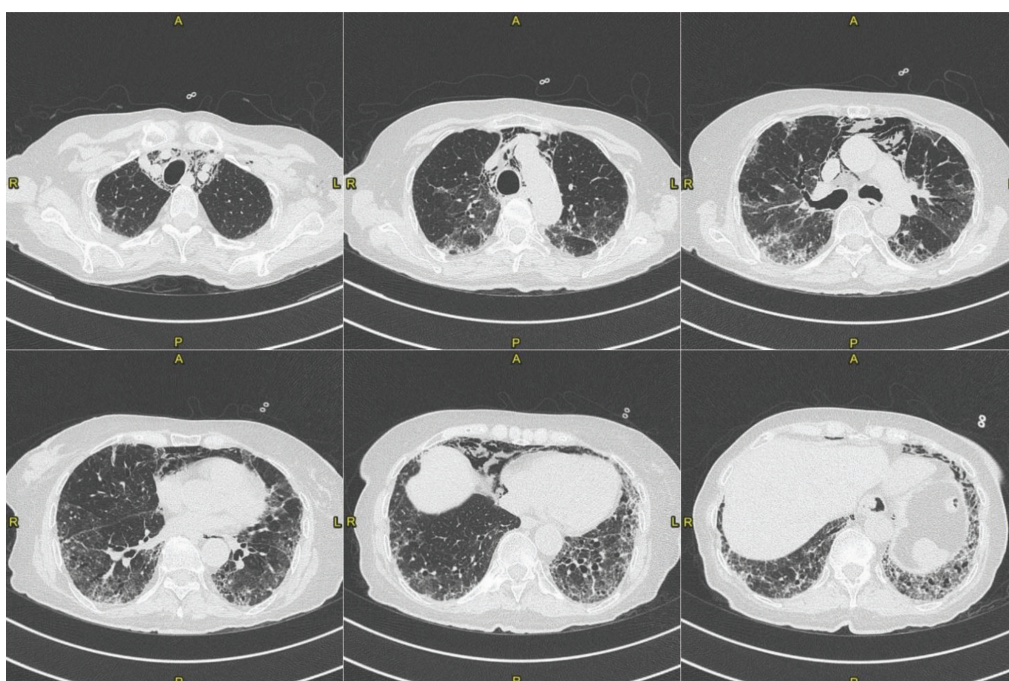


Figure 4. CT scan at the patient's discharge (June 2020): Ground glass opacities with patchy distribution, persistence of the basal fibrotic pattern, with traction bronchiectasis. Presence of pneumomediastinum. Visual score of 50%.

At the ER:

1. Vital Parameters: SpO₂ 70% on room air, BP 160/70 mmHg, non-febrile.
2. ABG on reservoir Mask+10 l/min O₂: pH 7,43, PaO₂ 130 mmHg, PaCO₂ 39,3 mmHg, HCO₃⁻ 26 mmol/l, sO₂ 97,7%, lac 3,3 mmol/L.
3. The blood lab tests showed a slightly increased C-RP (28,2 mg/l).
4. The nasopharyngeal swab for SARS-CoV-2 was negative.
5. HRCT: Worsening of the fibrosing interstitial lung disease, (extension score 75%), new isolated parenchymal consolidation in the inferior left lobe, suggestive of infection (maybe of fungal nature). (Figure. 5).

On admission to our ward, she showed diffused inspiratory crackles on chest auscultation.

POS was still present, and the dyspnoea significantly worsened since the previous hospital discharge.

We started EV-treatment with moderated doses of Methylprednisolone and empirical antibiotic/antifungal therapy (Ceftriaxone, Azithromycin and Fluconazole).

After ten days of therapy the patient showed no improvement, maintaining clinical stability with oxygen therapy with FiO₂ 40-50% on Venturi Mask. After consulting with an infectious disease specialist, we changed antifungal drug, switching to *Liposomal Amphotericin B*. No bronchial aspiration or lavage could be performed because of clinical instability and a nasopharyngeal aspirate showed no signs of respiratory viruses. After ten days without any significant clinical change, we increased drastically the steroid therapy for three days (750 mg of Methylprednisolone EV on day 1, 1000 mg on days 2 and 3) and started anti-fibrotic therapy as a last-ditch effort to slow down the fibrosing process (6), using Nintedanib 150 mg twice a day. A Chest CT scan done five weeks since the admission to our ward showed almost no changes of the fibrotic pattern and of the lower left lobe consolidation. The known pneumomediastinum significantly worsened (Figure. 6).

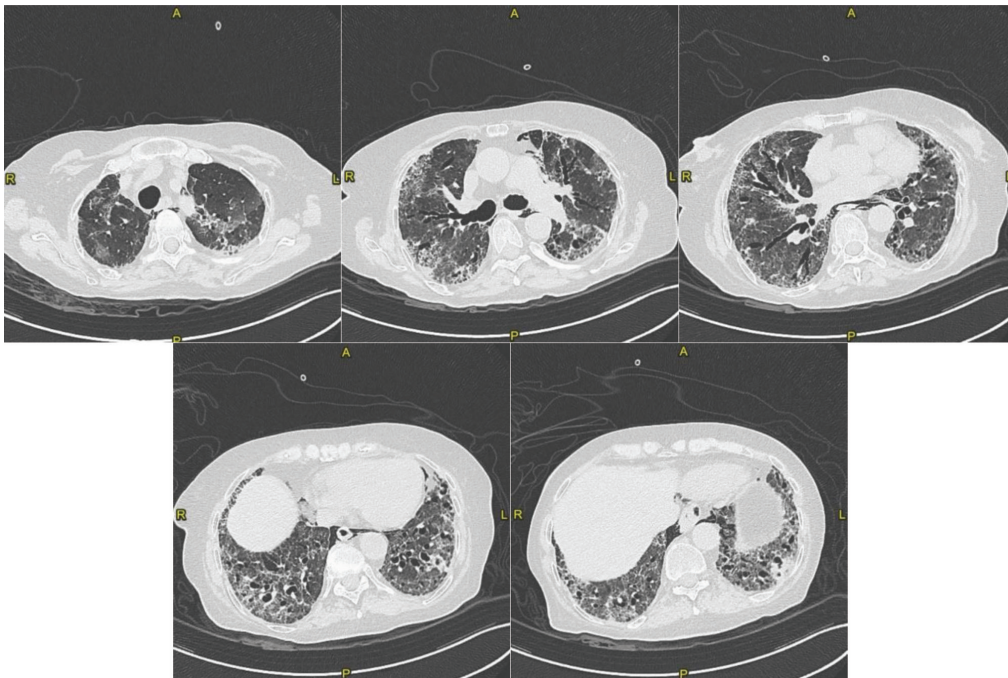


Figure 5. CT scan at 2nd hospitalization (August 2020): The parenchymal fibrosing pattern is globally worsened (extension score 75%), showing new ground glass areas (superior lobes) and traction bronchiectasis. New parenchymal peribronchial consolidation in the inferior left lobe, suggestive of infection (maybe of fungal nature). Significant decrease of the extension of the known pneumomediastinum.

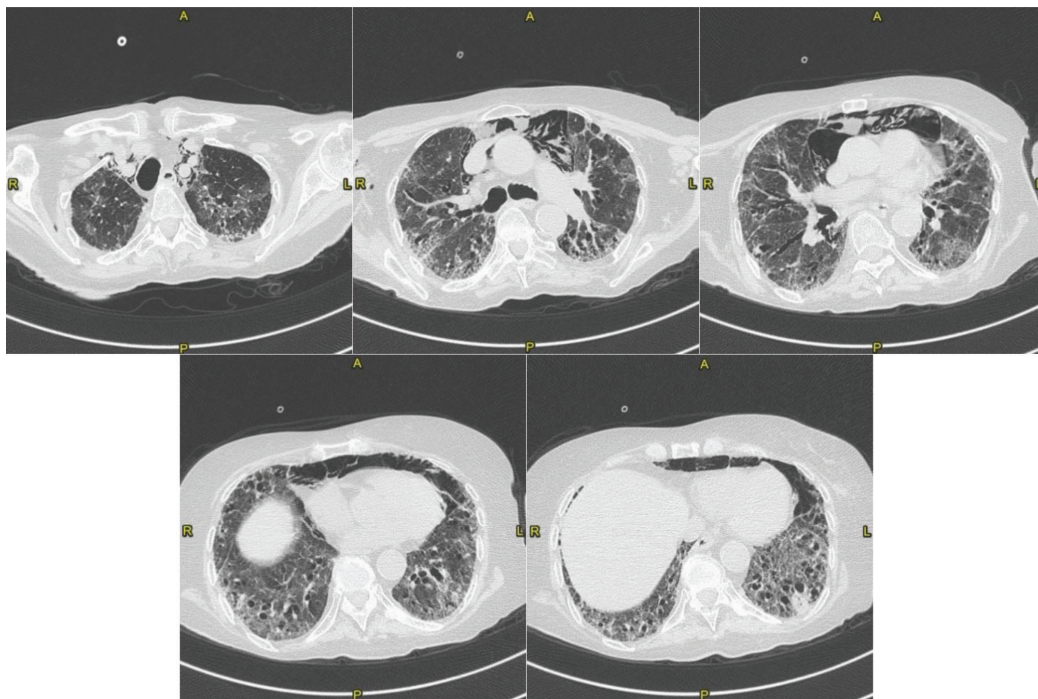


Figure 6. CT scan after 5 weeks since admission (October 2020): The parenchymal fibrosing pattern is unchanged. The known parenchymal peribronchial consolidation of the inferior left lobe is also unchanged. Significant increased the known pneumomediastinum.

The clinical status of the patient then suddenly changed for the worst with the onset of severe cough, dyspnoea while resting and desaturation (she showed SpO₂ around 91 % with Reservoir Mask + 15 l/min O₂ while resting in the supine position). After almost 8 weeks since admission, the patient died. In the last days she was sedated with morphine in order to alleviate the severe dyspnoea.

Discussion

SARS-CoV-2 infection may be an emergent cause of POS. Up to April 25th 2021, eleven cases (2-5,8) after SARS-CoV-2 pneumonia have been reported on Pubmed (the research was done by searching the keywords 'Platypnea' and/or 'Orthodeoxia' and 'SARS-CoV-2' and/or 'COVID').

One case was discussed by Singh K. et al. (2). Their patient has had severe COVID-19 disease that required admission in Intensive Care Unit (ICU). After an initial clinical improvement, he developed POS. Bubble echocardiography was negative for intrapulmonary or intracardiac shunts and a venous lower limbs ultrasound was negative for deep vein thrombosis. A chest CT-scan was suggestive of bilateral basal lung fibrosis. POS improved after 7 days of physiotherapy and the patient was discharged on room air.

Five cases with POS after severe SARS-CoV-2 pneumonia were reported by Tan G.P. et al. (3). All patients were admitted to the ICU and underwent invasive mechanical ventilation. Everyone reported had a Chest CT scan showing multi-lobar mixed ground glass opacities and consolidation particularly in the posterior lung segments and lower lobes; out of five patients: one showed early fibrotic change, one had a cavitory pneumonia (without positive microbiology), one had small segmental pulmonary embolism and signs of early fibrotic evolution and two patients developed ventilator-associated pneumonia. In these cases, POS resolved at the latest by 39 days. The authors hypothesized that the mechanisms underlying COVID-19 ARDS-associated POS are related to a gravitational exacerbation of intrapulmonary shunting due to COVID-19-associated vasculopathy (e.g. microangiopathy, microthrombi) and alveolar hypoventilation. Factors that decrease cardiac output could contribute to further reduction in the areas of non-dependent zone of blood flow of the

lungs, thereby worsening POS. A reduced cardiac output typically follows prolonged bedrest.

Siddique M. et al. (4) reported a case of POS after COVID-19 pneumonia. A transthoracic echocardiogram showed evidence of pulmonary hypertension and a bubble study raised the concern for intrapulmonary shunt. Arterial CT pulmonary angiograms were negative for pulmonary embolism and showed worsening interstitial involvement. Pneumomediastinum was temporarily present and resolved later on. A lung perfusion scan was performed, estimating a low probability of pulmonary embolism and a lung shunt fraction of 29% (reference value <7%), suggestive of right-to-left shunt. In the paper, authors did not specify if POS was persistent or transient; in any case the patient was discharged with oxygen therapy.

Oldani S. et al. (7) presented a case admitted in to their Semi-Intensive Respiratory Care Unit for SARS-CoV-2 pneumonia. After the weaning from CPAP, the patient developed clinical evidence of platypnea orthodeoxia (requiring increase in O₂ flow while seated).

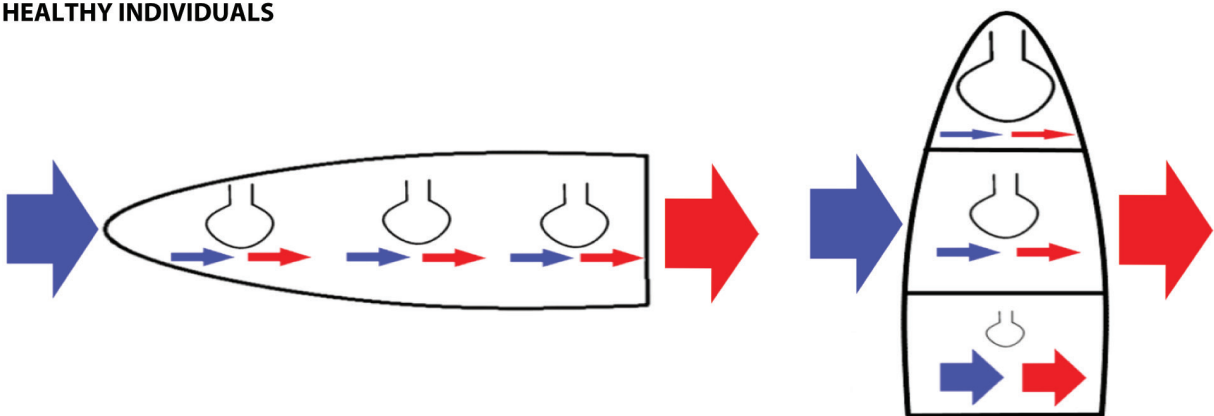
A CT scan done after 18 days since the onset of symptoms showed bilateral ground glass attenuation, crazy paving and consolidation, mainly in the lower lobes. The authors did not specify if POS was persistent or resolved during the hospitalization and hypothesized a possible cause for POS after SARS-CoV-2 pneumonia similar to hepatopulmonary syndrome (HPS) (7). HPS is characterized by lower levels of arterial blood oxygenation due to intrapulmonary vascular dilations and shunting. HPS patients have extremely dilated pulmonary vasculature, with almost preserved ventilation, and hypoxemia is caused by a reduction of the V/Q ratio. The vascular enlargement in HPS is usually more represented in the lower regions of the lungs (8); this may lead to a sudden increase in perfusion of these basal areas of the lungs as soon as the patient stands upright. The increase of vascular flow may cause further reduction in V/Q ratio, hence a swift worsening of hypoxemia in sitting position. Oldani S. et al. (7) propose a similar mechanism in patients with POS and phenotype L COVID-19 (typical of the early stage of lung disease, showing preserved lung compliance, low ventilation/perfusion ratio, low weight and low reclutability) (11).

Two cases of POS were reported by Tham SL. et al. (8). The first patient required mechanical ventilation for almost two months and tracheostomy was performed

due to persistent respiratory failure and multiple episodes of ventilator-associated pneumonia. He developed POS after eighteen days since the symptoms onset (noticed after the first verticalization attempt). A CT angiography showed diffuse patchy air space opacities and ground-glass attenuation of both lungs, with no evidence of pulmonary embolism or intrapulmonary vascular malformation. Transthoracic echocardiogram was negative for intracardiac shunt and demonstrated a mild pulmonary hypertension. He underwent rehabilitation and experienced POS for 65 days, with complete resolution thereafter. The patient did not require any supplemental oxygen use upon discharge. The second case (8) required high flow oxygen therapy, and POS was noticed after

twenty-six days since the onset of the symptoms. A CT angiography revealed bilateral patchy airspace consolidation with ground glass changes. There was no evidence of pulmonary embolism or intrapulmonary vascular malformation. He had a normal transthoracic echocardiogram, which did not reveal any intracardiac shunt. The patient experienced POS for 22 days, followed by a complete resolution without requiring supplemental oxygen on discharge. The cause of the orthodeoxia in these patients is not yet completely understood, although it's known that parenchymal abnormalities involving the lung bases can accentuate the V/Q mismatch in the upright position leading to a physiologic shunt that can present as POS (1) (figure. 7).

HEALTHY INDIVIDUALS



POS PATIENT

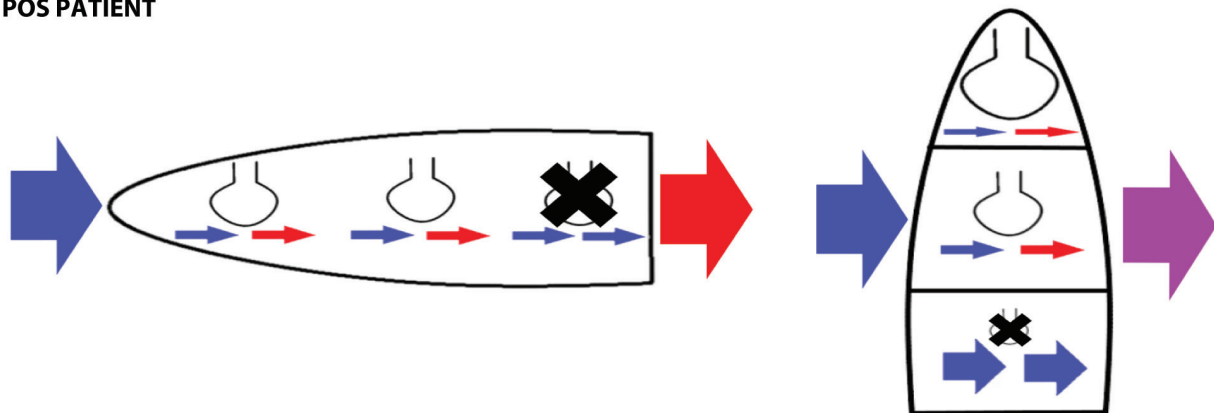


Figure 7. Ventilation/Perfusion (V/Q) and shunt in healthy and in POS. Passing from the supine position to the orthostatic one (left to right in the image), a V/Q gradient is formed physiologically. Due to gravity, in the orthostatic position the upper zone of the lung is highly ventilated but poorly perfused (Zone I) in contrast to the middle one (Zone II) and the lower one (Zone III), where more perfusion is present. Parenchymal lung diseases involving mostly the bases of the lung can cause intrapulmonary shunting by accentuating the V/Q mismatch. **Legend:** Blue arrow: Deoxygenated blood; Red arrow: Oxygenated blood; Purple arrow: Blend of deoxygenated and oxygenated blood; Black cross: lung zone with interstitial disease.

The frequent presence of PE in COVID patients may also contribute to the worsening of the V/Q mismatch.

To the best of our knowledge, we have reported the only case of POS after SARS-CoV-2 pneumonia that persisted until the death of the patient. The worst outcome may be due to the extremely severe extension of the fibrotic interstitial pattern (50% at the first discharge, on June 2020 and 75% on August 2020), the pulmonary embolism during the SARS-CoV-2 infection and the presence of pneumomediastinum that never completely resolved (pneumomediastinum is known to be associated with barotrauma and increase mortality in SARS-CoV-2 infected patient (9), and spontaneous pneumomediastinum to SARS-CoV infection) (10). On the contrary, the transient nature of some cases of POS after SARS-CoV-2 pneumonia may be caused by the gradual reduction of the lung's interstitial involvement, improving the V/Q ratio.

Conclusions

SARS-CoV-2 interstitial pneumonia may be considered an emergent cause of pulmonary POS, that it's reported in the literature to be rarer than the cardiac causes. In particular, the review by Agrawal A. et al. (1) that covered more than 66 years of literature (from 1949 to 2016) and a total of 239 patients, reported only 31 cases of pulmonary POS (9 of whom had parenchymal disease and 22 pulmonary arteriovenous malformation). Interestingly, in less than 2 years there are at least 11 cases of pulmonary POS due to the SARS-CoV-2 pandemic.

Even if the definitive etiological mechanism (or mechanisms) have yet to be completely understood, it's possible that both interstitial changes and vascular involvement in COVID-19 pneumonia are involved. According to Oldani S. et al. (7) POS can be explained mainly with vascular alteration, similarly to what happens in HPS.

Conflict of Interest: Each author declares that he or she has no commercial associations (e.g. consultancies, stock ownership, equity interest, patent/licensing arrangement etc.) that might pose a conflict of interest in connection with the submitted article

References

1. Agrawal A, Palkar A, Talwar A. The multiple dimensions of Platypnea-Orthodeoxia syndrome: A review. *Respir Med.* 2017; 129:31–38.
2. Singh K, Kadnur H, Ray A et al. Platypnea-orthodeoxia in a patient with severe COVID-19 pneumonia. *Monaldi Arch Chest Dis.* 2020 Dec 23;90(4). doi: 10.4081/monaldi.2020.1609. PMID: 33372742.
3. Tan GP, Ho S, Fan BE et al. Reversible platypnea-orthodeoxia in COVID-19 acute respiratory distress syndrome survivors. *Respir Physiol Neurobiol.* 2020 Nov;282:103515. doi: 10.1016/j.resp.2020.103515. Epub 2020 Aug 7. PMID: 32777268; PMCID: PMC7413098.
4. Siddique M, Nawaz MK, Khalid MB, Rai A. Right to Left Intrapulmonary Shunt in a Case with COVID-19-associated Pneumonia. *J Coll Physicians Surg Pak.* 2021 Jan;30(1):S23-S25. doi: 10.29271/jcpsp.2021.01.S23. PMID: 33650419.
5. Longo C, Ruffini L, Zaroni N et al. Platypnea-orthodeoxia after fibrotic evolution of SARS-CoV-2 interstitial pneumonia. A case report. *Acta Biomed.* 2020 Aug 10;91(3):ahead of print. doi: 10.23750/abm.v91i3.10386. PMID: 32921749; PMCID: PMC7716968.
6. George PM, Wells AU, Jenkins RG. Pulmonary fibrosis and COVID-19: the potential role for antifibrotic therapy. *Lancet Respir Med.* 2020 Aug;8(8):807-815. doi: 10.1016/S2213-2600(20)30225-3. Epub 2020 May 15. PMID: 32422178; PMCID: PMC7228727.
7. Oldani S, Ravaglia C, Bensai S et al. Pathophysiology of light phenotype SARS-CoV-2 interstitial pneumonia: from histopathological features to clinical presentations. *Pulmonology.* 2021 Mar 26:S2531-0437(21)00078-7. doi: 10.1016/j.pulmoe.2021.03.003. Epub ahead of print. PMID: 33832850; PMCID: PMC7997696.
8. Tham SL, Ong PL, Lee AJY, Tay MRJ. Rehabilitation of Patients with Platypnea-Orthodeoxia Syndrome in COVID-19 Pneumonia: Two Case Reports. *J Rehabil Med Clin Commun.* 2020;3:1000044. Published 2020 Nov 20. doi:10.2340/20030711-1000044
9. Elsaaran H, AlQinai S, AlTarrah D et al. Prevalence and risk factors of barotrauma in Covid-19 patients admitted to an intensive care unit in Kuwait; a retrospective cohort study. *Ann Med Surg (Lond).* 2021 Mar;63:102141. doi:

- 10.1016/j.amsu.2021.01.089. Epub 2021 Feb 5. PMID: 33564462; PMCID: PMC7862029.
10. Chu CM, Leung YY, Hui JY et al. Spontaneous pneumomediastinum in patients with severe acute respiratory syndrome. *Eur Respir J*. 2004 Jun;23(6):802-4. doi: 10.1183/09031936.04.00096404. PMID: 15218989.
11. Gattinoni, L., Chiumello, D. & Rossi, S. COVID-19 pneumonia: ARDS or not?. *Crit Care* **24**, 154 (2020). <https://doi.org/10.1186/s13054-020-02880-z>.

Correspondence:

Received: 1 May 2021

Accepted: 30 May 2021

Nicola Zanoni, MD

Department of Medicine and Surgery,
Respiratory Disease and Lung Function Unit,
University of Parma,
Parma, Italy