

Kinetic and Kinematic analysis of ACL reconstruction in association with lateral-extrararticular tenodesis of the knee in revision surgery: a pilot study.

Paolo Di Benedetto¹⁻², Michele Mario Buttironi¹, Francesco Mancuso¹, Federico Roman³, Daniele Vidi²⁻⁴, Araldo Causero¹⁻²

¹Clinics of Orthopedics ASU FC – Udine - Ple S.Maria della Misericordia, 15 - 33100 Udine; ²Medical Department – University of Udine; ³Orthopaedics and Traumatology Unit, Cattinara Hospital – ASUGI, Strada di Fiume 447, 34149 Trieste (Italy); ⁴IMFR Gervasutta - Udine

Abstract. *Background.* Anterior cruciate ligament reconstructions are a very frequent surgery. The key role of the anterolateral ligament in the knee rotational stability has been undelighted in recent years. Extra-articular tenodesis in association with ACL reconstructions, serves to eliminate anterolateral rotatory instability. The aim of our study is to compare treated knees with the contralateral uninjured knee in those cases whom been treated with ACL arthroscopic reconstruction and lateral extra-articular tenodesis in revision surgery, and evaluate clinical results with kinematic and kinetic examinations methods. *Materials and methods.* Sixteen patients (10 males and 6 females) with ages from 21 to 37 had been treated at the Orthopaedic Clinic of Udine for failure of previous ACL reconstruction. In all patients was performed ACL arthroscopic reconstruction with the association of a lateral extra-articular tenodesis (Coker-Arnold). We have decided to asses the patients at one year after surgery with GNRB arthrometer and Bioval inertial sensor system. *Results.* All patients treated with arthroscopic ACL reconstruction and lateral extra-articular tenodesis have regained pre-injury sagittal knee stability and gait dynamics. *Conclusions.* Clinical and instrumental evaluation showed how a combination of procedures can restore the kinematic and stability of a joint, even if the procedures performed are not anatomical. These are only preliminary data. (www.actabiomedica.it)

Keywords: ACL, Revision, Kinematic, Kinetic, Artrometer, Lateral extra-articular, Tenodesis, Reconstruction.

Introduction

Anterior cruciate ligament (ACL) reconstructions are a very frequent surgery. In the USA the annual incidence of ACL reconstructions is about 200,000 (1,2). We must undelights how the annual incidence of revision of a previous surgery is growing (2,3). The failure of an ACL reconstruction is a simple clinical diagnosis, but a very hard etiological diagnosis often is impossible to define a single cause. The role of numerous factors, also anatomical peculiarity like lateral tibial slope, determines in patients a greater risk of failure (4,5).

The key role of the anterolateral ligament in the knee rotational stability has been undelighted in recent years (6). ALL is a capsular thickening in the substance of the anterolateral capsule and behaves similarly to a ligament structure. ALL combined with ITB (iliotibial band) create a support in the anterolateral side of the knee reducing internal rotation of the tibia (7).

Slette et al (8) have analyzed the importance of the anterolateral soft tissue and the synergy with the ACL in the knee movements. From his work is possible to understand that most of the ACL lesions are associated with anterolateral ligament rupture and that can lead to an increased rotatory instability instead of

an isolated ACL injury (9). The traditional approach to ACL injury probably needs to be revised: the association of anterolateral peripheral lesions with pivot lesion of the knee is much more frequent than previously detected. In fact, Terry et al (10) demonstrated 82 cases in which 93% of them had concurrent anterolateral capsular injury and ACL tear.

Orthopedic surgeons, with lateral extra-articular tenodesis (LET) in association with ACL reconstructions, search to eliminate anterolateral rotatory instability (11-13). With the advent of lateral extra-articular tenodesis some surgeons sustained the theory that some procedures were non-anatomical and that could have led to failures and joint residual instability or stiffness.

The aim of our study is to compare treated knees with the contralateral uninjured knee in those cases whom been treated with ACL arthroscopic reconstruction and lateral extra-articular tenodesis, after failure of previous treatments, and evaluate clinical results with kinematic and kinetic examinations with the help of Bioval System and GNRB arthrometer and analyze side-to-side differences in the anterior tibial translation and gait kinematic between healthy and operated knees (14).

Methods

In a period between March 2019 and March 2020 sixteen patients (10 males and 6 females) with ages from 21 to 37 had been treated at the Orthopedic Clinic of Udine for failure of ACL reconstruction. Only 10 patients performed the primary ACL reconstruction in our Clinic with the same surgery technique, using gracilis and semitendinosus (G-ST) autologous tendons graft; the others 6 patient was previously treated in different hospitals but in any case, all of them with a technique who provide G-ST graft.

The revision surgery was performed with ACL arthroscopic reconstruction with the association of a lateral extra-articular tenodesis (15,16). During last years we try different technique for the lateral tenodesis and decide to use a Cocker-Arnold technique for performed this kind of treatment in our Hospital. All the patients were treated after diagnosis of failure of previous intra-articular reconstruction: patients were clinically evalu-

ated with anterior drawer, Lachman and pivot shift test. Imaging investigation with X-rays and MRIs who demonstrated a complete lesion of ACL.

In accordance with Di Benedetto et al, our preference in ACL revision surgery was towards allograft tendons – cryopreserved gracilis and semitendinosus – associated with a transtibial technique. In all the patients we utilized a femoral suspension system (Top Traction System-TTS) with a secure screw femoral cortical fixation.

Lateral extra-articular tenodesis was performed immediately after ACL reconstruction according with Cocker-Arnold technique (15,17): a longitudinal incision was performed in the lateral context of the knee in line with the iliotibial band, long about 15 cm, curved posteriorly in the distal section. It was identified the distal tract of the iliotibial (IT) band and his insertion to the Gerdy's tubercle. With a scalpel it was detached a strip of IT band long approximately 12 cm and 1 cm wide with intact distal insertion to the Gerdy's. This strip was basted with re-absorbable braided wire; then it was passed beneath the FCL, overturned and sutured with hi-resistance wires to the Gerdy's tubercle with the knee flexed at 90° and the tibia held in the maximum external rotation.

We have decided to assess the patients at one year after surgery, when the post-operation and rehabilitation period was ended: for the first step, all patients were evaluated for anterior-posterior residual laxity with GNRB arthrometer (18). The side-to-side differences in the anterior tibial translation (DELTA L in mm) was measured at 100 N, 150 N and 200 N. Software was able to recreate a graphic representation of the point-to-point deformity for single drawer forces applied with GNRB arthrometer. Differences greater than 2 mm between treated knee compared with the contralateral were considered as residual instability after surgical procedure.

The second step of measurement was based on Bioval inertial sensor system (Movea, France), a system that uses inertial sensors allowing the detection of kinematic parameters of the body on a 3D dimension. The software acquires data from MotionPods with wireless sensors. Each pod contains triaxle gyroscopes, accelerometers and magnetometers. The pods are held in place with tape or elastic bands without causing limitation of motion of the patient's joints. With the

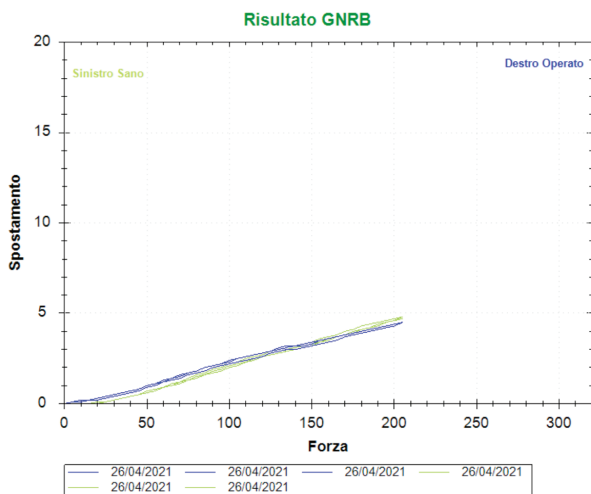


Figure 1. GNRB graphic model of anterior directed loading of operated knee (blue line) and healthy knee (green line). Forces applied at 50N,100N,150N and 200N demonstrates side-to-side differences less then 2mm

data acquired it was possible to obtain a graphic of the angular variation during walk and compare the treated leg with the opponent healthy one.

Continuous variables are presented through mean and standard deviation (SD); variables' distribution was assessed by the Shapiro-Wilk test. Group comparisons (ACR + LET vs control) were performed through Wilcoxon rank-sum (Mann-Whitney) test or two sample t-test as appropriate. An α -level equal to 0.05 was assumed as guide for significance. All analysis were performed using STATA software version 13 (StataCorp, College Station, TX).

Results

All patients treated with arthroscopic ACL reconstruction and lateral extra-articular tenodesis have regained pre-injury range of motion at time of evaluation (one-year post-surgery).

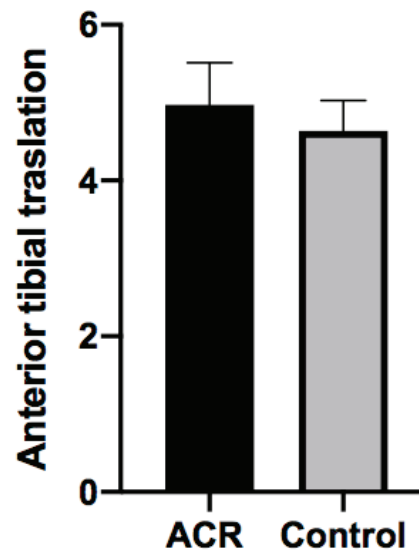
Patients undergoing GNRB arthrometer evaluation have demonstrated the restoration of sagittal knee stability (Fig. 1): the comparison between the operated knee and the healthy one have showed a difference less then 2.0 mm meaning that the treated knee have reacquired the same sagittal stability and have demonstrated that the ACL graft is able to sustain forces up to

200 N of anterior tibial translation. (Tab.1 and Graph. 1). GNRB evaluation shown a mean difference of 0,33 mm (SD 0,16) at 200 N ($p=0,2155$).

Table 1. Anterior tibial traslation mesured in mm with GNRB at 200 N result for each patient

ACR+LET	Control
4,5	4,4
4,8	4,5
5,6	4,5
5,4	5,3
4,5	4,6
6,1	5,1
5,1	4,3
5,2	3,9
4,3	4,4
4,7	4,8
5	5
5,1	5,2
4,4	4,5
4,7	5
4,4	4,4
5,8	4,3

200 N arthrometer test



Graph. 1. Anterior tibial traslation mesured in mm with GNRB at 200 N (mean and SD). Comparison between operated knee and the uninjured contralateral knee.

The subsequent kinematic examination by Bioval System analysis demonstrates that treated knee stability index during walking is comparable with the healthy knee: in flexion the mean stability index is 8,97 (DS 2,53) in treated knee and 9,76 (DS 2,63) in healthy knee with a non statistically significant 0,52 p-value. Meanwhile in extension the mean stability index is 5,90 (DS 1,23) in treated knee and 5,25 (DS 0,96) in healthy knee with a non statistically significant 0,79 p-value. In particular, kinematic analysis shown that treated knee has reacquired the same stability as the untreated knee, is possibile to underline the absence of residual instability after ACL reconstruction and LTE tenodesis (Fig. 2). Moreover, angles acquired with Bioval system shows comparable results between both legs in single leg squatting (Fig. 3). Each difference measured was found not to be statistically significant.

Discussion

In literature early results for procedures, they see the association of intra-articular reconstruction of ACL and LET were encouraging (13,19). Dejour

et al (20) evaluated outcomes in more than 200 cases treated with a bone-to-bone with patellar tendon re-contraction associated at a Lemaire procedure (21) at a minimum of 3 years of follow-up. In 83% of cases have registered good or excellent functional results, although the pivot shift was described as not completely reduced in 24%. Also Rackemann et al (22) reported the results of 714 knees treated with a patella tendon reconstruction augmented with a MacIntosh procedure (23) at 6 years' follow-up: the results were good in 93%. Bertoia et al (24) have registered good or excellent outcomes using the MacIntosh II technique, with the pivot shift reduction. Zarins and Rowe (25) described a modification of MacIntosh over the top procedure. 88% patients reported good or excellent results with the procedure, with pivot shift reduced in 91%.

From these data it can be deduced how the association of the intra-articular and extra-articular procedure is advantageous. In our study we underline the importance of LTE procedure combined with ACL reconstruction with the aim reduce the risk of ACLR failures and increase the tibial rotation stability during walking.

Lateral extra-articular procedures were considered as non-anatomical and were considered the cause

Single leg squatting

Flessione/Estensione sotto carico						
Date	Side	Flexion	Extension	Median widnes	Instability	
					Flexion	Extension
26/04/2021	Left	37°	3°	40°	14,90	5,89
26/04/2021	Right	35°	2°	36°	6,86	2,00

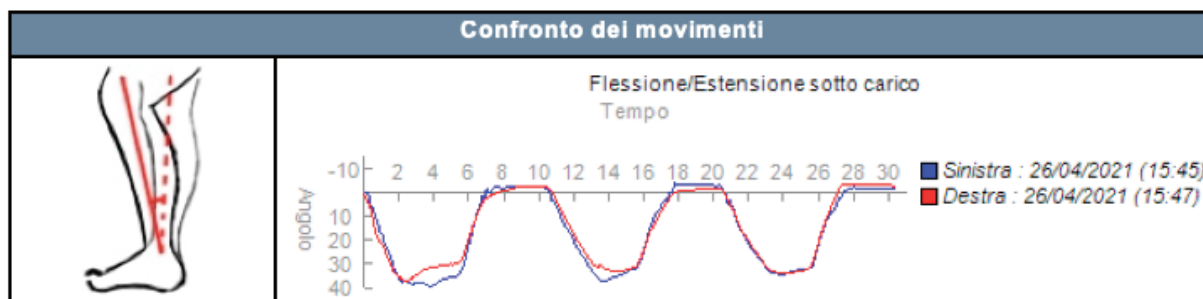


Figure 2. Angles acquired with Bioval system shows comparable results between both legs in single leg squatting. From the graph treated knee results to be more stable than the untreated knee.

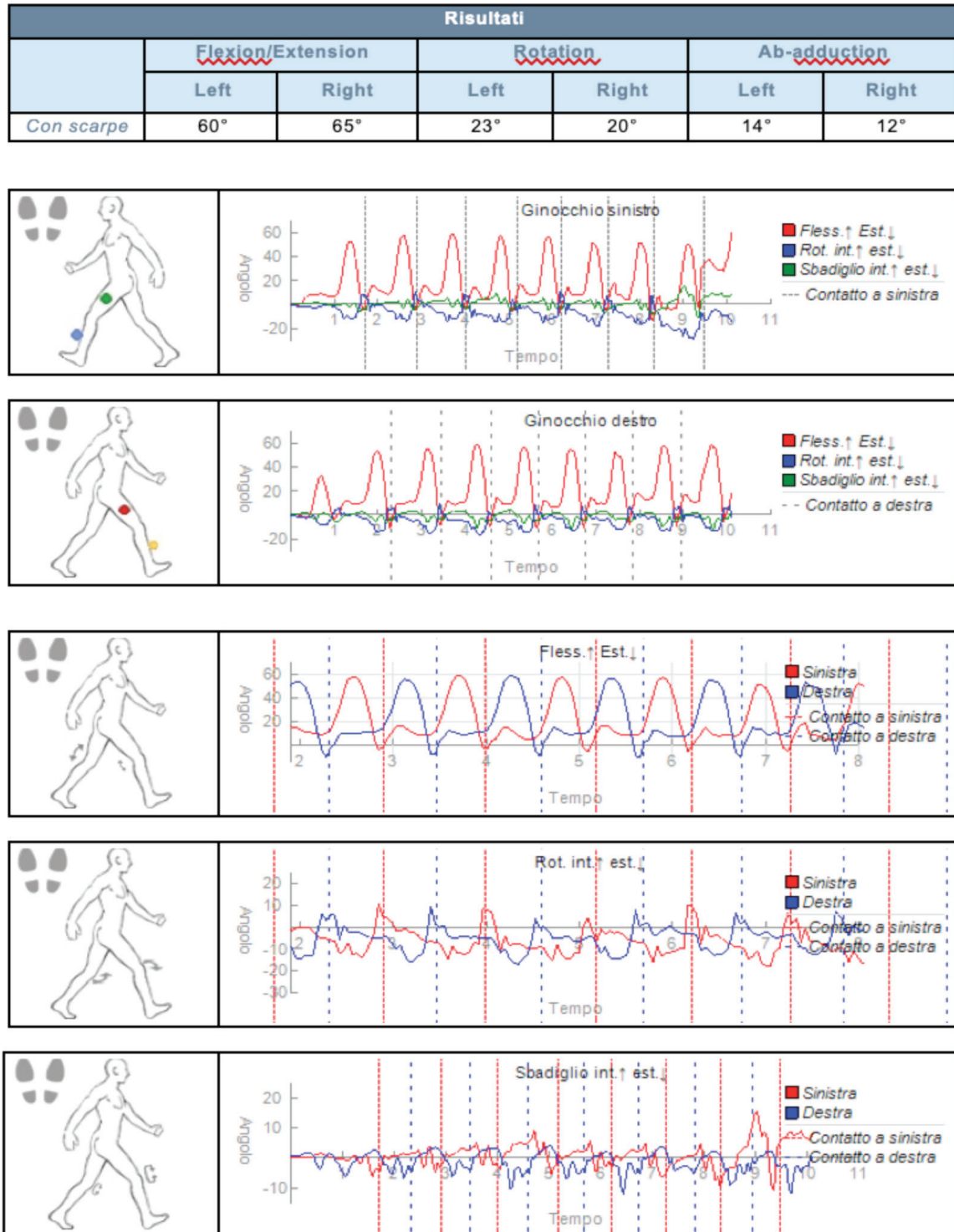
Walking: knee sensors

Figure 3. Data acquired during walking using MotionPods. Treated knee has reacquired the same stability as the untreated knee, is possible to underline the absence of residual instability after ACL reconstruction and LTE tenodesis.

of overconstraining the knee. Anderson et al (26) have performed a randomized prospective study evaluate multiple intra-articular reconstructions techniques with lateral extra-articular procedures: in his study have found no benefit to the addition of the extra-articular reconstruction with some complications like pain and overconstrain of lateral compartment, who can led to a risk of developing OA. Devitt et al (27), on the contrary, in a systematic review that included more than 400 patients, found no evidence that the addition of a LET to ACL reconstruction can resulted in an increased rate of OA of the knee.

The current literature suggests that the association of LET procedure to ACL reconstruction improves stability and reduces the risk of failure (28). What is the best lateral extra-articular procedure?

More than twelve lateral extra-articular techniques have been described in literature, most of which utilize a strip of the ITB with variable length that is passed under or over di FCL and fixed to different points at the lateral femoral condyle or at the Gerdy tibial tubercle. However, the literature does not show the superiority of one technique over the other. These procedures can restrict internal tibial rotation as in native state and also reduce forces applied to the ACL graft during anterior directed loading.

Most works in the literature analyze subjective data or operator dependent data. Furthermore, the works that use objective data are mostly in vitro.

Conclusions

Assuming that this is a pilot study, this short case series was able to provide us with important information: the LET in association with the reconstruction of the ACL guarantees an objective complete regained knee stability in patients. Clinical and instrumental evaluation showed how a combination of procedures can restore the kinematic and stability of a joint, even if the procedures performed are not anatomical. We will proceed along this path by collecting data from a greater number of patients and with greater follow-up with the aim of giving statistical significance to our data.

Conflict of interest: Each author declares that he or she has no commercial associations (e.g., consultancies, stock ownership, equity interest, patent/licensing arrangement etc.) that might pose a conflict of interest in connection with the submitted article.

References

1. Gottlob CA, Baker CL, Jr., Pellissier JM, Colvin L. Cost effectiveness of anterior cruciate ligament reconstruction in young adults. *Clin Orthop Relat Res* 1999;272-82.
2. Andernord D, Desai N, Bjornsson H, Ylander M, Karlsson J, Samuelsson K. Patient predictors of early revision surgery after anterior cruciate ligament reconstruction: a cohort study of 16,930 patients with 2-year follow-up. *Am J Sports Med* 2015;43:121-7.
3. Maletis GB, Granan LP, Inacio MC, Funahashi TT, Engbretsen L. Comparison of community-based ACL reconstruction registries in the U.S. and Norway. *J Bone Joint Surg Am* 2011;93 Suppl 3:31-6.
4. Di Benedetto P, Buttironi MM, Mancuso F, Beltrame A, Gisonni R, Causero A. Anterior cruciate ligament reconstruction: the role of lateral posterior tibial slope as a potential risk factor for failure. *Acta Biomed* 2020;91:e2020024.
5. Christensen JJ, Krych AJ, Engasser WM, Vanhees MK, Collins MS, Dahm DL. Lateral Tibial Posterior Slope Is Increased in Patients With Early Graft Failure After Anterior Cruciate Ligament Reconstruction. *Am J Sports Med* 2015;43:2510-4.
6. Woo SL, Kanamori A, Zeminski J, Yagi M, Papageorgiou C, Fu FH. The effectiveness of reconstruction of the anterior cruciate ligament with hamstrings and patellar tendon . A cadaveric study comparing anterior tibial and rotational loads. *J Bone Joint Surg Am* 2002;84:907-14.
7. Getgood A, Hewison C, Bryant D, et al. No Difference in Functional Outcomes When Lateral Extra-Articular Tenodesis Is Added to Anterior Cruciate Ligament Reconstruction in Young Active Patients: The Stability Study. *Arthroscopy* 2020;36:1690-701.
8. Slette EL, Mikula JD, Schon JM, et al. Biomechanical Results of Lateral Extra-articular Tenodesis Procedures of the Knee: A Systematic Review. *Arthroscopy* 2016;32:2592-611.
9. Claes S, Vereecke E, Maes M, Victor J, Verdonk P, Bellemans J. Anatomy of the anterolateral ligament of the knee. *J Anat* 2013;223:321-8.
10. Terry GC, Norwood LA, Hughston JC, Caldwell KM. How iliotibial tract injuries of the knee combine with acute anterior cruciate ligament tears to influence abnormal anterior tibial displacement. *Am J Sports Med* 1993;21:55-60.
11. Di Benedetto P, Di Benedetto E, Fiocchi A, Beltrame A, Causero A. Causes of Failure of Anterior Cruciate Ligament Reconstruction and Revision Surgical Strategies. *Knee Surg Relat Res* 2016;28:319-24.
12. Vundelinckx B, Herman B, Getgood A, Litchfield R. Surgical Indications and Technique for Anterior Cruciate Liga-

- ment Reconstruction Combined with Lateral Extra-articular Tenodesis or Anterolateral Ligament Reconstruction. *Clin Sports Med* 2017;36:135-53.
13. Benum P. Extracondylar transposition of the lateral third of the patellar ligament in anterolateral rotatory instability of the knee. Presented at the 43rd Meeting of the Scandinavian Orthopaedic Association, Trondheim, Norway. 1986.
 14. Di Benedetto P, Vidi D, Colombo A, Buttironi MM, Cainero V, Causero A. Pre-operative and post-operative kinematic analysis in total knee arthroplasty. A pilot study. *Acta Biomed* 2019;90:91-7.
 15. Engebretsen L, Lew WD, Lewis JL, Hunter RE. The effect of an iliotibial tenodesis on intraarticular graft forces and knee joint motion. *Am J Sports Med* 1990;18:169-76.
 16. Andrews JR, Sanders R. A "mini-reconstruction" technique in treating anterolateral rotatory instability (ALRI). *Clin Orthop Relat Res* 1983;93-6.
 17. Arnold JA, Coker TP, Heaton LM, Park JP, Harris WD. Natural history of anterior cruciate tears. *Am J Sports Med* 1979;7:305-13.
 18. Jenny JY, Puliero B, Schockmel G, Harnois S, Clavert P. Experimental validation of the GNRB((R)) for measuring anterior tibial translation. *Orthop Traumatol Surg Res* 2017;103:363-6.
 19. Andrews JR, Sanders RA, Morin B. Surgical treatment of anterolateral rotatory instability. A follow-up study. *Am J Sports Med* 1985;13:112-9.
 20. Dejour H, Walch G, Neyret P, Adeleine P. [Results of surgically treated chronic anterior laxities. Apropos of 251 cases reviewed with a minimum follow-up of 3 years]. *Rev Chir Orthop Reparatrice Appar Mot* 1988;74:622-36.
 21. Lemaire M. Ruptures anciennes du ligament croise anterieur. Frequence-clinique traitement. *J Chir* 1967;93:311-320.
 22. Rackemann S, Robinson A, Dandy DJ. Reconstruction of the anterior cruciate ligament with an intra-articular patellar tendon graft and an extra-articular tenodesis. Results after six years. *J Bone Joint Surg Br* 1991;73:368-73.
 23. MacIntosh DL DT. Lateral substitution reconstruction. *J Bone Joint Surg Br* 1986;58B:142.
 24. Bertioia JT, Urovitz EP, Richards RR, Gross AE. Anterior cruciate reconstruction using the MacIntosh lateral-substitution over-the-top repair. *J Bone Joint Surg Am* 1985;67:1183-8.
 25. Zarins B, Rowe CR. Combined anterior cruciate-ligament reconstruction using semitendinosus tendon and iliotibial tract. *J Bone Joint Surg Am* 1986;68:160-77.
 26. Anderson AF, Snyder RB, Lipscomb AB, Jr. Anterior cruciate ligament reconstruction. A prospective randomized study of three surgical methods. *Am J Sports Med* 2001;29:272-9.
 27. Devitt BM, Bouguennec N, Barfod KW, Porter T, Webster KE, Feller JA. Combined anterior cruciate ligament reconstruction and lateral extra-articular tenodesis does not result in an increased rate of osteoarthritis: a systematic review and best evidence synthesis. *Knee Surg Sports Traumatol Arthrosc* 2017;25:1149-60.
 28. Amis AA, Scammell BE. Biomechanics of intra-articular and extra-articular reconstruction of the anterior cruciate ligament. *J Bone Joint Surg Br* 1993;75:812-7.
-
- Received: 12 May 2021
Accepted: 30 May 2021
Correspondence:
Paolo Di Benedetto,
Clinica OrtopedicaAzienda Sanitaria - Universitaria Integrata di Udine
P.le S.Maria della Misericordia, 15 - 33100
Udine (Italy)
Tel. +39 0432 559464 Fax +39 0432 559298
E-mail: paolo.dibenedetto@asufc.sanita.fvg.it