

Bucket-handle meniscal tears in children under the age of 10: a literature review

Gianluca Canton, Guido Maritan, Francesco Impellizzeri, Cristina Formentin, Luigi Murena
Orthopaedics and Traumatology Unit, Cattinara Hospital – ASUGI, Trieste (Italy)

Abstract. *Background and aim of the work:* Traumatic meniscal tears are raising in skeletally immature patients due to increasing participation in sport activities. Nonetheless, meniscal tears remain a rare injury in children, with a lack of evidence regarding treatment and outcome. The aim of the study is to review the literature on BHMT in children aged under 10 years. *Methods:* Two independent reviewers conducted a systematic search of Embase, Medline and Pubmed databases to report a summary of literature evidence about epidemiology, clinical presentation, diagnosis, treatment and outcome of BHMTs in children under the age of 10. *Result:* Eight papers have been considered, including seven case reports and one case series, for a total amount of 21 cases of BHMTs in children under 10 years. Complete clinical information was retrieved for 12 cases, which were analyzed in detail. The injury occurred in the medial meniscus in 8 cases (66,7%), while in 4 cases (33,3%) on a lateral discoid meniscus. The mean reported age is 4,6 years (range 2 years - 9 years), with prevalence of the female sex (62,5%). *Conclusion:* BHMT is an uncommon lesion in children under 10 years old. It can be suspected after a history of knee trauma in patients with knee pain, effusion and locking. MRI is the best technique for the diagnosis. Current strategy of treatment is to preserve the meniscus through different arthroscopic suture techniques, unless the lesion occurs on a discoid meniscus. (www.actabiomedica.it)

Keywords: Knee, Bucket-handle meniscal tears, Children, Treatment

Background and aim of the work

Traumatic meniscal tears are raising in the pediatric population due to increasing participation in sport activities and to improvement of diagnostic methods (1-5). Bucket Handle Meniscal Tears (BHMTs) are a peculiar type of meniscal lesion, occurring approximately in 9% to 49% of all meniscal tears according to different studies (6-8). BHMT is a vertical longitudinal meniscal tear that leads to fragment displacement toward the intercondylar notch region (Figure 1). Although this type of lesion is rare in children, it must be identified and when possible repaired to obtain good long-term outcome and to prevent early arthritis (9,10). Aim of the present paper is to review the literature about epidemiology, clinical presentation, diagnosis and treatment of BHMTs in children under the age of 10.

Methods

Two reviewers (MG and IF) independently identified studies by a systematic search of Embase, Medline and Pubmed from inception of the database to 31 December 2020, using various combinations of the terms “meniscal tears”, “meniscal lesions”, “bucket-handle”, “knee”, “pediatric”, “skeletally immature”, “children”. Aim of the present review is to report a summary of literature evidence about epidemiology, clinical presentation, diagnosis, treatment and outcome of BHMTs in children under the age of 10. The two reviewers screened the titles and abstracts of the citations identified independently and in duplicate, and acquired the full text of any article that either judged potentially eligible. Epidemiology, diagnostic features, clinical management and outcome were all reviewed. Disagreements were resolved by discussion.

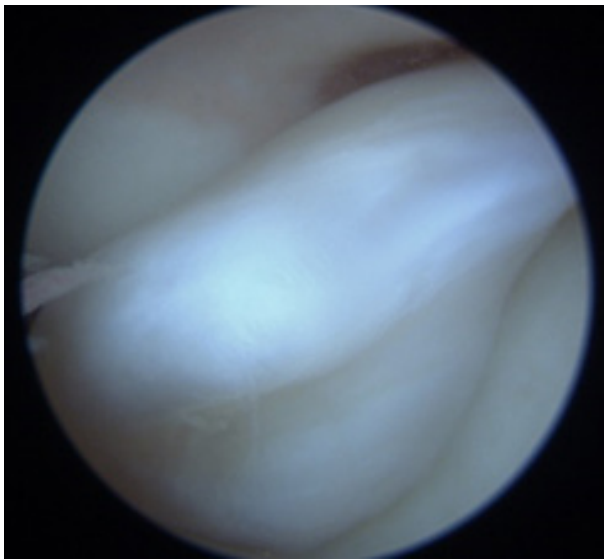


Figure 1: Eleven years old boy who sustained a minor knee trauma at the age of 9. Given the non-specific clinical signs and symptoms, diagnosis of BHMT occurring on a medial discoid meniscus occurred only two years after trauma. The clinical picture shows the typical arthroscopic aspect of meniscus fragment displacement in the intercondylar notch

Results

The authors found 21 cases of BMHT in children under 10 years in the present review, of which 8 described as case reports (Table 1) (8,11-16). In all cases there were no associated lesions reported. The remain-

ing 13 cases were retrieved in a large case-series of 280 BHMTs treated arthroscopically in patients aged 19 years or younger (17). Unfortunately, complete clinical information was reported only for the four youngest patients (aged 2 to 6 years). Hence, a detailed analysis of 12 cases of BHMT is reported in the following sections.

Discussion

Epidemiology

Meniscal lesions are considered to be the most common injuries in pediatric athletes together with ACL lesions (1,2). Although the rate of meniscus tears in pediatric population is reported to be increasing over time, the exact prevalence and incidence in children is still unknown. In the past these lesions were considered extremely rare, in particular under the age of 10 years, unless in cases of discoid meniscus (18). A Danish study showed an incidence of meniscus injury in patients up to 9 years old of 1 per 100,000 patients (19), while its incidence in US high school athletes have been reported to be 40.7 per 100,000 in males and 22.3 per 100,000 in females (20). As far as BHMTs are concerned, in pediatric and adolescent population their frequency among meniscus injury varies

Table 1. Summary of data reported in the case report papers considered in the review. Eight cases of BMHTs in children under 10 years are described

Reference	Age- sex	Meniscus	Time to treat	Mechanism of injury	Techniques	Results follow up
VOLK	5 M	Medial	NA	Twisting of the knee during physical activities	Total meniscectomy	Return to normal activities at 27 months with residual pain on kneeling
SADDAWI	4 F	Medial	NA	Direct trauma on the knee	Total meniscectomy	Return to normal activities
BLOOME	4 M	Medial	6 Weeks	Direct trauma on the knee	Arthroscopy suture	Return to normal activities at 17 months
BLOOME	4 F	Medial	1 year	Direct trauma on the knee	Arthroscopy suture	Return to normal activities at 12 months
YALCIN	6 F	Lateral	NA	Spontaneous rupture	Subtotal meniscectomy	Return to normal activities at 36 months
SHEA	5 M	Medial	NA	Twisting of the knee during physical activities	Arthroscopy suture	Return to normal activities at 12 months
NOOH	9 F	Medial	1 week	Twisting of the knee during physical activities	Arthroscopy suture	Return to normal activities at 7 months
FINK	2 F	Medial	Several weeks later	Direct trauma on the knee	Arthroscopy suture	Return to normal activities at 7 months

from 14% to 24% of cases (21, 22). Overall, medial meniscus is more often involved (88% of cases) (23).

In the present review, complete epidemiologic data were retrieved for 12 patients. The lesion occurred in the medial meniscus in 8 cases (66,7%), while in 4 cases (33,3%) the injury occurred on a lateral discoid meniscus. The mean reported age is 4,6 years (range 2 years - 9 years). Excluding the lesions described by Kramer in which the sex of the patients is not reported, there is a prevalence of female sex (62,5%).

Clinical presentation and diagnosis

As in the adult population, the main reported cause of BHMT in skeletally immature patients is a twisting injury of the knee occurring during physical activity. This trauma mechanism was responsible for 3 cases in the present review (8,11,12). A direct trauma was reported to be the cause in 5 cases (13,15-17), while in the case described by Bloome the young girl fell down while she was bouncing on trampoline, without further details on trauma mechanism (15). Just one case was reported to be nontraumatic in a 6 years old female children with history of spontaneous rupture on a discoid meniscus (14). For the three youngest patients in Kramer's series, trauma mechanism leading to discoid lateral meniscus rupture was not reported (17). Traumatic meniscal lesions may cause similar symptoms in children and adults, such as significant knee pain in acute injury, loss of knee function and swelling. In comparison with other meniscal tears, BHMT is more likely to cause knee pain, gait instability and especially mechanical symptoms such as locking. The latter occurs typically when the fragment is displaced in the intercondylar notch (10). However, symptoms in children are reported to be highly nonspecific, both for meniscal lesions in general and for BHMTs. Moreover, the lack of cooperation of the child can make assessment very difficult. Therefore, the parents could refer the child to the physician several days, weeks or even months after trauma.

Kramer et al. again did not describe each case, reporting just mechanical symptoms such as block to extension, difficulty with ambulation, and knee locking. For these reasons, these patients are not considered in the following description.

For the remainder, we found knee pain as the principal symptom, present in 100% of the cases. Another relevant clinical presentation is knee locking, which was reported in 5 out of 8 cases (62,5%) (8,11,14, 15). Effusion of the knee was reported in the children treated by Yalcin et al and Saddawi et al (25%) (13,14). Saddawi et al reported also limping (25%), which was also described by Fink in the youngest reported case of BHMT (13,16).

The time lapse between injury and diagnosis was different for every patient. In detail, Bloome et al reported the time lapse for the diagnosis to be 1 month for the 4 years-old boy, and 1 year for the 4-years-old girl (15). Nooh et al and Fink et al reported a time lapse of weeks (11,16), while the remaining authors did not record the period occurred between knee injury and diagnosis.

To avoid late diagnosis, it is fundamental to consider meniscal lesions in the differential diagnosis of a child presenting with knee pain and effusion, especially in case of twisting knee trauma and when mechanical symptoms are present.

After excluding fractures and dislocations with plain x-rays, clinical suspicion should guide the physician to undertake MRI to detect the intra-articular conditions which might cause knee pain and mechanical symptoms in children. Other than meniscal lesions, discoid meniscus even in the absence of a tear or instability, osteochondral fracture, ACL tears or loose body might be found (24,25). As in adults, MRI is the gold standard for the diagnosis of meniscal tears. However, some peculiarities in images interpretation must be taken into account. In skeletally immature patients, identification of a meniscus tear is not always simple as other sources of high signal intensity in the menisci might be present (26). Takeda et al. reported that in children the prevalence of high signal intensity within the menisci was not related to meniscal tears in a significantly higher proportion than in adults (27).

The most common sign of BHMT on MRI is displacement of meniscus fragment. As in adults, the "intercondylar notch sign" and the "Double PCL Sign" are described to be useful signs in BHMTs in children (28,29). The first consists in a simple dislocation of the main fragment in the intercondylar notch,

seen in the coronal MRI views. The second is due to the displacement of the fragment in the intercondylar region anterior to the PCL. This situation creates a false image that simulate a double PCL on sagittal MRI views (Figure 2), with a reported specificity of 100% for BHMT lesion (30). It is visible in medial meniscus tears, because in lateral meniscus lesions the presence of an intact ACL does not permit its dislocation. Conversely, the double ACL sign is typically correlated with a lateral BHMT. This sign is due to the medial migration of the fragment across the intercondylar notch, appearing as a curvilinear low parallel signal band behind the ACL on sagittal views. This sign has a value especially when occurs in patient without precedent knee surgery or previous injury of ACL (31). Other signs of BHMT, as the “double anterior flipped meniscus sign” and the “absent bow tie” sign have also been described (10,32).

In the present review, except for the oldest studies dating back to a period before the application of MRI, every injury that we considered was diagnosed through MRI. Both Nooh and Shea found the double PCL and the intercondylar notch sign in their cases, Bloome described a medial meniscus tear displaced into the notch in one of the two cases, while in the other cases details about MRI findings were not reported (8,11,15).

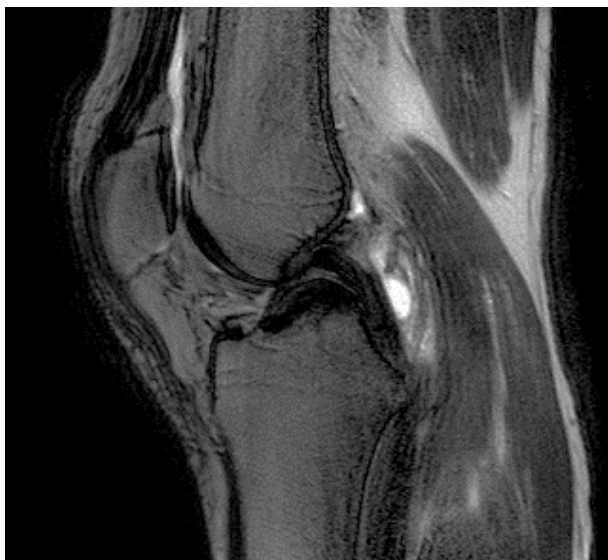

Figure 2: Same case of Figure 1, pre-operative MRI shows the “double PCL sign” (arrow shows PCL, arrowhead shows the meniscus tear)

Treatment and results

Given the lack of a specific treatment algorithm for pediatric BHMTs in the literature, management strategies are usually derived from the adult setting (33). Nowadays, the aim of BHMTs treatment is to preserve the meniscus whenever possible. It is well known how partial meniscectomy could accelerate the incidence of osteoarthritis. Although this could be accepted in more advanced age groups, it cannot be tolerated in children. Meniscectomy, even if partial, may have disastrous consequences in younger patients. Their basic activity level and daily ambulatory function can be adversely affected (34). Although partial meniscectomy must be taken into consideration in case of irreparable tears and in case of lesions occurring on discoid meniscus (24), arthroscopic meniscal repair should be the goal to obtain a favorable prognosis and functional outcome (11). This treatment strategy is all the more reason justified in children, given the vascularity and high healing potential of the meniscus in this age group. As reported by Krich et al, clinical success rate of BHMT repair is similar to simple tears in adolescent patients (6). Meniscal repair can be carried out with all-inside, inside-out or outside-in techniques with sutures. Given the lack of dedicated devices for pediatric meniscal suture, literature reports describe the use of the same techniques used in adults (35). In literature, there are no studies available that compare the results of these techniques on children. In the present review, treatment modality was reported in all 21 cases, although surgical technique details are not always reported. Analyzing the 19 patients younger than 10 years old treated in recent years, 14 were treated with arthroscopic meniscal repair. Regarding the technical aspects, different techniques have been used for arthroscopic repair, with good functional outcome at different follow-ups (8-15). In detail, Shea et al placed four vertical mattress sutures to restore the meniscus integrity using an inside-out suture repair technique and an additional vertical mattress suture using an all-inside technique (8). In the injury described by Nooh et al arthroscopy was performed one week after injury, but the exact suture technique is not reported. Both patients resumed their normal activities at 12 and 7 months follow up respectively (11). In the two cases described by Bloome, two different surgeons

opted for different techniques. Outside-in technique was used for a small knee of a 4-year-old patient treated 6 weeks after injury. In the second case, a combination of all-inside and inside-out sutures was used in another medial meniscus tear occurred in a child of 4-year-old treated 1 year after knee injury. The all-inside technique was chosen for the extreme posterior portion of the meniscus, while the inside-out technique was used to repair the more medial posterior horn portion and the midbody section. Both cases showed good functional outcomes, each patient resumed his normal activities at follow up of respectively 17 month and 1 year (15). Fink described the youngest case of BHMT, occurring on the medial meniscus in a 2 years old girl. In this case, two vertical mattress sutures were placed with all-inside technique several weeks after injury. After 8 weeks the patient recovered a full range of motion of the knee and at 6 months of follow-up she resumed her normal activities (16).

In the two oldest cases referring to the pre-arthroscopic era, open medial meniscectomy was carried out. Volk et al and Saddawi et al reported good functional outcomes with this technique at short term follow up, with minimal residual pain on kneeling in the child with the injury described by Volk. (12,13).

The remaining 5 cases underwent arthroscopic meniscectomy, four of which lack details about age, side and type of lesion. Yalcin et al. performed an arthroscopic subtotal meniscectomy of a lateral BHMT occurring on a discoid lateral meniscus in a 6-year-old girl, reporting full range of motion without any symptoms at three years (14).

Conclusions

BHMT is an uncommon lesion in skeletally immature patients and becomes rare in children under 10 years old, with only 21 cases reported in the literature. BHMTs must be suspected also in this age group when pain, effusion and mechanical symptoms are present, especially after a twisting injury during physical activity. Meniscal arthroscopic repair seems to be the technique of choice unless the lesion occurs on a discoid meniscus.

Conflict of Interest: Each author declares that he or she has no commercial associations (e.g. consultancies, stock ownership, equity interest, patent/licensing arrangement etc.) that might pose a conflict of interest in connection with the submitted article

References

1. McConkey MO, Bonasia DE, Amendola A. Pediatric anterior cruciate ligament reconstruction. *Curr Rev Musculoskelet Med* 2011;4(2):37-44
2. Stanitski CL, Harvell JC, Fu F. Observations on acute knee hemarthrosis in children and adolescents. *J Pediatr Orthop.* 1993;13(4):506-10.
3. Bellisari G, Samora W, Klingele K. Meniscus tears in children. *Sports Med Arthrosc Rev.* 2011;19(1):50-5.
4. Carter CW, Kocher MS. Meniscus repair in children. *Clin Sports Med.* 2012;31(1):135-54.
5. Ferrari MB, Murphy CP, Gomes JLE. Meniscus repair in children and adolescents: a systematic review of treatment approaches, meniscal healing, and outcomes. *J Knee Surg.* 2018.
6. Krych AJ, McIntosh AL, Voll AE, Stuart MJ, Dahm DL. Arthroscopic repair of isolated meniscal tears in patients 18 years and younger. *Am J Sports Med.* 2008;36(7):1283-9.
7. Lucas G, Accadbled F, Violas P, et al. Isolated meniscal injuries in paediatric patients: outcomes after arthroscopic repair. *Orthop Traumatol Surg Res.* 2015;101(2):173-7
8. Shea KG, Archibald-Seiffer N, Kim KM, Grimm NL. Bucket-handle meniscal tear in a 5-year-old child *KNEE SURG SPORT TR A.* 2012 ;20(11):2291-3
9. Kraus T, Heidari N, Švehlík M, Schneider F, et al. Outcome of repaired unstable meniscal tears in children and adolescents. *Acta Orthop* 2012; 83:261-266
10. Helms CA, Laorr A, Cannon WD Jr. The absent bow tie sign in bucket-handle tears of the menisci in the knee. *Am J Roentgenol* 1998; 170:57-61
11. Anas Nooh 1, Feras Waly, Fahad H Abduljabbar, Chantal Janelle; Bucket-handle meniscal tear in a 9-year-old girl: a case report and review of the literature 2015; *J. Pediatr Orthop B,* 2016
12. VOLK H, SMITH FM. Bucket-handle tear of the medial meniscus in a five-year old boy. *J Bone Joint Surg Am.* 1953 ;35-A(1):234-6
13. Saddawi ND, Hoffman BK. Tear of the attachment of a normal medial meniscus of the knee in a four-year-old-child. A case report. *J Bone Joint Surg Am.* 1970;52(4):809-11
14. Yalçın N, Bektaşer B, Çiçekli O, Doğan M. Alti ya indaki kız hastada diskoid lateral menisküsün kova sapi yirtisi [Bucket-handle tear of a discoid lateral meniscus in a 6-year-old girl]. *Acta Orthop Traumatol Turc.* 2009;43(6):528-31
15. Bloome DM, Blevins FT, Paletta GA Jr, et al. Meniscal repair in very young children. *Arthroscopy.* 2000;16(5):545-9
16. Fink K, Kaushal N, Gross J, Patel H, Delbello D. Bucket-Handle Tear of the Medial Meniscus in a 2-Year-Old Child. *Orthopedics.* 2018 Jul 1;41(4):e580-e582

17. Kramer DE, Kalish LA, Martin DJ, Yen YM, Kocher MS, Micheli LJ, Heyworth BE. Outcomes After the Operative Treatment of Bucket-Handle Meniscal Tears in Children and Adolescents. *Orthop J Sports Med.* 2019 Jan 15;7(1):2325967118820305.
18. Andrish JT. Meniscal Injuries in Children and Adolescents: Diagnosis and Management. *J Am Acad Orthop Surg.* 1996 Oct;4(5):231-237.
19. Hede A, Jensen DB, Blyme P, Sonne-Holm S. Epidemiology of meniscal lesions in the knee. 1,215 open operations in Copenhagen 1982-84. *Acta Orthop Scand.* 1990 Oct;61(5):435-7.
20. Mitchell J, Graham W, Best TM, Collins C, Currie DW, Comstock RD, Flanigan DC. Epidemiology of meniscal injuries in US high school athletes between 2007 and 2013. *Knee Surg Sports Traumatol Arthrosc.* 2016 Mar;24(3):715-22.
21. Shieh A, Bastrom T, Roocroft J, Edmonds EW, Pennock AT. Meniscus tear patterns in relation to skeletal immaturity: children versus adolescents. *Am J Sports Med.* 2013 Dec;41(12):2779-83.
22. Jackson T, Fabricant PD, Beck N, Storey E, Patel NM, Ganley TJ. Epidemiology, Injury Patterns, and Treatment of Meniscal Tears in Pediatric Patients: A 16-Year Experience of a Single Center. *Orthop J Sports Med.* 2019 Dec 20;7(12):2325967119890325.
23. Shakespeare DT, Rigby HS. The bucket-handle tear of the meniscus: a clinical and arthrographic study. *J Bone Joint Surg Br.* 1983;65: 383Y387
24. Kim JG, Han SW, Lee DH. Diagnosis and Treatment of Discoid Meniscus. *Knee Surg Relat Res.* 2016 Dec 1;28(4):255-262.
25. Goodman AD, Chase A, Owens BD. Locked Knee in a 15-Year-Old Girl: The Knee Examination. *J Pediatr.* 2017 Jun;185:245-245.e1.
26. Francavilla ML, Restrepo R, Zamora KW, Sarode V, Swirsky SM, Mintz D. Meniscal pathology in children: differences and similarities with the adult meniscus. *Pediatr Radiol.* 2014 Aug;44(8):910-25; quiz 907-9.
27. Takeda Y, Ikata T, Yoshida S, Takai H, Kashiwaguchi S. MRI high-signal intensity in the menisci of asymptomatic children. *J Bone Joint Surg Br.* 1998 May;80(3):463-7.
28. Magee TH, Hinson GW. MRI of meniscal bucket-handle tears. *Skeletal Radiol* 1998; 17:495-499.
29. Weiss KL, Morehouse HT, Levy IM. Sagittal MR images of the knee: a low signal band parallel to the posterior cruciate ligament caused by a displaced bucket handle tear. *AJR Am J Roentgenol* 1991; 156:117-119
30. Ververidis AN, Verettas DA, Kazakos KJ, et al. Meniscal bucket handle tears: a retrospective study of arthroscopy and the relation to MRI. *KNEE SURG SPORT TR A*, 2006; 14:343-349
31. Bui-Mansfield LT, DeWitt RM. Magnetic resonance imaging appearance of a double anterior cruciate ligament associated with a displaced tear of the lateral meniscus. *J Comput Assist Tomogr* 2006;30(2):327-332
32. Haramati N, Staron RB, Rubin S, Shreck EH, Feldman F, Kiernan H. The flipped meniscus sign. *Skeletal Radiol* 1993; 22:273-277
33. Brian W. Yang¹ & Elizabeth S. Liotta¹ & Nikolaos Paschos¹. Outcomes of Meniscus Repair in Children and Adolescents. *Curr. Rev. Musculoskelet. Med* 2019
34. Dennis E. Kramer, Leslie A. Kalish, Daniel J. Martin et al. Outcomes After the Operative Treatment of Bucket-Handle Meniscal Tears in Children and Adolescents; *Orthop J Sports Med.* 2019
35. Yang BW, Liotta ES, Paschos N. Outcomes of Meniscus Repair in Children and Adolescents. *Curr Rev Musculoskelet Med.* 2019 Jun;12(2):233-238.

Received: 5 May 2021 – Accepted: 8 June 2021

Correspondence:

Francesco Impellizzeri

Orthopaedics and Traumatology Unit, Cattinara Hospital – ASUGI, Strada di Fiume 447, 34149 Trieste (Italy).

Phone number: +39 0403994730.

Fax number: +39 0403994544

E-mail address: francesco_impellizzeri@gmail.com