

# One-stage procedure for open tibial fractures: feasible without orthoplastic surgery?

Carlotta Pari<sup>1</sup>, Filippo Raggini<sup>2</sup>, Stefania Paderni<sup>1</sup>, Giulia Bettinelli<sup>2</sup>, Vincenzo Salini<sup>2</sup>, Giovanni Vicenti<sup>3</sup>, Alberto Belluati<sup>1</sup>

<sup>1</sup>Orthopaedic and Trauma Department, Hospital Santa Maria delle Croci, Ravenna, Italy; <sup>2</sup> Orthopaedic and Trauma Department, University Vita-Salute San Raffaele, Milan, Italy; <sup>3</sup> Orthopaedic& Trauma Unit, Department of Basic Medical Sciences, Neuroscience and Sense Organs, School of Medicine, University of Bari -Aldo Moro- AOU Consorziale -Policlinico-, Bari, Italy

## Abstract.

**Background:** Open tibial fractures are mostly the result of high-energy traumas and often involve severe injuries with extensive bone and soft tissue loss, damage of muscles and neurovascular structures. Over recent years, the growth of Ortho-Plastic teams, as a well-coordinated bone, joint and soft tissue treatment, contributed to change the approach to these fractures and to achieve higher successful results in lower limb salvage. Unfortunately, many hospitals cannot benefit of a combined team in emergency, and the orthopedic surgeon is forced to manage personally these kinds of traumas. **Methods:** We retrospectively reviewed all the open tibial fractures treated at our Orthopaedic Department over the last 10 years, in order to assess the treatments performed (one-stage fixation with Intramedullary Nailing or Open Reduction Internal Fixation – ORIF, versus two/multiple-stage fixation with temporary External Fixation followed by nailing or ORIF) and the differences in the outcome between the different methods. **Purpose:** Based on our experience and review of the literature, the purpose of this paper is to define what cases can be managed by a single-stage orthopaedic approach, and when the orthopaedist should lay down his arms in favor of other specialties. ([www.actabiomedica.it](http://www.actabiomedica.it))

**Key words:** open tibial fractures, one-stage treatment, orthoplastic surgery

## Introduction

Open tibial fractures still represent a significant challenge for the orthopedic surgeon, as they are the 36.7% of all long-bone fractures in adults (1) and, in most cases, they involve severe injuries with extensive bone and soft tissue loss, damage of muscles and neurovascular structures (2). A careful preoperative clinical evaluation of the associated soft tissue damages is essential, due to the need of restoring the blood supply and guarantee an appropriate soft tissue coverage (3). Open tibial fractures are mostly the result of high-energy traumas and this may lead to a higher rate of postoperative complications such as malunion, nonun-

ion, infection or functional loss of the affected limb (1-2). Therefore, a proper therapeutic approach of all open fractures should include the mechanism of the injury, the appearance of the soft tissues, the likely levels of bacterial contamination and the specific pattern of the fracture (4-5). Several authors have highlighted a strong association between the grade of open tibial fractures, based on Gustilo-Anderson classification, and the risk to develop complications (6). Nowadays, it is well known that Grade I wounds are the easiest to be managed: they mainly occur as a result of a lower energy trauma with a minimal area of exposure and a consequent low bacterial contamination. The skin wound can be closed directly after having stabilized

the fracture, and the risk of postoperative perilesional swelling and necrosis is not frequent. Conversely, higher attention must be paid to open fractures with significant soft tissue damage, as occurring in high energy traumas which lead to Grade II and Grade III exposure wounds; the final outcome of these fractures remains unpredictable (7-11). Over recent years, the growth of Ortho-Plastic teams, as a well-coordinated bone, joint and soft tissue treatment, strongly contributed to change the approach to complex open tibial fractures and to achieve higher successful results in lower limb salvage (12). However, although orthoplastic teamwork is now recognized in many realities for being functional (13), “individual” work, with primary orthopedic intervention and secondary delayed soft tissue reconstruction, still remains the usual practice in many hospitals. This outlines important differences in terms of clinical results between the one and the two/multiple-stage approach where different specialties are involved (14-15). Indeed, the collaboration between orthopedic and plastic surgeons is not always easy, even when the two teams are available in the same center, due to the lack of communication and the absence of standard guidelines for the management of complex wounds (16).

Therefore, can a single-stage orthopedic approach still be considered feasible for treating open tibial fractures? What injuries should the orthopedic lay down his arms for, in favor of other specialties? The purpose of this paper is to report the experience of our Orthopaedic and Trauma Department, comparing the different treatments performed for Gustilo I-II-III open tibial fractures, according with a one-stage orthopedic approach or a two/multiple-stage ortho-plastic treatment.

## Patients and Methods

During a 10-year period from January 2009 to December 2019, 78 open tibial fractures were treated at our Orthopedic Department. We retrospectively reviewed all the cases in order to assess the treatments performed (one-stage fixation with Intramedullary Nailing or Open Reduction Internal Fixation – ORIF, versus two/multiple-stage fixation with temporary Ex-

ternal Fixation followed by nailing or ORIF) and the differences in the outcome between the two different methods. Patients who had less than 6-month x-ray follow-up were excluded, obtaining a 74-patient study population for a total amount of 75 fractures (one case was bilateral). The average age at the time of the surgery was 44 (range 16-82); 58 patients were male, 16 were female; 38 cases were right tibial fractures, 37 cases were left tibial fractures. Our Department protocol for the management of the open fractures includes a double wound irrigation with isotonic saline solution, the first performed at the arrival at the Emergency, the second performed in the operating room before starting the surgery. Antibiotics prophylaxis is administered to all patients following the scheme reported below:

- Cefazolin 2 g every 8 hours for 24 hours for the Gustilo I
- Cefazolin 2 g every 8 hours for 72 hours for the Gustilo II
- Cefazolin 2 g every 8 hours + Gentamicin 3-5 mg/Kg in single dose per day for 72 hours for the Gustilo IIIA/B/C (+ Metronidazole 500 mg every 6 hours in case of topsoil contamination)

It has been decided to separate patients affected by open tibial shaft fractures (Table 1) from the ones affected by open tibial plafond fractures (Table 2), due to the different involvement of the surrounding soft tissues, the management of which is typically more problematic for plafond fractures. 58 cases were shaft fractures, 17 cases were tibial plafond fractures.

The treatment options used for the shaft fractures consisted of:

- One-stage Intramedullary Nail fixation +/- Negative Pressure Wound Therapy (NPWT) based on the level of soft tissue involvement
- Two/multiple-stage approach with a temporary External Fixation, followed by nailing +/- postponed plastic surgery reconstruction based on the bone defect and the level of soft tissue damage

The treatment options used for the plafond fractures consisted of:

- One-stage ORIF (distal tibia plate fixation + peroneal plate fixation in case of associated peroneal fracture) +/- NPWT based on the level of soft tissue involvement

	Fracture Pattern (AO-OTA) Simple: type A1/A2 Complex: type A3/B/C	Surgical Procedure	Complications	x-ray fracture healing (average)
Gustilo I	Simple: 12	Nail	--	4 months
	Complex: 6	Nail	1 delayed union	(3 to 6)
Gustilo II	Simple: 2	Nail	--	4 months
	Complex: 22	Nail (12); Ex fix (10) > Nail within 15 days	1 infected nonunion (Ex fix)	(3 to 8)
Gustilo IIIA	Simple: --	--	--	5 months
	Complex: 11	Nail (4); Ex fix (7) > Nail within 15 days	1 delayed union (nail) 2 deep infection (Ex fix)	(4 to 8)
Gustilo IIIB	Simple: --	--	--	
	Complex: 1	Nail + dermo-epidermalgraft	Partialgraftnecrosis	6 months
Gustilo IIIC	Simple: --	--	--	10 months
	Complex: 4	Ex fix	Multiple surgeries (massive bone defect)	(5 mo to 2 y)

**Table 2.** Plafond fractures

	Fracture Pattern (AO-OTA) Simple: type A1/A2 Complex: type A3/B/C	Surgical Procedure	Complications	X-ray fracture healing (average)
Gustilo II	Simple: --	--	--	
	Complex: 6	ORIF (2); Ex fix (4) > ORIF 15 to 21 days	1 deep infection (Ex fix) 1 delayed union (Ex-fix)	6 to 8 months
Gustilo IIIA	Simple: --	--	--	
	Complex: 7	ORIF (2); Ex fix (5) > ORIF 20 to 30 days	1 deep infection (ORIF) 2 deep infection (Ex fix)	6 to 8 months
Gustilo IIIB	Simple: --	--	--	
	Complex: 1	Ex fix	Delayed union Plastic surgery needed	10 months
Gustilo IIIC	Simple: --	--	--	
	Complex: 3	Ex fix	Multiple surgeries 1 legamputation	8 months

- Two/multiple-stage approach with temporary External Fixation, followed by ORIF +/- postponed plastic surgery reconstruction based on the bone defect and the level of soft tissue damage

## Results

According to the Gustilo-Anderson classification (4), 18 cases were Gustilo type I fractures, 30 cases were Gustilo type II, 18 cases were Gustilo type IIIA, 2 case were Gustilo type IIIB, 7 cases were Gustilo

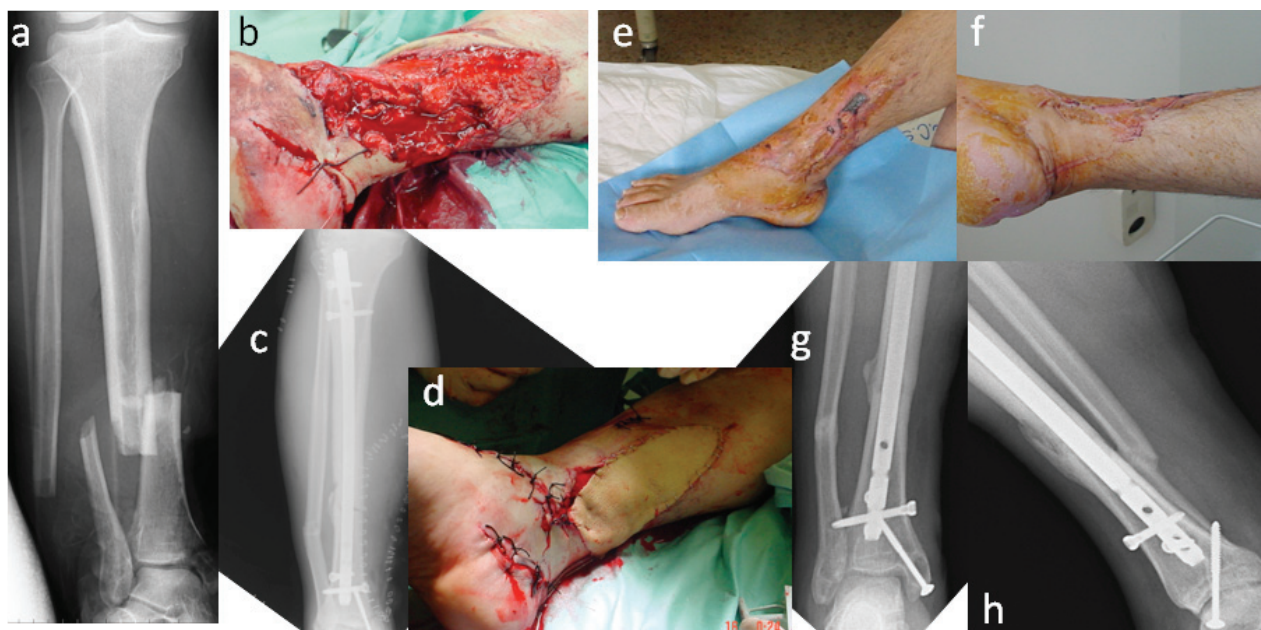type IIIC. As reported in Table 1, the Gustilo I tibial shaft fractures were all treated with one-stage Intra-medullary Nail fixation, regardless of their pattern, being it simple (type A1/A2 according to AO-OTA classification) or complex (type A3/B/C according to AO-OTA classification). The only complication occurred was a case of delayed union, which did not require a second surgery. We considered as 'delayed union' those fractures not healed yet after 4 months. Gustilo II fractures were mostly associated with a complex fracture pattern; one-stage treatment with intra-medullary nailing was performed in 14 cases, the re-

maintaining 10 fractures were firstly treated with external fixation and turned into nail fixation within 15 days, as soon as the wound at the exposure site healed. A single infected non-union, which required the implant removal, debridement and new osteosynthesis, occurred in a patient belonging to the two-stage group. Gustilo IIIA were all associated to a complex fracture pattern; 4 were treated one-stage; 7 were treated two-stage, performing the External Fixator/Nail switch within 15 days after the first surgery. No significant complications occurred in the one-stage group except from a delayed union; 2 deep infections, treated with antibiotics and NPWT, occurred in the two-stage group. Only one Gustilo IIIB was found and treated one-stage with nail and a dermo-epidermal skin graft to cover the medial soft tissue damage (fig.1).

The Gustilo IIIC (4 cases) were all associated to a complex fracture pattern with bone defect and required multiple surgeries to be solved. One was entirely treated using Ilizarov External Fixator, the remaining three were treated with Masquelet technique and secondary nailing. The overall percentage of complications observed within our population is 9,2% for open tibial shaft fractures, ranging from Gustilo I to Gustilo IIIA; the average x-ray fracture healing is 4 months, ranging

from a minimum of 3 to a maximum of 8 months, also for those cases which developed a deep infection.

A different scenario was found in the group of open tibial plafond fractures. As reported in Table 2, the plafond fractures were associated with a complex fracture pattern in all cases, regardless of the grade of bone exposure. However, no Gustilo I was found; this could be explained with the mechanisms of injury of these fractures, which frequently include a crushing trauma with severe soft tissue involvement. One-stage ORIF was performed in 4 patients for the treatment of 2 Gustilo II and 2 Gustilo IIIA plafond fractures. NPWT was needed in 2 cases to manage the skin necrosis occurred within one week after the surgery and was prolonged up to 5 weeks before obtaining the complete wound healing. The remaining 9 patients who reported a Gustilo II and IIIA fracture were firstly treated with External fixation. The switch from External Fixation to ORIF was performed within 21 days after the first surgery for the Gustilo II fractures, and from 20 to 30 days after the surgery for the Gustilo IIIA fractures. The x-ray complete fracture healing was 6 to 8 months, longer than what observed for shaft fractures (4 months). The overall percentage of complications was 41,6% and included: a delayed



**Figure 1.** Gustilo IIIB tibial shaft fracture treated one-stage with nail and a dermo-epidermal skin graft. a+b) pre-operative; c+d) post-operative; e+f) skin wound at the 3-month follow-up; g+h) 6-month follow-up x-ray



union occurred in the two-stage group and 4 deep infections (1 occurred in the one-stage group, 3 occurred in the two-stage group), 1 of which required the implant removal and ended in ankle arthrodesis. The only Gustilo IIIB fracture needed 10 months to heal and required a multiple-step approach, in combination to plastic surgery, to obtain a proper covering of the soft tissue damage. The 3 cases of Gustilo IIIC fractures also required multiple surgeries to be solved, 1 of which ended in the below-knee leg amputation.

## Discussion

Open fractures represent an orthopedic emergency due to the several complications they can lead to (1). The combination of bone and soft tissue damage could require a multidisciplinary approach (orthopaedic/plastic/vascular) for a proper management of these traumas. For this reason, the effectiveness of the first surgical procedure becomes crucial for final success (12). In previous literature, external fixation has always been considered the best method for primary and definitive stabilization of open tibial fractures, especially in cases of severe soft tissue damage and wound contamination. However, External Fixation could be affected by complications such as risk of malunion, malalignment and pin-track infection (17-19). According to the fracture site, different internal fixation devices have been developed over the years in order to perform an early definitive synthesis as an alternative to External Fixation. In the 1990s, intramedullary nails were established as a viable alternative to external fixation for the treatment of tibial shaft fractures (20-21). Some authors advised that intramedullary nailing was superior to external fixation with regard to fracture healing. Buzzi et al. (22) showed that nailing had a lower incidence of malalignment, earlier and more complete functional recovery and less need for further steps to achieve consolidation. In contrast, patients treated with external fixation experienced a fair incidence of pin-track infection. Similarly, Agrawal et al. (23) found, in a consecutive series of thirty patients with open tibial fractures, that unreamed intramedullary nailing resulted in a faster fracture healing, earlier rehabilitation and better biomechanical stability. Other orthopedics spread the theory that implanting a nail

in a fracture presented a risk of deep infection (24-26). Subsequently, data have shown that the risk of infection after intramedullary nailing correlates with soft tissue damage. The risk of infection is low in Gustilo I and II fractures, balances around 7% in grade IIIA fractures and over 15% in those IIIB (27-30). Thus, during time, intramedullary nailing has progressively replaced the External fixation for treating open tibial shaft fractures. The same increasing trend in the use of intramedullary nailing, can be noticed among our population over the last 10 years, obtaining satisfactory results in terms of fracture healing and low percentage of deep infections (31). Nevertheless, a different scenario is observed for the tibial pilon fractures. Although our population includes only 17 cases of pilon fractures, we have recorded a high percentage of complications (41,6%) regardless of the treatment used, one or two-stage. This is a consequence of the high energy of the trauma these fractures are usually caused by, of the complex fracture pattern with the frequent involvement of the articular surface, of the bone defect and extensive impairment of soft tissues (32). An additional aggravating factor is the characteristic low thickness of surrounding tissues at this anatomical site, which can lead to the development of tissue necrosis up to 72 hours after surgery. This can underestimate the actual damage on the soft tissue at the first evaluation, and make the wound healing more difficult, even when the skin coverage seems to be sufficient (33-34). In 2007, The AO foundation suggested a new classification system, taking care about both soft tissue and bone damage, which is extremely meticulous and useful in predicting the impending soft tissue involvement, but difficult to apply in the daily clinical practice (35). It has not been possible to go back to the AO classification system for our patients, due to the lack of images taken at the first patients' evaluation. As a result, the use of external fixation is well documented also for the treatment of close plafond fractures with articular involvement, in the effort to minimize soft tissue complications. Another advantage of External fixation is the opportunity to perform a computed tomography scan (CT scan) with the ankle joint in distraction. This allows the surgeon to accurately analyze the fracture pattern in order to obtain an effective preoperative planning before proceeding to ORIF. For these reasons, the external fixation in open pilon fractures remains the

preferred method as a first step treatment (36-37), also in our clinic. However, some authors such as Conroy et al. (38) promote a single-stage management consisting in the early open reduction and soft tissue coverage, with a vascularized muscle flap as the most suitable option. According to Gopal et al. (39-40), the “fix and flap” technique has shown that early wound closure and early fixation reduces infection rates and promotes fracture healing and early restoration of function. Thus, the ortho-plastic reconstruction is, today, gaining increasing popularity (41). Unfortunately, although the most recent studies showed that the Ortho-Plastic approach is more effective than the orthopedic one alone, many hospitals cannot benefit of a combined team in emergency yet. For this reason, the orthopedic surgeon is forced to manage personally these kinds of traumas, which often reach even peripheral hospitals. These injuries require a prompt irrigation-debridement, preferably

within 6 hours when bacterial contamination is still limited, and bacterial replication has not started (42). It has been proved that the infection rate raises in case of late soft tissue coverage, which should be ideally completed within 72 hours, and no longer than 7 days after the trauma (33,41).

Therefore, can the tissue coverage be acutely assessed without a plastic surgeon? What cases could safely be managed by a single-stage orthopaedic approach? What cases are suitable for a more cautious multiple approach, even if this entails a postponed plastic surgery intervention? Based on our experience and review of the literature, we realized an easily applicable guideline, specific for our Trauma Department Organization, and able to assist the orthopedic surgeon in the most appropriate treatment choice, in order to maximize the final outcome (fig.2).

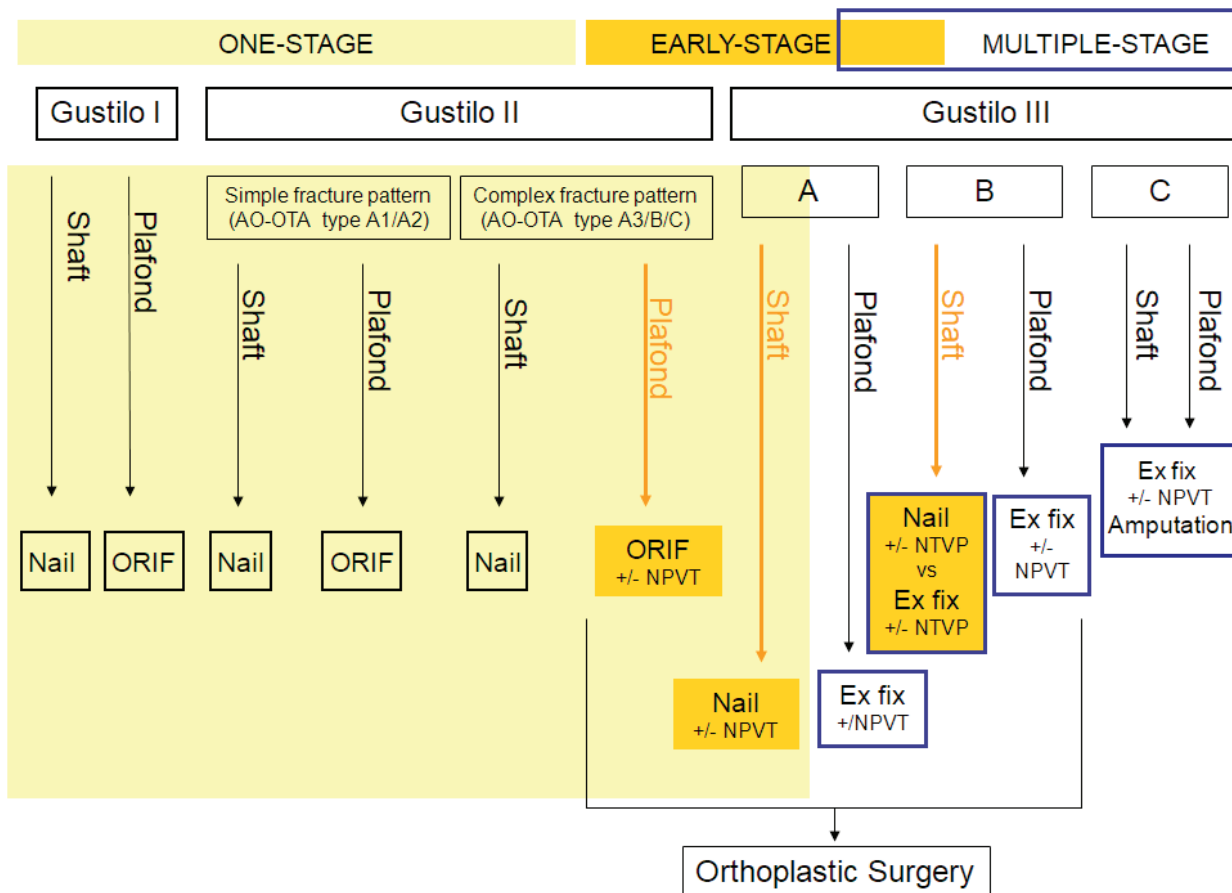


Figure 2. our scheme for guiding the orthopaedic surgeon's decision making

We defined as One-Stage the definitive fixation performed acutely at the patient arrival, where an orthoplastic combined approach is not required. The lack of plastic surgeons in emergency forced us to introduce the concept of Early-Stage treatment, which consist in the nail / ORIF fixation performed acutely at the patient arrival, associated to an early (within 48-72 ore) plastic surgeon intervention to obtain an adequate bone tissue coverage. This has been facilitated by NPWT support, that allows to maintain a clean and well vascularized wound floor waiting for the plastic surgeon intervention. We define as Multiple-Stage the temporary external fixation, followed by postponed nailing/ORIF and plastic surgery reconstruction.

## Conclusions

The literature increasingly promotes the one-stage approach also for high exposure grade tibial fractures. Indeed, it has been proved that an early combined bone and soft tissue treatment is more effective in reducing the infection risk, as well as the need of re-operation. However, the one-stage approach is not always feasible by the orthopedic surgeon alone. This is especially true for higher grades of bone exposure and for more complex articular plafond fractures, which are at a higher risk of developing secondary tissue necrosis. Therefore, it would be advisable, also in centers like ours, to create a trial including plastic surgery in the earliest post-fixation phases, in order to assess the actual damage on soft tissues, to time-effectively reduce the use of NPWT and the amount of re-operations.

**Conflict of Interest:** Each author declares that he or she has no commercial associations (e.g. consultancies, stock ownership, equity interest, patent/licensing arrangement etc.) that might pose a conflict of interest in connection with the submitted article .

## References

- Weiss RJ, Montgomery SM, Ehlin A, et al. Decreasing incidence of tibial shaft fractures between 1998 and 2004: information based on 10,627 Swedish inpatients. *ActaOrthop* 2008; 79:526–33.
- Court-Brown CM, Bugler KE, Clement ND, et al. The epidemiology of open fractures in adults. A 15-year review. *Injury*. 2012;43(6):891–7.
- Diwan A, Eberlin KR, Smith RM. The principles and practice of open fracture care, 2018. *Chin J Traumatol*. 2018;21(4):187–92.
- Paul, H Kim; Seth, S Leopold. “Gustilo–Anderson Classification”. *Clinical Orthopaedics and Related Research*. 470 (11): 3270–4.
- Gustilo R.B., Anderson J.T. Prevention of infection in the treatment of one thousand and twenty-five open fractures of long bones: retrospective and prospective analysis. *J Bone Joint Surg Am*. 1976;58-A:453–8.
- Papakostidis C, Kanakaris N, Pretel J et al. Prevalence of complications of open tibial shaft fractures stratified as per the Gustilo–Anderson classification. *Injury Int. J. Care Injured* 42 (2011) 1408–15.
- Gustilo RB, Mendoza RM, Williams DN. Problems in the management of type III (severe) open fractures: a new classification of type III open fractures. *J Trauma* 1984; 24:742–6.
- Cole JD, Ansel LJ, Schwartzberg R. A sequential protocol for management of severe open tibial fractures. *ClinOrthopRelat Res* 1995; 315:84–103.
- Russell GG, Henderson R, Arnett G. Primary or delayed closure for open tibial fractures. *J Bone Joint Surg Br* 1990; 72:125–8.
- Jenny JY, Jenny G, Kempf I. Infection after reamed intramedullary nailing of lower limb fractures. A review of 1,464 cases over 15 years. *ActaOrthopScand* 1994; 65:94–6.
- Kakar S, Tornetta P 3rd. Segmental tibia fractures: a prospective evaluation. *ClinOrthopRelat Res*. 2007; 460:196–201.
- Godina M. Early microsurgical reconstruction of complex trauma of the extremities. *PlastReconstrSurg* 1986; 78 (3): 285–92
- Boriani F, UlHaq A, Baldini T, et al. Orthoplastic surgical collaboration is required to optimize the treatment of severe limb injuries: A multi-centre, prospective cohort study. *J PlastReconstr Aesthetic Surg* 2017; 70: 715–22
- SommarP, Granberg Y, Halle M et al.. Effects of a formalized collaboration between plastic and orthopedic surgeons in severe extremity trauma patients; a retrospective study. *J Trauma Manag Outcomes* 2015; 9:3
- Toia F, Zabbia G, Scirpo R, et al. Microsurgery and external fixation in orthoplastic reconstruction of tibial injuries. *HandchirMikrochirPlastChir*. 2019;51(6):484–91.
- Lerman OZ, Kovach SJ, Levin LS. The respective roles of plastic and orthopedic surgery in limb salvage. *PlastReconstrSurg* 2011; 127: 215–27
- Belluati A, Pari C, Busatto C, et al. Intercalary allograft reconstruction in a patient with large tibial defect: Case report. *Injury, Int. J. Care Injured* 49S4 (2018) S39–42
- Behrens F, Searls K. External fixation of the tibia. Basic concepts and prospective evaluation. *J Bone JtSurg Br*. 1986; 68:246–54.
- Court-Brown CM, Wheelwright EF, Christie J, et al. External fixation for type III open tibial fractures. *J Bone Jt-*

- Surg Br. 1990; 72:801–4.
20. Krettek C, Haas N, Schandelmaier P, et al. Unreamed tibial nail in tibial shaft fractures with severe soft tissue damage. Initial clinical experiences. *Unfallchirurg*. 1991;94:579–87.
  21. Stegemann P, Lorio M, Soriano R, et al. Management protocol for unreamed interlocking tibial nails for open tibial fractures. *J Orthop Trauma*. 1995; 9:117–20.
  22. Buzzi R, Bertini FA, Cerulli Mariani P, et al. Treatment of open tibial fractures with locked intramedullary nailing. *GIOT* 2005; 31:224–9
  23. Agrawal A, Chauhan VD, Maheshwari RK, et al. Primary nailing in the open fractures of the Tibia-Is it worth? *J Clin-Diagn Res*. 2013; 7:1125–30.
  24. Blachut PA, Meek RN, O'Brien PJ. External fixation and delayed intramedullary nailing of open fractures of the tibial shaft. *J Bone J Surg* 1990; 72:729–75
  25. Court-Brown CM, Keating JF, McQueen MM. Infection after intramedullary nailing of the tibia. Incidence and protocol for management. *J Bone Joint Surg Br*. 1992;74(5):770–4.
  26. Vicenti G, Bizzoca D, Cotugno D, et al. The use of a gentamicin-coated titanium nail, combined with RIA system, in the management of non-unions of open tibial fractures: A single centre prospective study. *Injury*. 2019 Sep20;S0020-1383(19)30542-X.
  27. Henley MB, Chapman JR, Agel J, Harvey EJ, et al. Treatment of type II, IIIA, and IIIB open fractures of the tibial shaft: a prospective comparison of unreamed interlocking intramedullary nails and half-pin external fixators. *J Orthop Trauma* 1998; 12:1–7
  28. Whittle AP, Russell TA, Taylor JC, et al. Treatment of open fractures of the tibial shaft with the use of interlocking nailing without reaming. *J Bone Joint Surg Am* 1992; 74:1162–71.
  29. Keating JF, O'Brien PJ, Blachut PA, et al. Locking intramedullary nailing of open fractures of the tibia. A prospective randomised comparison of reamed and unreamed nails. *J Bone Joint Surg* 1997; 79:334–41.
  30. Sanders R, Jersinovich I, Anglen J, et al. The treatment of open tibial shaft fractures using interlocked intramedullary nail without reaming. *J Orthop Trauma* 1994; 8:504–10.
  31. Alho A, Ekeland, Stromsoe K, Folleras G, Thoresen BO. Locked intramedullary nailing for displaced tibial shaft fractures. *J Bone J Surg* 1990; 72:808–9
  32. Scolaro J, Ahn J. Pilon fractures. *ClinOrthopRelat Res*. 2011;469(2):621–3.
  33. Mathews JA, Ward J, Chapman TW, et al. Single-stage orthoplastic reconstruction of Gustilo–Anderson Grade III open tibial fractures greatly reduces infection rates. *Injury*. 2015;46(11):2263–6.
  34. Vicenti G, Pesce V, Tartaglia N, et al. Micromotion in the fracture healing of closed distal metaphyseal tibial fractures: a multicentre prospective study. *Injury*. 2014 Dec;45 Suppl6:S27–35
  35. Sommer C, Baumgaertner MR. Tibia, distal intraarticular (pilon). Ruedi TP, Buckley RE, Moran CG (eds). *AO Principles of Fracture Management*. 2nd ed. Stuttgart New York: Georg Thieme Verlag; 2007: 855–70
  36. Silluzio N, De Santis V, Marzetti E, et al. Clinical and radiographic outcomes in patients operated for complex open tibial/pilon fractures. *Injury*. 2019;50 Suppl 2: S24–28.
  37. Liporace FA, Yoon RS. Decisions and staging leading to definitive open management of pilon fractures: where have we come from and where are we now? *J Orthop Trauma*. 2012;26(8):488–98.
  38. Conroy J, Agarwal M, Giannoudis PV, et al. Early internal fixation and soft tissue cover of severe open tibial/pilon fractures. *IntOrthop*. 2003;27(6):343–7.
  39. Gopal S, Majumder S, Batchelor AG, et al. Fix and flap: the radical orthopaedic and plastic treatment of severe open fractures of the tibia. *J Bone Jt Surg Br*. 2000; 82:959–66.
  40. Maruccia M, Elia R, Caizzi G, et al. Free flap and kickstand external fixator in foot and ankle soft tissue reconstruction. The versatility of a microsurgical-friendly application of an orthopedic device. *Injury* 2018;49:S105–9.
  41. BOA/BAPRAS Standards for the management of open fractures of the lower limb. In Internet: <http://www.bapras.org.uk/professionals/clinical-guidance/open-fractures-of-the-lower-limb>; last date of access: October 7th, 2019
  42. Hendrickson SA, Wall RA, Manley O, et al. Time to Initial Debridement and wound Excision (TIDE) in severe open tibial fractures and related clinical outcome: A multi-centre study. *Injury*. 2018;49(10):1922–6.

Received: 4 May 2021

Accepted: 19 May 2021

Correspondence:

Carlotta Pari

Orthopaedic and Trauma Department, Hospital Santa Maria delle Croci, Ravenna, Italy

E-mail: [carlotta.pari@alice.it](mailto:carlotta.pari@alice.it)