

# Factors influencing results and complications in proximal periprosthetic femoral fractures: a retrospective study at 1- to 8-year follow-up

Chiara Concina, Marina Crucil, Franco Gherlinzoni

Department of Orthopaedics and Traumatology, San Polo Hospital, Monfalcone (Italy)

**Abstract.** *Background and aim:* Proximal periprosthetic femoral fractures (PPFFs) are gradually increasing and surgical management is often associated to high risk of complications, due to elderly population and associated comorbidities. We retrospectively assessed 79 patients at 1- to 8-years follow-up, focusing on factors that may have affected results and complications. *Methods:* Seventy-nine PPFFs were classified according to Vancouver classification in: 4 type B1, 22 type B2, 29 type B3, 24 type C. The average age of the patients was 81.5 year-old (61-95). 37 PPFFs (12 type B2 and 25 type B3) were treated with uncemented tapered fluted revision stems (Link MP Reconstruction Stem, Waldemar Link GmbH) and 42 patients with open reduction and internal fixation (ORIF). Patients were clinically and radiographically assessed at a mean 5-year follow-up (1-8 years). Elixhauser Comorbidity index was analysed. *Results:* All PPFFs, except two, healed within 10 months. Harris Hip score at follow-up was 65.6 in ORIF group and 79.8 in revision hip group ( $p < 0.05$ ). 35.7% and 32.4% had blood transfusions in ORIF and revision hip group respectively ( $p > 0.05$ ). 5 patients in ORIF group and 2 patients in revision hip group died within 12 months from surgery ( $p < 0.05$ ). *Conclusions:* Both ORIF and hip revision arthroplasty with modular uncemented tapered fluted stems are valid procedures for Vancouver B2 and B3 PPFFs. Low bone quality, high number of comorbidities with elevated Elixhauser Comorbidity Index, low body mass index and ORIF are associated to high 12-month mortality. ([www.actabiomedica.it](http://www.actabiomedica.it))

**Key words:** periprosthetic fractures, femoral fixation, revision, hip arthroplasty

## Introduction

Proximal periprosthetic femoral fractures (PPFFs) are the second reason for hospital 30-days readmission in patients with total hip replacement (THR) after infections (1) and the third most common reason for reoperation after aseptic loosening and dislocation in patients who had THR (2). Because the demand of THR is estimated to grow by 174% by 2030, as reported by Kurtz et al. (3), it is possible that the incidence of PPFFs will increase as well. The risk of having a PPFF is about 1.7% after primary THR with a cumulative risk of 3.5% at 20 years (4) and their incidence is three times higher after revision arthroplasty than primary THR (5,6). Furthermore, most of the times, PPFFs occurred in elderly patients for low-energy trauma (7)

and aging people have higher risk of falls (8). So the increasing number of THR in the elderly may contribute to raise their incidence.

PPFFs can be classified according to the Vancouver system proposed by Duncan and Masri, based on fracture site, stability of the stem and femoral bone quality (9). Type A involves lesser or greater trochanter. B fractures involve the bone surrounding the femoral stem and are subclassified in B1 (stable stem), in B2 (unstable stem but good bone stock) and B3 (unstable stem and poor quality bone stock). Fractures distal to the tip of the stem are classified as type C. Surgical management of PPFFs can include both osteosynthesis and revision hip arthroplasty, depending on fracture characteristics.

Besides being technically demanding, PPFFs are also very expensive problems with a 90-days readmis-

sion rate that can reach 27.3% (10). In fact, their surgical treatments are usually high-cost with long hospital stay, need of medical support and blood transfusions (11). The perioperative complications and mortality are particularly high as well: these patients are generally fragile people with other systemic comorbidities and limited mobilization, that need long physiotherapy and, most of the times, failed to return to their pre-injury functional level, requiring previously unnecessary assistance, with further social costs (6). The average total cost for a PPF was estimated at US\$ 30,979 (12).

In the present study we retrospectively analysed at an average 5-years follow-up the series of PPFs admitted in our Department, focusing on the factors that may have influenced their outcomes.

## Material and methods

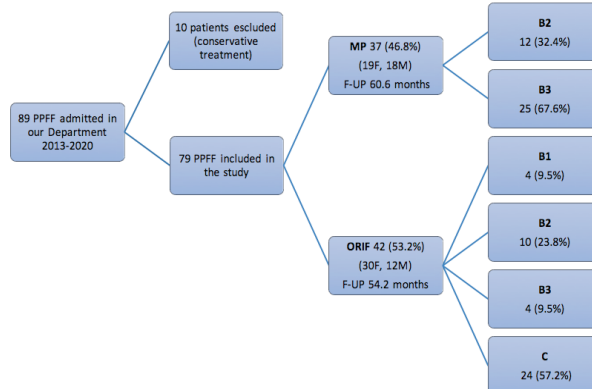
89 patients with PPFs were admitted in our Department from January 2013 to March 2020. 10 patients were treated conservatively, thus excluded from the present study. The remaining 79 consecutive patients were retrospectively analysed at an average 5-year follow-up (range 1-8). A proper informed consent form has been signed and the study was conducted in according with the Declaration of Helsinki.

The mean age of the patients was 81.5 years (range 61-95). 49 were female (62%) and 30 were male. The

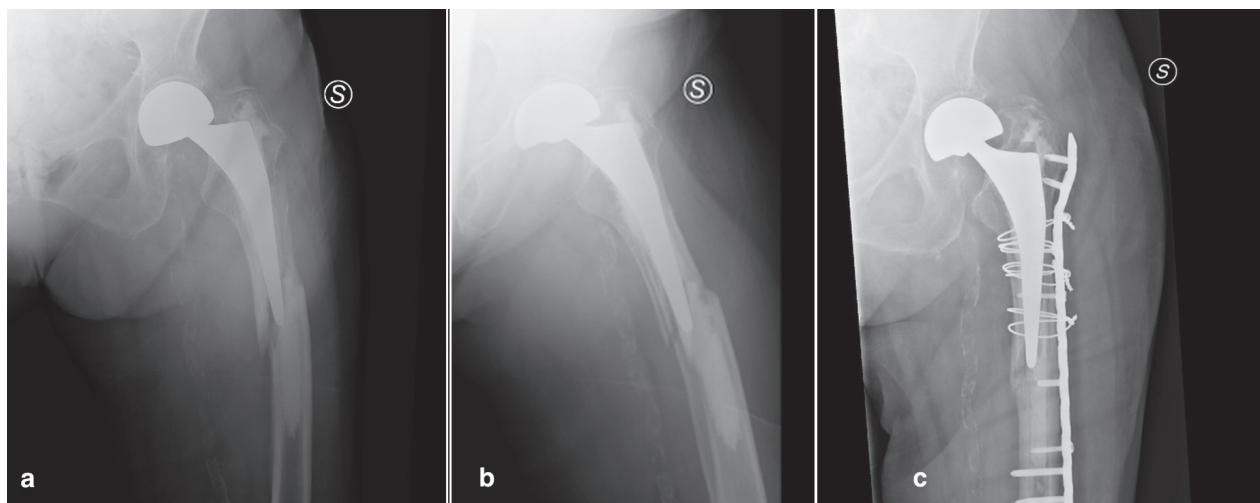
PPFFs were classified according to Vancouver classification (9): 4 cases were type B1, 22 were type B2, 29 were type B3 and 25 were type C (Graph. 1). PPFs occurred in 8 cemented primary THR (10.1%) and in 71 uncemented stem THR, and in 7 anatomical stems and in 72 straight stems.

41 patients (3 type B1, 10 type B2, 4 type B3, 24 type C) were treated with open reduction and internal fixation (ORIF) with LCP (Locking Compression Plate) and cables (Fig. 1) and one case classified as B1 with a greater trochanter plate (Cable-Ready plate, Zimmer, Inc, Warsaw, IN, USA) (Fig. 2).

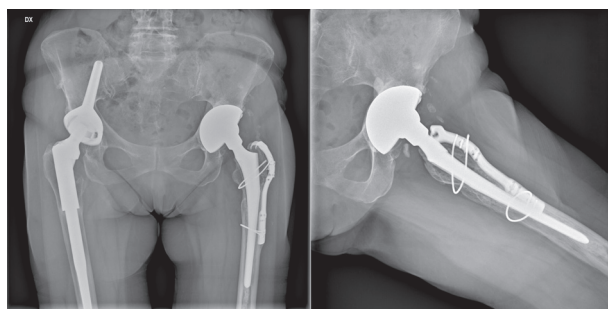
37 patients (12 type B2, 25 type B3) underwent to revision arthroplasty with a cementless Link MP Reconstruction stem (Waldermar Link GmbH, Hamburg, Germany) via direct lateral approach. It



**Graph.1** Patients' characteristics and fractures classification according to Vancouver system.



**Figure 1.** Type B3 fracture in a cemented stem in a 94 year-old woman (a,b). The fracture has been treated with a LCP plate, although the partial impairment of the cement mantle (c).



**Figure 2.** Seven-year radiographic control in a B1 fracture in a 85 year-old women treated with Cable-Ready plate.

is a tapered fluted titanium modular stem with distal fixation. The distal part of the implant has different diameters and lengths, with a 2-degree taper angle with longitudinal ribs that increases rotational stability, and a 3-degree bow, that follows the normal anterior bow of the femoral shaft. The proximal part has different neck-shaft angles and different offsets and allows increasing the leg length given to 1 cm modular blocks. Changing of the version is also permitted after distal segment implantation (Fig. 3).

The post-operative weight-bearing was restricted for 6 weeks in all patients who underwent to ORIF and was full in 30/37 (81.1%) patients who had hip revision arthroplasty.

The patients underwent to regular post-operative clinical and radiographic controls at one month, three months, 6 months and yearly. Medical records and radiographs were retrospectively analyzed considering the pre-operative and the last functional and radiographic control. On the radiographs were considered signs of implant loosening according to Gruen's zones (13), fracture healing, and hardware breakage.

Need of blood transfusion and complications occurred 12-months within index surgery were also recorded. Type of stem, femoral bone stock and quality were considered on the pre-operative radiographs. Functional abilities were assessed at follow-up using HHS score, focusing on the return to the pre-injury functional level. The number of comorbidities considered in the Elixhauser Comorbidities Index (14) were also recorded, dividing the patients in four groups based on this number: 0, 1-2, 3-4, 5+ comorbidities. The Elixhauser Comorbidities Index was also calcu-



**Figure 3.** Cementless Link MP Reconstruction stem (Waldemar Link GmbH, Hamburg, Germany).

lated using van Walraven algorithm (14).

A comparison between patients who had hip revision and ORIF was made too, analysing the aforementioned variables.

A two-tailed Student t-test was used for statistical analysis, considering the difference as statistically significant if the p-value was inferior to 0.05.

## Results

77 out of 79 (97.5%) PPF were healed within 10 months. One patient died a couple of weeks after surgery, because of cardiovascular complications, so it has been considered as lost at follow-up. The other patient, who was a B3 treated with ORIF, needed a further



revision at 14 months for non-union, using a double plating technique. Neither radiolucency lines nor subsidence were identified around the femoral stem; no hardware breakage occurred (Figs. 4-5).

The mean HHS was 79.8 (46-100) in the revision arthroplasty group and 65.6 (51-97) in the ORIF group. This difference was statistically significant ( $p < 0.05$ ). Particularly, 4 patients who had revision stem and 7 patients who had ORIF had very low functional ability (HHS  $< 70$ ) and were not able to walk at the follow-up. All the 7 patients who had ORIF, and one patient who had revision (he previously had a contralateral thigh amputation) had severe disability before the injury, so surgery did not affect their clinical conditions.

In the revision group 13 patients had no pain, 20 patients had mild pain, 4 patients had moderate pain; in the ORIF group 6 patients had no pain, 29 patients had mild pain, 7 patients had moderate pain.

As regards complications, 5 patients in ORIF group (11.9%) and 2 patients in revision hip group (5.4%) died within 12 months from surgery ( $p < 0.05$ ). One of the 5 patients died two weeks after ORIF for congestive heart failure. In the revision hip group we also had one myocardial infarction, three hip disloca-

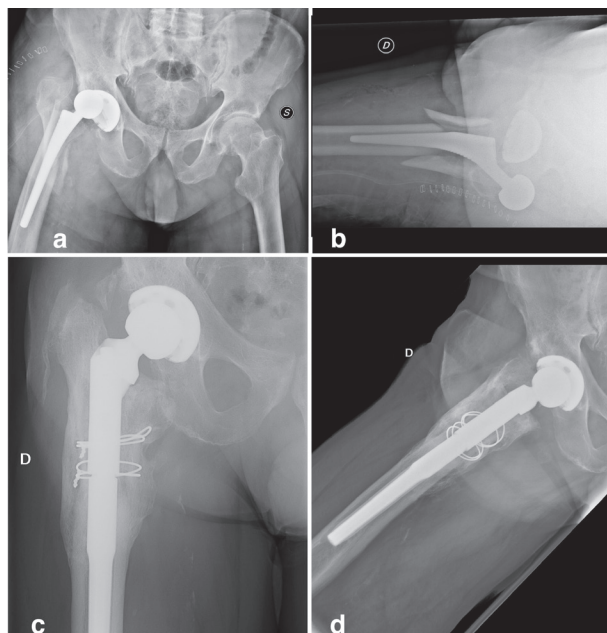
tions (one revised) and two early infections treated with surgical debridement. In the ORIF group we had one early infection treated with surgical debridement and one case of non-union (Tab. 1).

12 patients in the revision group (32.4%) and 15 patients in the ORIF group (35.7%) needed post-operative blood transfusions ( $p > 0.05$ ).

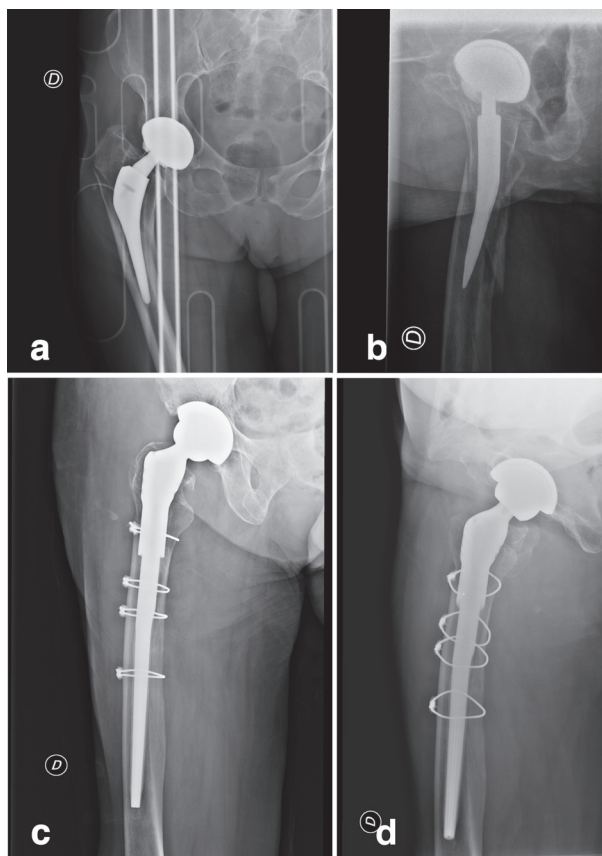
The Elixhauser Comorbidity Index was 19.9 in the ORIF group and 21.13 in the revision group ( $p < 0.05$ ). The allocation of the patients based on number of Elixhauser comorbidities is described in Graphic 2 with relative post-operative complications.

## Conclusions

PPFFs, although rare, are becoming more frequent, due to the increasing number of primary THR and to the ageing of the population. This kind of injury



**Figure 4.** A periprosthetic fracture-dislocation occurred 7 days after THR in a 78 year-old man (a,b). Radiographic control at 5-year follow-up treated with an uncemented tapered fluted stem showed fracture healing without stem subsidence (c,d).



**Figure 5.** A B2 fracture occurred in a 86 year-old woman with an anatomic stem (a,b). Radiographic control at 8 years showed fracture healing without stem subsidence or osteolysis.

**Tabella 1.** Results and complications in the ORIF group and in the revision arthroplasty group. \* identifies statistically significant results.

	ORIF group	Revision group	
Death	5 (11.9%)	2 (5.4%)	p<0.05*
Major complications	1 early infection 1 non union	2 early infections 3 dislocations 1 myocardial infarction	
Transfusions	15 (35.7%)	12 (32.4%)	p>0.05
HHS	65.6	79.8	p<0.05*
Pain:			
- no pain	6 (14.3%)	13 (35.1%)	p<0.05*
- mild	29 (69%)	20 (54.1%)	
- moderate	7 (16.7%)	4 (10.8%)	
Elixhauser Comorbidity Index	19.9	21.1	p>0.05
Return to pre-injury functional level	35 (83.3%)	29 (78.3%)	p>0.05

usually occurs for low energy trauma in elderly people with associated comorbidities (4,5). These fractures have poor clinical outcomes and, most of the times, the involved fragile patients do not return to their pre-injury functional level, with long in-bed period favouring other systemic complications, like lower respiratory tract infections, cardiovascular failure, bedsores or further limited mobilization (15,16). Female gender is 40% more likely to have a PPF (6). 62% of our series was female.

PPFFs are also described to be more common in uncemented stems. In a meta-analysis Bissias et al. described cemented implants as a protective factor against PPF, reducing the risk by 41% (6). In our series only 10.1% of the stems involved in a PPF were

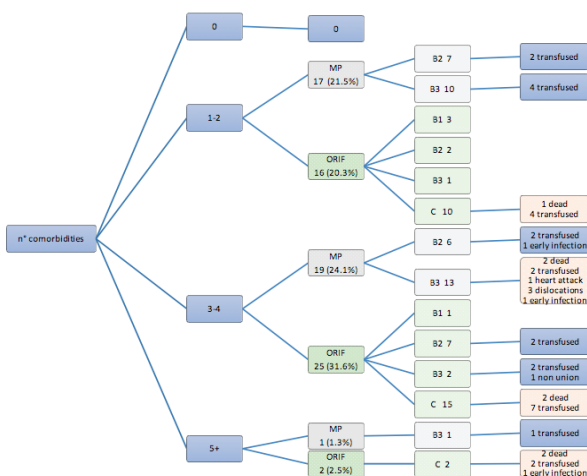
cemented, suggesting that also in our patients the majority of PPFs occurred in cementless prostheses.

In the present study we aimed to analyse clinical and radiological results at an average 5-years follow-up in Vancouver type B and C fractures using ORIF or revision hip arthroplasty with an uncemented modular tapered fluted stem. We have also tried to compare the two different treatments for B2 and B3 fractures.

Patsiogiannis et al. in their review emphasized that pre-operative evaluation of fracture site, characteristic of cement mantle and osteolytic areas surrounding the stem should influence the surgeon choice (17). In fact, good results can be also achieved with ORIF even in B2 and B3 fractures, as reported in the present study and from other Authors (18).

A comparison among results about managing Vancouver B2 and B3 fractures is quite difficult, because of multiple provided technical solutions and various surgeon preferences, that might influence the results (18).

In the present study we had fair clinical results at an average 5-years follow-up after surgical management of PPFs. The HHS was significantly higher in the revision group (79.8 vs 65.6), with a greater percentage of patients without pain (35.1% vs 14.3%), but with a slightly higher return to their pre-injury activity level in the ORIF group (83.3% vs 78.3%). In our opinion extremely low pre-injury functional level might explain the latter. In fact, surgery did not affect at all the functional ability in 7 patients in the ORIF group and in one patient in the revision group (previously

**Graph. 2** Allocation of the patients based on number of Elixhauser comorbidities.

thigh-amputated), and it affected only in minor part the functional abilities of the remaining patients.

As regards systemic complications, in our study they occurred more frequently in Vancouver B3 and C fractures, with 5 deaths within 12 months after surgery in the ORIF group and 2 deaths and one acute myocardial infarction in the revision group. The mortality rate was double in the ORIF group in comparison to revision group (11.9% vs 5.4%). It is well-known that PPFs have high mortality rate, reaching 60% at 5-years in males, over 75 years, with an American Society of Anesthesiologists (ASA) grade  $\geq 3$  (19). In a match-paired study based on the New Zealand Registry on 232 hip revisions for PPFs the 6-month mortality rate was 7.3% in comparison to 0.9% in 232 hip revisions for aseptic loosening, with lower functional outcomes in the first group (20).

Since PPFs are severe injuries, involving elderly patients that usually assume antiplatelets or anticoagulants drugs, it also important to consider the transfusion rate. More than one third of our patients has been transfused in both groups without statistically difference in the two groups. In the literature the transfusion rate after PPFs surgery is also significantly high (11,21).

In this study we tried to focus our attention on factors that may influence the functional outcome or promote the onset of complications. In our opinion the number of comorbidities described in the Elixhauser Comorbidities Index can be one of these elements. It is proved that this index correlates with in-hospital mortality and readmission and is usually used in research for creating models to control the severity of illness, giving a weight to each comorbidity (14,22). It can also be applied in orthopaedics surgery, for example, for predicting adverse events and length of stay after shoulder arthroplasty (23) or to foresee 30-day mortality risks after femur fracture (24). In the present study we listed the Elixhauser comorbidities of each patient, dividing the subjects into four groups, according to the number of pathologies. 6 patients died within 12 months after surgery in the groups with more than 3 comorbidities (12.8%), instead only one patient died in the group with one or two comorbidities (4.3%). Moreover, in the first group one patient had a post-operative myocardial infarction. The Elixhauser Comor-

bidities Index was higher in the group with more than three comorbidities, predicting higher mortality rate, according to the literature (19). Varady et al. showed that Elixhauser Comorbidities Index is more accurate than the ASA score for predicting 1-year mortality after hip fractures (25) and no other studies in the literature used this index for PPFs.

Number of comorbidities also affects the length of stay; in fact patients with more than 5 comorbidities are more likely to have longer length of stay than those with 0 to 2 comorbidities with a higher total cost (12).

Restricted weight-bearing after ORIF may also have affect the outcomes of PPFs in the present study. We allowed early full weight-bearing in 81.1% of the revision hip arthroplasty and restricted weight-bearing for 6 weeks to all patients who underwent to ORIF, because we did not trust in femoral bone quality. In fact, in the literature ORIF in PPFs had a failure rate from 18% to 33% (26-28). Other studies reported similar restrictions and suggested this factor as a negative factor for poor outcomes in B1 and B2 fractures (7,29). Albeit not complication free, revision with modular uncemented tapered fluted stems allows avoiding weight-bearing restrictions that may influence the post-operative functional recovery in elderly patients and our study showed that these stems could be a valid option in Vancouver B2 and B3 PPFs. In fact, stems with distal fixation permit to by-pass proximal femoral comminution or bone loss and to avoid structural bone grafts (30), achieving axial and rotational stability and high rate of fracture union (31,32). Even if some Authors showed low complication rate for PPF osteosynthesis (29), ORIF can sometimes be challenging with higher risk of non-unions and hardware loosening in comparison to revision arthroplasty, with a functional level that might be very poor (20). Park et al. in 27 B2 fractures treated by ORIF with plates and cables had just one refracture, with optimal radiographic results but they stated that mobility of those patients was so low that they were not able to assess them in their clinic (29). Moreta et al. showed marked functional deterioration and high complication rate, despite good radiographic results, as well (33).

In our study we had 100% non union within 10 months in the revision group and 97.6% in the ORIF

group with one case of non-union that needed further revision with double plating technique. These results are consistent with the literature (32,34). Abdel et al. had one stem subsidence that appeared well-fixed at the final follow-up and 11% of dislocations using tapered fluted uncemented stems (31). Dislocation was our main orthopaedic complication in the revision group (3 cases - 8.1%).

In addition, modularity of these revision stems improve the versatility of the implant, making easier to modify the neck version in a second time without removing the distal part of fixed stem (during the same surgery or in case of next revision) or to increase the limb length or femoral offset if necessary. Removal of uncemented stems most of the times is easier to perform in comparison to cemented stems and there is no risk of cement interposition in the fracture, impairing the fracture healing.

The present study has some limits. It has a retrospective design and a mid-term follow-up. However the follow-up was enough long to prove fracture healing and functional recovery.

Then we did not considered if they usually assumed antiplatelet or anticoagulant therapy, that may be a confounding factor, affecting the percentage of blood transfusion in the two groups (ORIF versus revision arthroplasty).

We thought we would be interesting to consider other factors that could have influenced the outcomes, like body mass index or bone mineral density or blood tests like post-operative serum albumin.

PPFFs are severe complications of primary and revision THR, usually associated to poor clinical outcomes. Both osteosynthesis and hip revision arthroplasty with modular uncemented tapered fluted stems can be considered valid procedures for Vancouver B2 and B3 PPFFs. Even if not complication-free, revision stems with distal fixation avoid restricted weight-bearing, that together with low bone quality, high number of comorbidities with elevated Elixhauser Comorbidity Index can be factors affecting the post-operative clinical outcomes and increasing 12-month mortality risk. However, regardless these conclusions, patient-specific considerations should be done in management these injuries: conservative treatment of PPFFs involving a loose stem should be considered in patients

with lower life expectancy, several chronic diseases and poor functional demand.

**Conflict of Interest:** Each author declares that he or she has no commercial associations (e.g. consultancies, stock ownership, equity interest, patent/licensing arrangement etc.) that might pose a conflict of interest in connection with the submitted article

## References

1. Phruetthiphat OA, Otero JE, Zampogna B, Vasta S, Gao Y, Callaghan JJ. Predictors for readmission following primary total hip and total knee arthroplasty. *J Orthop Surg (Hong Kong)* 2020; 28 (3): 2309499020959160.
2. Lindahl H, Garellick G, Regnér H, Herberts P, Malchau H. Three hundred and twenty-one periprosthetic femoral fractures. *J Bone Joint Surg Am* 2006; 88 (6): 1215-22.
3. Kurtz S, Ong K, Lau E, Mowat F, Halpern M. Projections of primary and revision hip and knee arthroplasty in the United States from 2005 to 2030. *J Bone Joint Surg Am* 2007; 89 (4): 780-5.
4. Abdel MP, Watts CD, Houdek MT, Lewallen DG, Berry DJ. Epidemiology of periprosthetic fracture of the femur in 32 644 primary total hip arthroplasties: a 40-year experience. *Bone Joint J* 2016; 98-B (4): 461-7. Erratum in: *Bone Joint J* 2020; 102-B (12): 1782.
5. Della Rocca GJ, Leung KS, Pape HC. Periprosthetic fractures: epidemiology and future projections. *J Orthop Trauma* 2011; 25 Suppl 2: S66-70.
6. Bissias C, Kaspiris A, Kalogeropoulos A, et al. Factors affecting the incidence of postoperative periprosthetic fractures following primary and revision hip arthroplasty: a systematic review and meta-analysis. *J Orthop Surg Res* 2021; 16 (1): 15.
7. Chatziagorou G, Lindahl H, Kärrholm J. Surgical treatment of Vancouver type B periprosthetic femoral fractures: patient characteristics and outcomes of 1381 fractures treated in Sweden between 2001 and 2011. *Bone Joint J* 2019; 101-B (11): 1447-58.
8. Rubin LE, Blood TD, Defillo-Draiby JC. Total Hip and Knee Arthroplasty in Patients Older Than Age 80 Years. *J Am Acad Orthop Surg* 2016; 24 (10): 683-90.
9. Duncan CP, Masri BA. Fractures of the femur after hip replacement. *Instr Course Lect* 1995; 44: 293-304.
10. Reeves RA, Schairer WW, Jevsevar DS. The national burden of periprosthetic hip fractures in the US: costs and risk factors for hospital readmission. *Hip Int* 2019; 29 (5): 550-7.
11. Bozic KJ, Katz P, Cisternas M, Ono L, Ries MD, Showstack J. Hospital resource utilization for primary and revision total hip arthroplasty. *J Bone Joint Surg Am* 2005; 87 (3): 570-6.
12. Ragland K, Reif R, Karim S, et al. Demographics, Treatment, and Cost of Periprosthetic Femur Fractures: Fixation Versus Revision. *Geriatr Orthop Surg Rehabil* 2020; 11:



- 2151459320939550.
13. Gruen TA, McNeice GM, Amstutz HC. "Modes of failure" of cemented stem-type femoral components: a radiographic analysis of loosening. *Clin Orthop Relat Res* 1979; 141: 17-27.
  14. van Walraven C, Austin PC, Jennings A, Quan H, Forster AJ. A modification of the Elixhauser comorbidity measures into a point system for hospital death using administrative data. *Med Care* 2009; 47 (6): 626-33
  15. Lee SR, Bostrom MP. Periprosthetic fractures of the femur after total hip arthroplasty. *Instr Course Lect* 2004; 53: 111-8.
  16. Zheng L, Lee WY, Hwang DS, Kang C, Noh CK. Could Patient Underwent Surgical Treatment for Periprosthetic Femoral Fracture after Hip Arthroplasty Return to Their Status before Trauma? *Hip Pelvis* 2016; 28 (2): 90-7.
  17. Patsiogiannis N, Kanakaris NK, Giannoudis PV. Periprosthetic hip fractures: an update into their management and clinical outcomes. *EFORT Open Rev* 2021; 6 (1): 75-92.
  18. Stoffel K, Blauth M, Joeris A, Blumenthal A, Rometsch E. Fracture fixation versus revision arthroplasty in Vancouver type B2 and B3 periprosthetic femoral fractures: a systematic review. *Arch Orthop Trauma Surg* 2020; 140 (10): 1381-94.
  19. Khan T, Middleton R, Alvand A, Manktelow ARJ, Scammell BE, Ollivere BJ. High mortality following revision hip arthroplasty for periprosthetic femoral fracture. *Bone Joint J* 2020; 102-B (12): 1670-4.
  20. Young SW, Walker CG, Pitto RP. Functional outcome of femoral peri prosthetic fracture and revision hip arthroplasty: a matched-pair study from the New Zealand Registry. *Acta Orthop* 2008; 79 (4): 483-8.
  21. Gibbs VN, McCulloch RA, Dhiman P, et al. Modifiable risk factors for mortality in revision total hip arthroplasty for periprosthetic fracture. *Bone Joint J* 2020; 102-B (5): 580-5.
  22. Moore BJ, White S, Washington R, Coenen N, Elixhauser A. Identifying Increased Risk of Readmission and In-hospital Mortality Using Hospital Administrative Data: The AHRQ Elixhauser Comorbidity Index. *Med Care* 2017; 55 (7): 698-705.
  23. Kim CY, Sivasundaram L, LaBelle MW, Trivedi NN, Liu RW, Gillespie RJ. Predicting adverse events, length of stay, and discharge disposition following shoulder arthroplasty: a comparison of the Elixhauser Comorbidity Measure and Charlson Comorbidity Index. *J Shoulder Elbow Surg* 2018; 27 (10): 1748-55.
  24. Kim D, Jo H, Lee Y, Kim KO. Elixhauser comorbidity measures-based risk factors associated with 30-day mortality in elderly population after femur fracture surgery: a propensity scorematched retrospective case-control study. *Acute Crit Care* 2020; 35 (1): 10-5.
  25. Varady NH, Gillinov SM, Yeung CM, Rudisill SS, Chen AF. The Charlson and Elixhauser Scores Outperform the American Society of Anesthesiologists Score in Assessing 1-year Mortality Risk After Hip Fracture Surgery. *Clin Orthop Relat Res* 2021.
  26. Boesmueller S, Michel M, Hofbauer M, Platzer P. Primary cementless hip arthroplasty as a potential risk factor for non-union after long-stem revision arthroplasty in periprosthetic femoral fractures. *Int Orthop* 2015; 39 (4): 617-22.
  27. Zuurmond RG, van Wijhe W, van Raay JJ, Bulstra SK. High incidence of complications and poor clinical outcome in the operative treatment of periprosthetic femoral fractures: An analysis of 71 cases. *Injury* 2010; 41 (6): 629-33.
  28. Chakrabarti D, Thokur N, Ajnin S. Cable plate fixation for Vancouver Type-B1 periprosthetic femoral fractures-Our experience and identification of a subset at risk of non-union. *Injury* 2019; 50 (12): 2301-5.
  29. Park JS, Hong S, Nho JH, Kang D, Choi HS, Suh YS. Radiologic outcomes of open reduction and internal fixation for cementless stems in Vancouver B2 periprosthetic fractures. *Acta Orthop Traumatol Turc* 2019; 53 (1): 24-9.
  30. Tsiroidis E, Spence G, Gamie Z, El Masry MA, Giannoudis PV. Grafting for periprosthetic femoral fractures: strut, impaction or femoral replacement. *Injury* 2007; 38 (6): 688-97.
  31. Abdel MP, Lewallen DG, Berry DJ. Periprosthetic femur fractures treated with modular fluted, tapered stems. *Clin Orthop Relat Res* 2014; 472 (2): 599-603.
  32. Parry JA, Hernandez NM, Berry DJ, Abdel MP, Yuan BJ. Risk Factors for Subsidence of Modular Fluted Tapered Stems Used During Revision Total Hip Arthroplasty for Periprosthetic Hip Fractures. *J Arthroplasty* 2018; 33 (9): 2967-70.
  33. Moreta J, Aguirre U, de Ugarte OS, Jáuregui I, Mozos JL. Functional and radiological outcome of periprosthetic femoral fractures after hip arthroplasty. *Injury* 2015; 46 (2): 292-8.
  34. Munro JT, Garbus DS, Masri BA, Duncan CP. Tapered fluted titanium stems in the management of Vancouver B2 and B3 periprosthetic femoral fractures. *Clin Orthop Relat Res* 2014; 472 (2): 590-8.

---

Received: 4 May 2021

Accepted: 8 June 2021

Correspondence:

Chiara Concina, MD

Department of Orthopaedics and Traumatology,

San Polo Hospital

Via Galvani, 1

Monfalcone, 34074 Italy

Tel.: 0481-487255

Email: chiara.concina@asugi.sanita.fvg.it



