

Surgical HIP dislocation vs arthroscopy for fixation of subfoveal femoral head fractures

Alessandro Aprato¹, Marco Buzzzone¹, Paolo Di Benedetto²⁻³, Alessandro Massè¹

¹Università degli studi di Torino, Torino, Italy; ²Clinica Ortopedica, Azienda Sanitaria Universitaria Friuli Centrale, Udine, Italy; ³Dipartimento di Area Medica, Università degli Studi di Udine, Udine, Italy

Abstract. *Background.* Reduction and fixation of Pipkin type I femoral head fractures may be performed either via surgical dislocation either via hip arthroscopy but to our knowledge no studies compared those techniques. Aim of our study is to compare (1) Fracture reduction quality, (2) modified Harris hip score at a minimum of 2 years, and (3) Frequency of complications in a case series of patients with femoral head fractures treated with those approaches. *Methods* Five cases of arthroscopic fixation of femoral head fracture (AG) have been compared with our historical cohort (8 patients, SDG). Patient demographic, injury, and surgical variables as well as complications were recorded and retrospectively evaluated. Radiographic outcome was scored according to Matta's criteria on postoperative radiographs and clinical outcomes were evaluated with the modified Harris hip score. *Results* Fracture reduction was anatomic in five hips and imperfect in two in the SDG while four hip were classified as anatomic and one imperfect in the AG. The mean clinical scores were significantly different between the two groups ($p=0.03$): 88 points in SDG (SD 7) and 94 points in AG (SD 5). In the SDG, one patient developed symptomatic femoral head AVN and one had heterotopic ossification. In the AG, no complication (heterotopic ossification and AVN) but one grade I sign of arthritis were noted. *Conclusions* Arthroscopic reduction and fixation of Pipkin type I fracture shows radiographic results comparable to surgical dislocation but better clinical results and lower rates of comorbidity. (www.actabiomedica.it)

Key Words: femoral head fracture; hip arthroscopy; safe surgical dislocation; Pipkin fracture, medial hip arthroscopic portal.

Introduction

Femoral head fractures are relatively uncommon injuries and are usually associated to traumatic hip dislocation after high-energy trauma (e.g. motor vehicle accidents or sport injuries). Degree of fragmentation, location and size of the femoral head fragment are related to the position of the hip at the time of the trauma (Fig. 1A). Femoral head fractures are often associated to hip posterior dislocation due to the collision of the femoral head on the posterior rim of the acetabulum (1-4). Pipkin (5) classified these fractures in four types according to their morphology and relation with femoral neck or acetabular fractures: fracture

caudal to the fovea capitis (Type I), fracture cephalad to the fovea capitis involving the weight-bearing portion of the femoral head (Type II), fracture inferior to the fovea centralis (type I or II) plus femoral neck fracture (Type III) and Femoral Fracture associated to Acetabular Fracture (Type IV).

In Pipkin type I fractures, surgery is recommended when the femoral head fragment is big and displaced: in those cases, if untreated, spontaneous evolution to osteoarthritis after a traumatic hip dislocation combined with femoral head fracture can occur (6). Prompt reduction of hip dislocation is detrimental (Fig. 2), but definitive treatment is controversial (7). The choice of surgical intervention and reconstructive options are in-

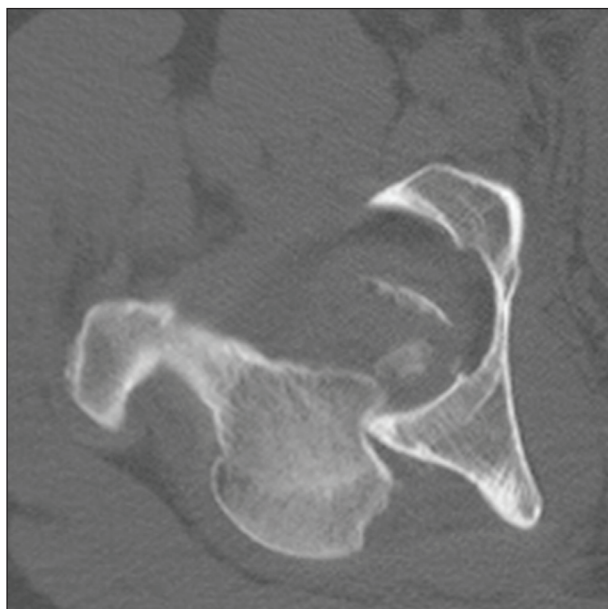


Figure 1: CT-scan slice showing femoral head impaction against the acetabulum.

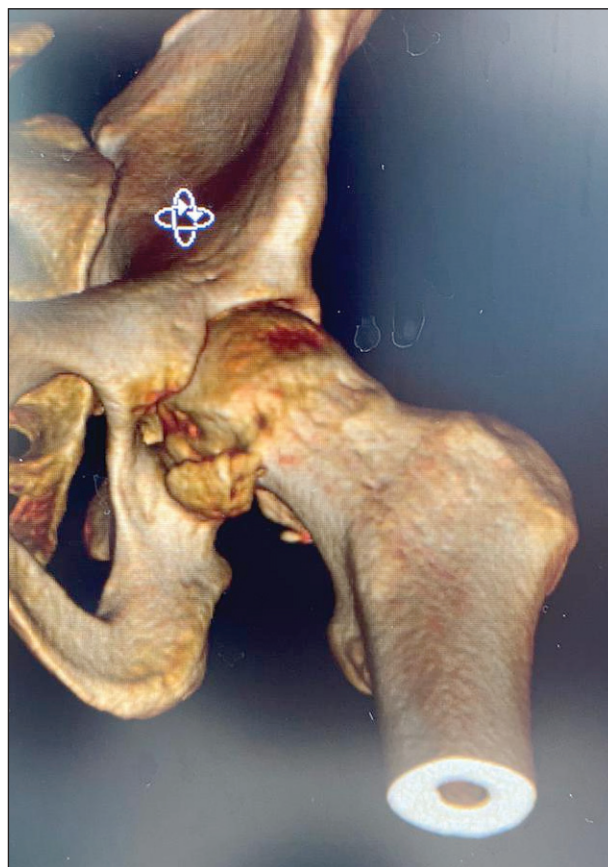


Figure 2: CT-scan slice showing a Pipkin type I fracture after femoral head reduction

fluenced by patient and fracture considerations. Patient factors include physiological age, level of activity, bone quality, and associated comorbidities (8). Open excision of displaced fracture fragments may compromise the fragile circulation of the femoral head because of the associated morbidity and the intrinsic risk of arthrotomy. In older patients, femoral head fracture may be treated with a total hip arthroplasty while, in younger and more active patients, Pipkin type I are usually managed by open reduction and internal fixation (9).

Several approaches (Smith- Petersen, Kocher-langhebeck, etc) have been proposed but surgical dislocation has gained a great popularity in the last decade (10). Surgical hip dislocation allows for a 360 degrees view of the head and may facilitate the reduction (Fig. 3 A-B-C), but its morbidity on the capsule and the greater trochanter may represent a limit of this technique. On the other hand, hip arthroscopy has evolved and some case reports of femoral head fractures treated with arthroscopy have been published (11, 12).

To our knowledge no comparison of those techniques have been reported, therefore the aim of our study is to compare (1) Fracture reduction quality, (2) modified Harris hip score at a minimum of 2 years, and (3) Frequency of complications, including avascular necrosis and heterotopic ossification in a case series of patients with femoral head fractures treated with those approaches.

Materials and Methods

Between 2014 and 2018, we used hip arthroscopy selectively to manage displaced Pipkin type I femoral head fractures. Patients who underwent an arthroscopy were asked to give their informed consent to the use of an unconventional approach. The study was approved by the local ethical committee.

All patients treated with this technique were included and compared to our historical cohort of Pipkin type I fractures treated with surgical dislocation. All patients underwent a preoperative CT scan. Surgical indications were the same in the two groups: a displacement greater than 3 mm on CT scan, fragment dimension major than 20% of the femoral head and age lower than 60 years old were the criteria for those technique. Exclusion criteria was a follow-up of less than 2 years.

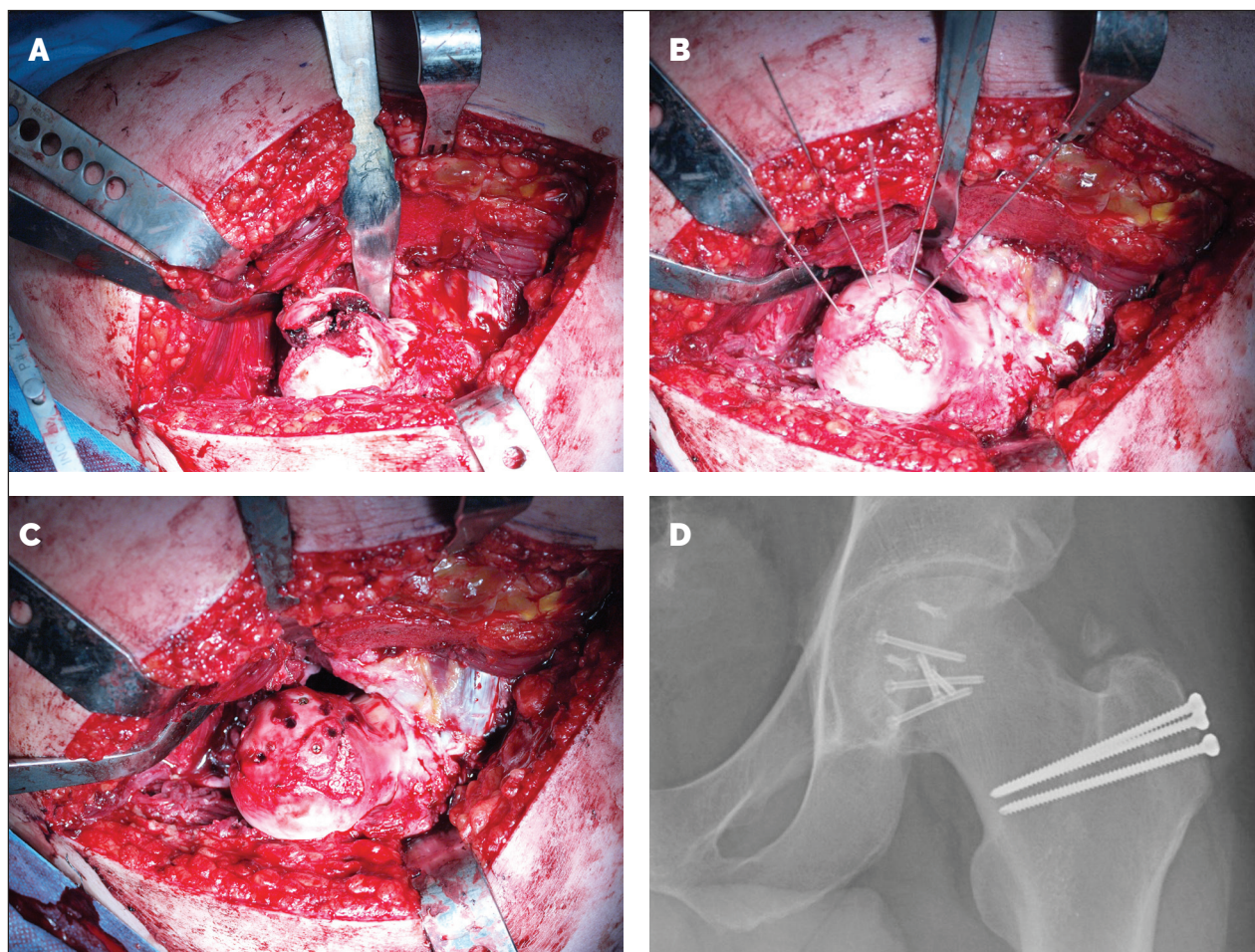


Figure 3: intraoperative view of Pipkin type I fracture before reduction (A), after the achieved reduction is held by k-wires (B), after final fixation (C) and Xrays at two years follow-up (D).

Patient demographic, injury, follow-up and surgical variables as well as complications were recorded and retrospectively evaluated. Fracture reductions were evaluated according to Matta's criteria (13) by measuring the residual postoperative displacements on the two plain radiographs (AP and lateral views). For each of these radiographs, the maximum displacement seen at any of the normal radiographic lines of the acetabulum or the femoral head was recorded in millimeters, and the highest of the three values was used to grade the reduction according to one of three categories: anatomical (0–1 mm of displacement), imperfect (2–3 mm), or poor (more than 3 mm). Radiographs taken at the last follow-up were also classified according to the Tönnis classification (14). Clinical outcome was evaluated with the modified Harris hip score by an

orthopedic surgeon independent from the pelvic team and blinded to surgical findings (MB).

The presence of heterotopic ossification was recorded and graded according to the Brooker classification (15).

Two group comparisons were performed with the chi-squared test for categorical data and continuous data Student t test. The statistical analysis was performed using StataMP13 (Stata Corp., College Station, TX.)

Surgical techniques

Surgical dislocation technique for femoral head reduction have been described in literature (16). Post-operative indications were: to avoid active hip abduc-

tion and passive hip adduction and to avoid weight-bearing on the affected side for one month. All patients received heterotopic ossification prophylaxis with 25 mg indomethacin three times a day for 21 days.

Arthroscopic technique was performed on a standard traction table with the patient supine. Standard arthroscopic technique (17) was used to assess the central compartment in order to fix the labrum (if damaged) and to remove small fracture's fragments (if present). Then the peripheral compartment was investigated. A superolateral viewing portal was created first using a 17-gauge×6-inch spinal needle. The needle was directed under image intensifier control to the displaced fragment. The bevel was rotated such that it is opposed to the bony surface. The spinal needle was then advanced with the bevel sliding along the anterior surface of the femoral neck. On removal of the trocar correct positioning was confirmed by inflating saline in the joint and checking with image intensifier. The portal was then established in the usual manner. The nitinol guide wire should come to rest against the medial wall of the capsule, which should provide springy resistance to further gentle advancement. The guide wire was sequentially retracted as the 5.0 mm hip cannula and obturator were advanced. The arthroscope was introduced and a second portal (more distal) established under direct vision and image intensifier control. Once the second portal is established, a RF ablator was used to join the portals and extended them to assist with the free movement of both the arthroscope and the instruments. The arthroscope in the posterolateral portal followed the RF ablator or tissue shaver as it progressed distally and medially to the fragment bed. Hip flexion may assist during this process. Once the fragment is debrided and free (Fig. 4) to move, a medial portal was created abducting and externally rotating the leg. This portal was made at the anterior border of the adductor longus, about 3-5 cm distal to the inguinal crease (Fig. 5) (18, 19).

From this portal a two Herbert screw guide pins were placed in the free fragment and used as joysticks to reduce the fracture (Fig. 6). Eventually, the fragment was fixed with two cannulated Herbert screws with specific attention to avoid the weight-bearing zones and screw protrusion (Fig. 7 A-B). The only post-operative restriction was to avoid weight-bearing on the affected side for one month (20, 21).

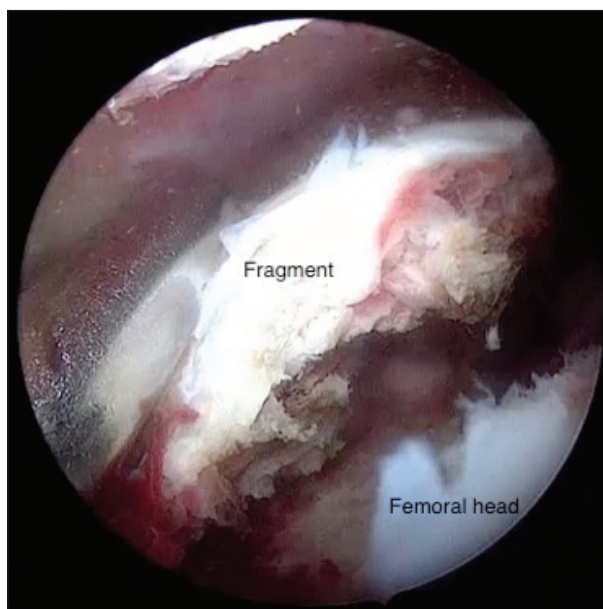


Figure 4: intraoperative arthroscopic view of the femoral head fragment before mobilization

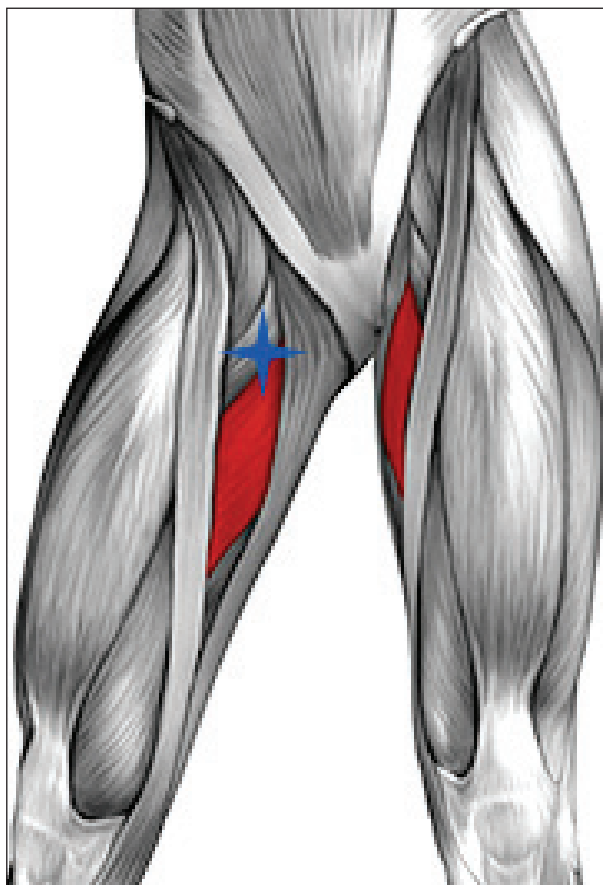


Figure 5: medial portal position

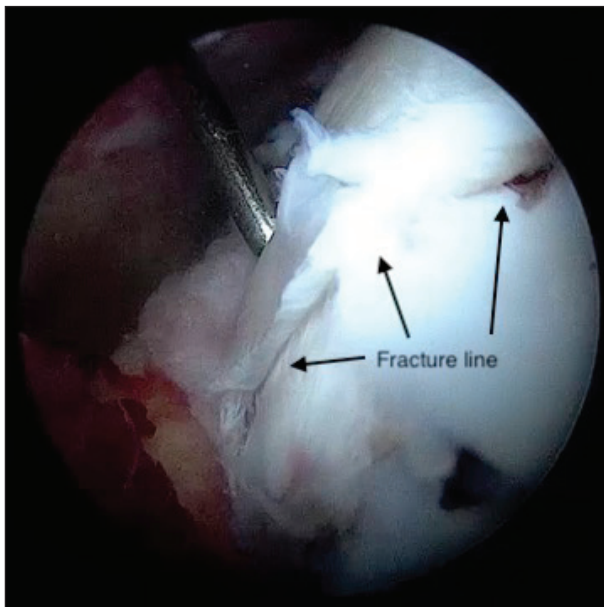


Figure 6: intraoperative arthroscopic view of the femoral head fragment after reduction

Results

This study reviewed five cases of arthroscopic fixation of femoral head fracture and compared them with our historical cohort treated with surgical dislocation (8 patients). In the surgical dislocation group (SDG) one patient was lost before the minimum follow-up (24 months). No patients were lost at follow-up in the arthroscopy group (AG).

Mean ages were 36 and 45 respectively in the SDG and AG group ($p=0.01$) while mean follow-ups were 49 months for SDG and 28 months for AG ($p=0.01$). All patients were males.

The mean surgical time was 121 minutes (SD, 35) for SDG and 100 minutes (SD 10) for the AG ($p=0.28$).

Fracture reduction was anatomic in five hips and imperfect in two in the SDG while four hip were classified as anatomic and one imperfect in the AG. The mean clinical scores were significantly different between the two groups ($p=0.03$): 88 points in SDG (SD 7) and 94 points in AG (SD 5). In the SDG, one patient developed symptomatic femoral head AVN and underwent total hip arthroplasty 4 years after the index procedure; signs of arthritis (Grade I according to Tönnis classification) were found in one patient and

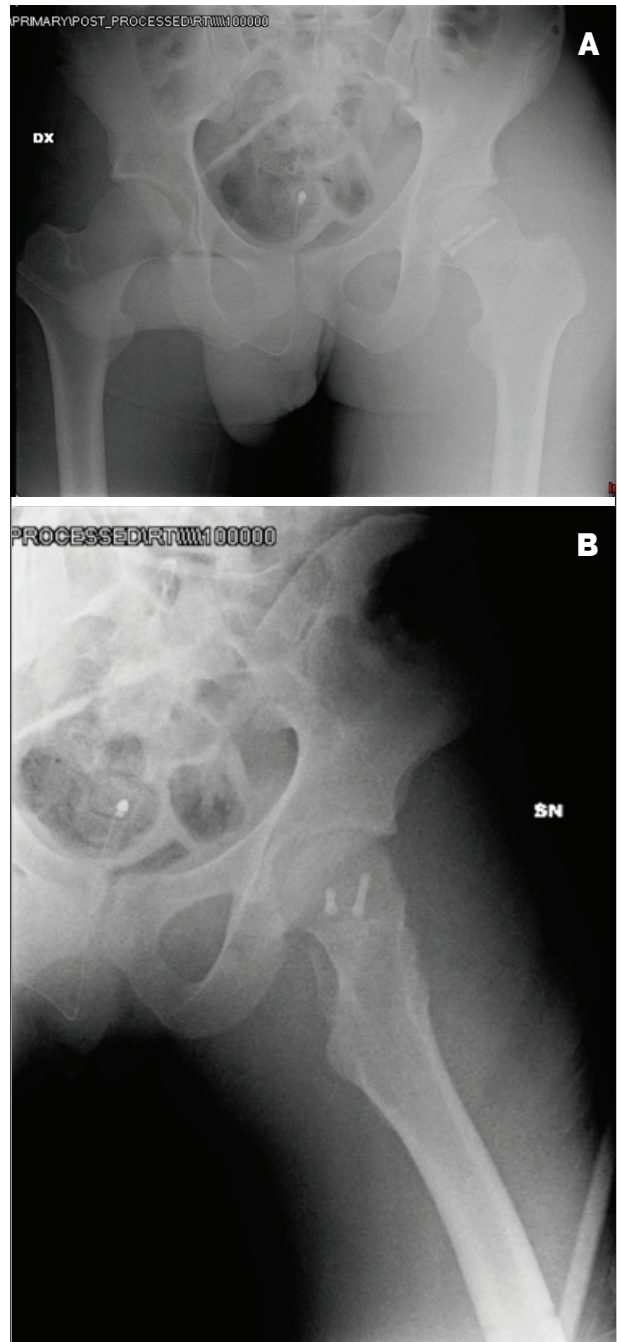


Figure 7: anteroposterior (A) and lateral (B) post-operative X-rays showing the achieved reduction and fixation of the femoral head fragment

heterotopic ossification was recorded in two patients, but neither was symptomatic. In the AG no major complications were reported (heterotopic ossification and AVN) but one patient developed signs of grade I arthritis.

Discussion

Pipkin type-I femoral head fractures are rare injuries and are commonly treated with surgical fixation if the fragment is big and displaced. Surgical dislocation provides full exposure of the femoral head but spare the blood supply to the femoral head (22-25) and is the actual gold standard for those fractures.

Hence, we compared our experience of surgical hip dislocation with a case-series of arthroscopic treatment. The two groups (SDG and AG) were similar in terms of quality of fracture reduction while mean modified Harris hip score was higher in AG than in SDG. Furthermore, frequency of complications, including AVN, arthritis development, and heterotopic ossification were lower in AG.

Our results suggest that hip arthroscopy may be a good choice to treat those fractures. Some other authors reported on arthroscopic treatment of Pipkin type I fractures. The older report, from Lansford, described arthroscopic excision of the fragments and fracture's debridement (26). Yamamoto pioneered the importance of arthroscopy in hip trauma for removing of small fragments in neglected Thomposn-Epstein dislocation type I and II which can be not detected at CT and may lead to hip arthritis (27).

Matsuda (28) described the keystones to arthroscopically treat femoral head fractures: first, the fragment should be identified through arthroscopy and secondly it should be translated toward the fracture site. Using an additional portal, the surgeon should fix it with two Herbert screw guide pins in a chopstick manner in order to de-rotate the fragment and reduce the fracture. Finally, the fragment should be fixed with a cannulated Herbert screw in the central portion and another screw at the proximal pole.

Park (29, 30) reported satisfactory outcomes performing an arthroscopically-assisted percutaneous 3.5-mm cortical screw fixation of displaced infra-foveal Pipkin type I fractures. To achieve this, they used an accessory distal anterior portal and T-shaped capsulotomy.

Yamamoto (27) also performed one arthroscopic fixation of femoral head fracture using absorbable poly-L-lactic acid pin; after a follow-up period of 5 years the patients was completely asymptomatic. Eventu-

ally, Kekatpure made a step by step surgical technique description of arthroscopic reduction and internal fixation of Pipkin type I, advising an additional distal anterior portal for the insertion of the screw perpendicularly to the fracture site and the use of radiopaque headless cannulated compression screw in order to evaluate any screw migration (31) postoperatively. We think the medial portal is even more efficient to achieve the perfect screws' directions (Fig. 8).

This study had a number of limitations. First, this study comprised a single center and was single expert team-based. Thus, there is concern about the reproducibility of this technique; the surgeon who performed all surgeries has been trained to perform the techniques and has experience either in acetabular and femoral head fracture treatment either in hip arthroscopy. Our results may not be reproduced by centres without high volumes of acetabular fractures and/or with less experience in hip arthroscopy. Other limitations are the small number of enrolled patients. There is a possibility for selection bias, but our criteria for inclusion were not markedly different in the two groups. Furthermore, some patients have been lost to follow-up and even a single patient could negatively influence the rate of complications. Eventually we used the modified Harris hip score, which has been criticized in the literature for its ceiling effect (32). Other scoring instruments such as the WOMAC or Hip disability and Osteoarthritis Outcome Score may be more applicable in these patients. However, we chose the Harris hip score here because it is used extensively worldwide, is familiar, and because no clinical score has been validated for femoral head fracture fixation. Since a specific tool to evaluate the reduction of femoral head fractures has not been described in the orthopedic literature, we used the Matta classification. This instrument has been described to evaluate acetabular fracture and shows a good correlation with posttraumatic arthritis development (33) but has not been validated for femoral head fractures and may not correlate with posttraumatic arthritis. AVN could also be present in more patients, who were not identified because postoperative MRI was not always performed. Finally, arthroscopic technique itself also has some limitations, and these deserve comment. Importantly, there is not on the market a specific set of headless

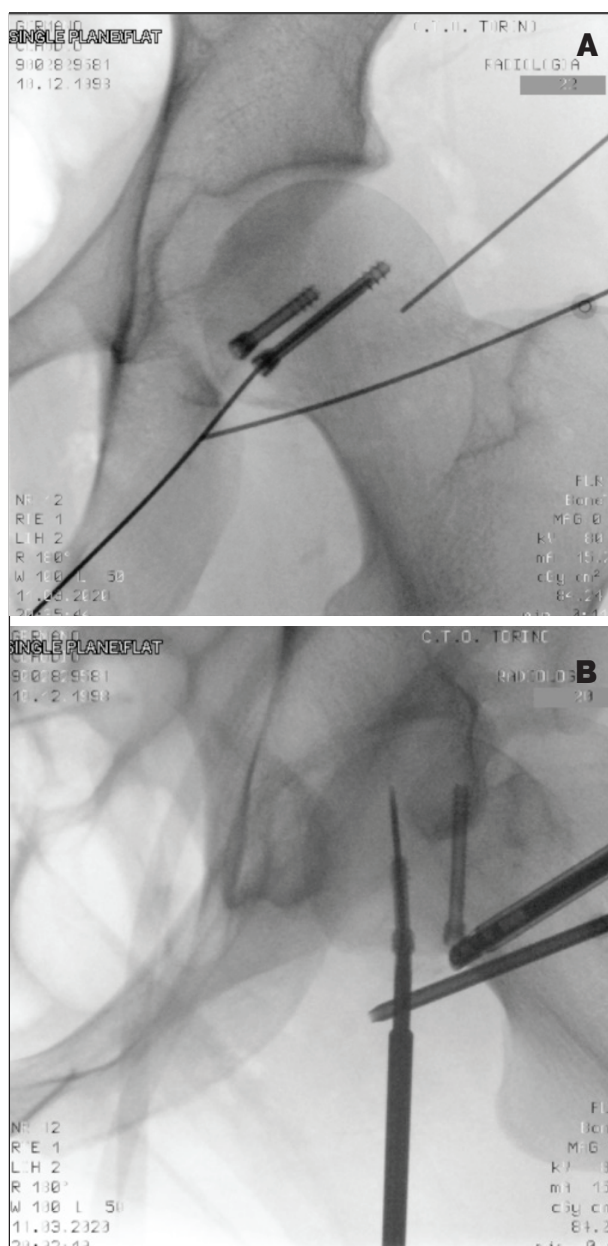


Figure 8: anteroposterior (A) and lateral (B) intraoperative fluoroscopic views showing the optimal direction across the fracture achieved through the medial portal.

screw with the desired dimensions (the actual presents guiding wire too little and flexible). Another major limitation of this approach may be the incomplete vision of the fragment (reduction is based on the only anteroinferior congruence): the amount of residual fracture displacement even if it does not correlate with clinical outcomes, every effort should be made to obtain the best possible reduction. Further study should

focus on assessing the role of residual osteochondral incongruity on arthritis development in the long term.

Conclusions

We recommend consideration of Pipkin type I fracture arthroscopic fixation for surgeons treating either a high volume of acetabular fractures either a high volume of hip arthroscopy. On the other hand, future studies are required to compare this approach with the gold standard in terms of outcome scores and complications with a higher level of evidence.

Conflict of Interest: Each author declares that he has no commercial associations (e.g. consultancies, stock ownership, equity interest, patent/licensing arrangement etc.) that might pose a conflict of interest in connection with the submitted article.

References

1. Thompson VP, Epstein HC. Traumatic dislocation of the hip: a survey of two hundred and four cases covering a period of twenty-one years. *J Bone Joint Surg Am.* 1951; 33:746–778.
2. Clegg TE, Roberts CS, Greene JW, Prather BA. Hip dislocations—epidemiology, treatment, and outcomes. *Injury* 2010. April;41(4):329-334.
3. Beebe MJ, Bauer JM, Mir HR. Treatment of hip dislocations and associated injuries: current state of care. *Orthop Clin North Am.* 2016. July;47(3):527-549
4. Dawson-Amoah K, Raszewski J, Duplantier N, Waddell BS. Dislocation of the Hip: A Review of Types, Causes, and Treatment. *Ochsner J.* 2018;18(3):242-252.
5. Pipkin G. Treatment of Grade IV fracture-dislocation of the hip. A review. *J Bone Joint Surg Am.* 1957;39:1027-1197
6. Oransky M, Martinelli N, Sanzarello I, Papapietro N. Fractures of the femoral head: a long-term follow-up study. *Musculoskelet Surg* 2012;96:95–99.
7. Aprato A, Nardi M, Arduini M, et al Italian Consensus Conference on Guidelines for preoperative treatment in acetabular fractures *Acta Biomedica*, in press
8. Gillespie P, Aprato A, Bircher M. Hip dislocation and femoral head fractures. In: Bentley G, ed. *European Surgical Orthopaedics and Traumatology: the Efort Textbook.* Berlin, Heidelberg, Germany: Springer; 2014:2179-2202.
9. Alonso JE, Volgas DA, Giordano V, Stannard JP. A review of the treatment of hip dislocations associated with acetabular fractures. *Clin Orthop Relat Res.* 2000;377:32-43.
10. Masse A, Aprato A, Rollero L, Bersano A, Ganz R. Surgical dislocation technique for the treatment of acetabular frac-

- tures. *Clin Orthop Relat Res.* 2013 Dec;471(12):4056-64.
11. Aprato A, Bertolo F, Bistolfi A, Sabatini L, Massè A. The Use of Hip Arthroscopy in Trauma of the Hip. In: Büchler L., Keel M. (eds) *Fractures of the Hip. Fracture Management Joint by Joint.* Springer 2019; 189-196
 12. Aprato A, Reboli M, Olivero M, Massè A. Hip Arthroscopy in Trauma In Aprato A (Ed) *What's new in hip arthroscopy,* Novapublishers. ISBN: 978-1-53619-321-3
 13. Matta JM. Fractures of the acetabulum: accuracy of reduction and clinical results in patients managed operatively within three weeks after the injury. *J Bone Joint Surg Am.* 1996;78:1632-1645
 14. Tönnis D. Normal values of the hip joint for the evaluation of X-rays in children and adults. *Clin Orthop Relat Res.* 1976;119:39-47.
 15. Brooker A, Bowerman J, Robinson R, Riley LH. Ectopic ossification following total hip replacement: incidence and a method of classification. *J Bone Joint Surg Am.* 1955;55:1629-1632
 16. Massè A, Aprato A, Alluto C, Favuto M, Ganz R. Surgical hip dislocation is a reliable approach for treatment of femoral head fractures. *Clin Orthop Relat Res.* 2015 Dec;473(12):3744-51.
 17. Aprato A, Giachino M, Masse A. Arthroscopic approach and anatomy of the hip. *Muscles Ligaments Tendons J.* 2016 Dec 21;6(3):309-316.
 18. Polesello GC, Queiroz MC, de Figueiredo MJPS, Braga SR, Riccoli W Jr, Akkari M. Medial hip arthroscopy portals: a novel approach for hip pathologies. Is it feasible? *Hip Int.* 2017 May 12;27(3):e3-e5.
 19. Kang C, Hwang DS, Hwang JM, Park EJ. Usefulness of the Medial Portal during Hip Arthroscopy. *Clin Orthop Surg.* 2015 Sep;7(3):392-5.
 20. Bistolfi A, Guidotti C, Aprato A, et al. Rehabilitation protocol following hip arthroscopy. A 2015 to 2020 systematic review. *Am J Phys Med Rehabil.* 2020 Dec 29;
 21. Jayasekera N, Aprato A, Villar RN. Are crutches required after hip arthroscopy? A case-control study. *Hip Int.* 2013 May-Jun;23(3):269-73.
 22. Gardner MJ, Suk M, Pearle A, Buly RL, Helfet DL, Lorch DG. Surgical dislocation of the hip for fractures of the femoral head. *J Orthop Trauma.* 2005;19:334-342.
 23. Henle P, Kloen P, Siebenrock KA. Femoral head injuries: which treatment strategy can be recommended? *Injury Int J Care Injured.* 2007;38:478-488
 24. Mostafa MF, El-Adl W, El-Sayed MA. Operative treatment of displaced Pipkin type I and II femoral head fractures. *Arch Orthop Trauma Surg.* 2014;134:637-644
 25. Solberg BD, Moon CN, Franco DP. Use of a trochanteric flip osteotomy improves outcomes in Pipkin IV fractures. *Clin Orthop Relat Res.* 2009;467:929-933
 26. Lansford T, Munns SW. Arthroscopic treatment of Pipkin type I femoral head fractures: a report of 2 cases. *J Orthop Trauma.* 2012 Jul;26(7):e94-6.
 27. Yamamoto Y, Ide T, Ono T, et al. Usefulness of arthroscopic surgery in hip trauma cases. *Arthroscopy* 2003;19:269-273
 28. Matsuda DK (2009) A rare fracture, an even rarer treatment: the arthroscopic reduction and internal fixation of an isolated femoral head fracture. *Arthroscopy* 25:408-412
 29. Park MS, Yoon SJ, Choi SM. Hip Arthroscopic Management for Femoral Head Fractures and Posterior Acetabular Wall Fractures (Pipkin Type IV). *Arthrosc Tech.* 2013 Jun 22;2(3):e221-5.
 30. Park MS, Her IS, Cho HM, Chung YY. Internal fixation of femoral head fractures (Pipkin I) using hip arthroscopy. *Knee Surg Sports Traumatol Arthrosc.* 2014 Apr;22(4):898-901.
 31. Kekatpure A, Ahn T, Lee SJ, Jeong MY, Chang JS, Yoon PW. Arthroscopic Reduction and Internal Fixation for Pipkin Type I Femoral Head Fracture: Technical Note. *Arthrosc Tech.* 2016 Sep 5;5(5):e997-e1000.
 32. Aprato A, Jayasekera N, Villar RN. Does the modified Harris hip score reflect patient satisfaction after hip arthroscopy? *Am J Sports Med.* 2012 Nov;40(11):2557-60.
 33. Lichte P, Sellei RM, Kobbe P, Dombroski DG, Gänsslen A, Pape HC. Predictors of poor outcome after both column acetabular fractures: a 30-year retrospective cohort study. *Patient Saf Surg.* 2013 Mar 19

Received: 5 March 2021

Accepted: 7 May 2021

Correspondence:

Alessandro Aprato, MD

Università degli Studi di Torino,

Viale 25 aprile, 137

Torino, 10133 Italy

Phone: 338 6880640

E-mail: ale_aprato@hotmail.com