

Survival and outcome of total elbow arthroplasty for distal humeral fracture at long-term follow-up

Paolo Schiavi¹, Francesco Pogliacomì¹, Alice Garzia¹, Piergiulio Valenti¹, Francesco Ceccarelli¹, Filippo Calderazzi¹

¹Orthopaedic Clinic, Department of Medicine and Surgery, University Hospital of Parma, Italy

Summary

Background: Total elbow arthroplasty is an accepted procedure for the treatment of acute comminuted distal humeral fractures in elderly. Few long-term outcomes are available. The purpose of this study was to examine long-term clinical and radiological outcomes of prosthesis performed (January 2002-June 2015) for complex fractures of the distal humerus (AO/C) in patients older than 65 years with low functional demands. **Materials and Methods:** Further inclusion criteria were: the availability of a clinical and radiological follow-up of minimum 5 years and pattern of closed fracture. Demographic data and characteristics of patients were collected. All patients were clinically and radiographically assessed after 2 and 5 years from surgery. **Results:** Twelve patients were included with complete available data. The mean follow-up was 7.6 years. Five patients reported a worsening of the elbow functionality through the follow-ups. Five subjects had complications. There were no cases of revision surgery. The quality of fixation showed a progressive worsening with increase of radiolucency both on humeral and ulnar side. The recorded MEPS showed no correlation with the grade of periprosthetic osteolysis. Polyethylene bushing wear was scored of grade 2 in one subject who had showed type 4 Morrey radiolucency. **Discussion and Conclusions:** Total elbow arthroplasty is an effective and reliable procedure for comminuted fractures of the distal humerus in elderly, although the incidence of complications can not be considered as negligible. For the majority of these patients, a well-performed implant will give them a well-functioning elbow for their remaining life.

Keywords: total elbow arthroplasty, humeral fracture, periprosthetic osteolysis, radiolucency, outcome.

Introduction

Total elbow arthroplasty (TEA) has become an increasingly accepted procedure for the treatment of elderly patients with acute comminuted distal humeral fractures. Unlike fractures of proximal ulna and radial head, distal humeral fractures are more frequently comminuted and represent a challenge for surgeons (1). Multiple retrospective studies have documented good to excellent clinical outcomes at short- to moderate-term follow-up (2-5).

Because it is a relatively rare procedure, most surgeons have less experience with TEA than hip and knee arthroplasty. Furthermore, many studies have investigated periprosthetic osteolysis and radiographic evolution of hip and knee arthroplasty (6-8), suggesting the application of newer and more performing materials as trabecular metal if necessary (9-11). Instead, we currently have small evidence related to osteointegration and mobilization of TEA after the first years. Lee et al. recently reported the possibility of stem fracture after TEA because of fatigue failure of the implant, thus suggesting the need of careful follow-up in order to

early identify a polyethylene bushing wear and consequent periprosthetic osteolysis.

Few long-term outcomes data are available; a recent publication from the Danish National Patient Register demonstrated a relative risk of revision of 1.75 for TEA secondary to trauma for patients older than 60 years (12). A more recent Scottish registry report demonstrated 10- and 18-year survival rates of 98% for primary TEA performed for trauma, although age was not specified (13).

The purpose of this study was to examine long-term clinical and radiological outcomes of semi-constrained TEAs performed for acute complex intra-articular fractures of the distal humerus classified by AO as type C in patients older than 65 years old and with low functional demands.

Materials and Methods

This study was conducted according to the principles of the Declaration of Helsinki.

Informed consent relating to the surgical and anaesthetic procedures were always obtained. Patients also gave their signed consent for the use of their personal data and clinical/instrumental outcomes for scientific researches.

Patients with complex intra-articular fractures of the distal humerus classified by AO as type C and treated with TEA positioning as first line of treatment were included in the present study (January 2002-June 2015).

All patients were functionally low-demanding subjects. Further inclusion criteria were: the availability of a minimum 5 years clinical and radiological follow-up and pattern of closed fracture. Patients were excluded if they had a vascular injury present at the time of initial injury, a history of previous elbow infection, prior ipsilateral distal humeral fracture, pathologic fracture, fracture with a diaphyseal extension of 8 cm or greater, pre-existing severe joint disease or impending death due to significant medical comorbidities.

Gender, mean age at the time of surgery, mean follow-up, hand dominance, type of fracture, prosthesis

model, selected surgical approach and comorbidities which could adversely affect the clinical and functional outcomes, were recorded. Preoperative anteroposterior and lateral X-rays images of the elbow were used to classify the type of fracture. A CT-scan were recorded if performed in preoperative period in order to complete surgical planning.

Linked prosthetic models fixed with antibiotic-loaded cement were always implanted (Coonrad-Morrey [Zimmer Inc, Warsaw, IN, USA] implant or Latitude prosthesis [Tornier NV, Amsterdam, The Netherlands]) with surgery always done in supine position, with the arm placed over the chest and a haemostatic tourniquet at the base of the involved upper extremity. A triceps sparing approach or Morrey posterior approach was used after the ulnar nerve was isolated and protected.

Postoperative management consisted in immobilizing the elbow in extension with an anterior univalve plaster of Paris cast or splint. Drains and the cast were removed 48 hours later to begin rehabilitation. The first 2 weeks of the early mobilization program consisted in gentle passive elbow extension within a pain free range and active flexion reaching no more than 90°. Active pronosupination was possible with the elbow flexed at 90° after 7-10 days. Therapy sessions were short but frequent during this period to avoid elbow stiffness and triceps muscle activation. In the following 2 weeks, overall elbow range of motion (ROM) was gradually increased by actively flexing the elbow beyond 90° and by actively extending the elbow with the assistance of gravity (the patient was supine with humerus resting alongside the body and supported with cushions or towels). No forceful contractions were allowed, and patient education was mandatory in this phase as the triceps tendon still required protection. The splint was still worn between sessions and at night. Following x-ray controls, the splint could be gradually dismissed during the day and worn at night for another 10-14 days. Therapy sessions became longer and more intensive as triceps strengthening was begun and passive stretching was applied to the joint. The ultimate goal of rehabilitation was to reach ROM of 30° to 130° of extension and flexion as well as stability of the elbow in all planes. The

patient was instructed to avoid impact activities and a lifetime lifting limitation of 3 kg with the operated-on arm during a single event and less than 1 kg if used repeatedly.

All patients were clinically assessed after 2 years from surgery and then contacted for a further clinical follow-up at a minimum of 5 years.

Patients were clinically evaluated using MEPS and were asked about to report on overall function and satisfaction as graded on a 10-point scale, with 10 being a normal elbow and 1 being nonfunctional. Lastly, they were asked to report on the average daily pain level, with 10 being severe pain for the majority of the day and 1 being no pain.

In all cases a radiographic assessment was performed at 2 years from surgery and then at a further follow-up of minimum 5 years. Ulnar and humeral cementation was checked on immediate postoperative X-rays, and classified in 3 types, following postoperative Morrey (PE-Morrey) criteria (14): type 1, adequate cementation with < 1 mm radiolucency at the cement-bone interface and cement going beyond the implant stem; type 2, 2 mm radiolucency at the interface, and cement going beyond the tip of the implant or < 2 mm radiolucency and no cement beyond the implant stem; and type 3, insufficient cementation with > 2 mm radiolucency and no cement beyond the implant stem. Implant fixation was assessed on X-ray ahead of each follow-up consultation, and scored 0 to 4, following again Morrey criteria (LE-Morrey) for evaluation at late follow-up (14): type 0, < 1 mm radiolucency involving < 50% of the interface; type 1, 1 mm radiolucency involving < 50%; type 2, > 1 mm radiolucency involving > 50%; type 3, > 2 mm radiolucency involving the entire interface; and type 4, massive bone lysis.

Polyethylene bushing wear at the hinge was classified on X-ray at last follow-up in accordance with Lee and Morrey (15) in:

- type 1: normal bushings, with < 3.5° ulno-humeral angle in the coronal plane;
- type 2: partial wear, with 3.5°–5° bushing angulation;

- type 3: complete bushing wear, with > 5° angulation.

Results

Twelve patients were included in this study with complete available data. Table 1 presents patients characteristics, demographic data and comorbidities. The dominant arm was involved in 8 patients, whereas 4 were affected on the non-dominant side. The mean follow-up was 7.6 years (range: 5–10). Clinical outcomes registered at 2 years and 5 years follow-up are reported in Table 2.

Five patients reported a worsening of the elbow functionality through the two follow-ups.

Five patients (41,6%) had complications. A superficial wound infection developed in 2 subjects, both suffering from diabetes mellitus, which were treated with intravenous antibiotics and secondary wound debridement. One patient developed a transitory impairment of the ulnar nerve which resolved spontaneously in less than six months from surgery. One subject developed a concomitant deep early infection (*Staphylococcus*

Table 1. Demographic data and characteristics of the patients.

Age	
Mean	74,7
Standard deviation	(+/-7,6)
Gender	
Male	0
Female	12
Associated diabetes mellitus	3
Associated cognitive impairment	2
Associated rheumatoid arthritis	4
BMI	
Mean	26,1
Standard deviation	3,4
Side	
Dominant	8
Non dominant	4

Table 2. Clinical outcome registered at mid- and long-term follow-up.

	2 years	Last follow-up (mean 7.6 years)
MEPS		
Mean	83,4	75,1
Range	45-92	38-89
Overall satisfaction (1-10)		
Mean	7,3	6,4
Range	3-9	3-8
Pain (1-10)		
Mean	3,2	3,1
Range	1-7	1-5

Aureus) treated with antibiotic therapy; wound cleaning was unsuccessfully and further revision surgery could not be performed because of other associated comorbidities. One patient underwent resection for heterotopic ossification.

There were no cases of revision surgery for implant mobilization or stem fracture.

The radiological data at follow-ups were described in Table 3.

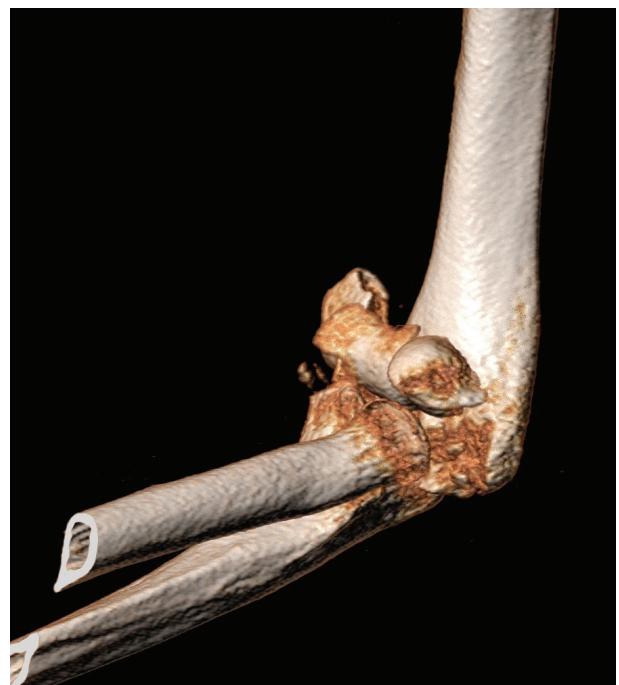The patient with type 4 of Morrey criteria was not considered eligible for revision surgery because of the small clinical impact of the bone resorption. This patient reported an overall satisfaction of 6/10, an average pain level of 3/10 and we registered a mean MEPS of 54,8.

During the years the type of fixation quality showed a progressive worsening with increase of radiolucency both on humeral and ulnar side. However, we did not find a relationship between the cementation quality registered on postoperative X-ray and the progression of radiolucency in the following period. In fact, two patients showed a grade 2 of Morrey criteria in immediate postoperative X-ray (PE-Morrey) and the same two-patients showed a grade 2 at the long-term follow-up evaluation (LE-Morrey) (Fig 1 a-c).

The MEPS registered in patients with radiolucency type 0-1 (mean 76,3) at the last follow-up were compared with the MEPS registered in patients with radiolucency 2-3-4 (mean 71,5) at the last follow-up and we did not document a statistic significant difference (Fig 2 a-b). Moreover, the same result was

Table 3. Radiographic results (NA: not available).

	Immediate postoperative	2 years	Last follow-up (mean 7.6 years)
Cementation quality			
Humeral	Type I: 10 Type II: 2	NA	NA
Ulnar	Type I: 10 Type II: 2	NA	NA
Radiolucency			
Humeral	NA	Type 0: 8 Type I: 2 Type II: 2	Type 0: 7 Type I: 2 Type II: 1 Type III: 1 Type IV: 1
Ulnar	NA	Type 0: 10 Type I: 2	Type 0: 9 Type I: 2 Type II: 1
Polyethylene bushing wear	NA	Type I: 12	Type I: 11 Type II: 1

**Figure 1a.** CT scan - Type C fracture in 83 years-old female.

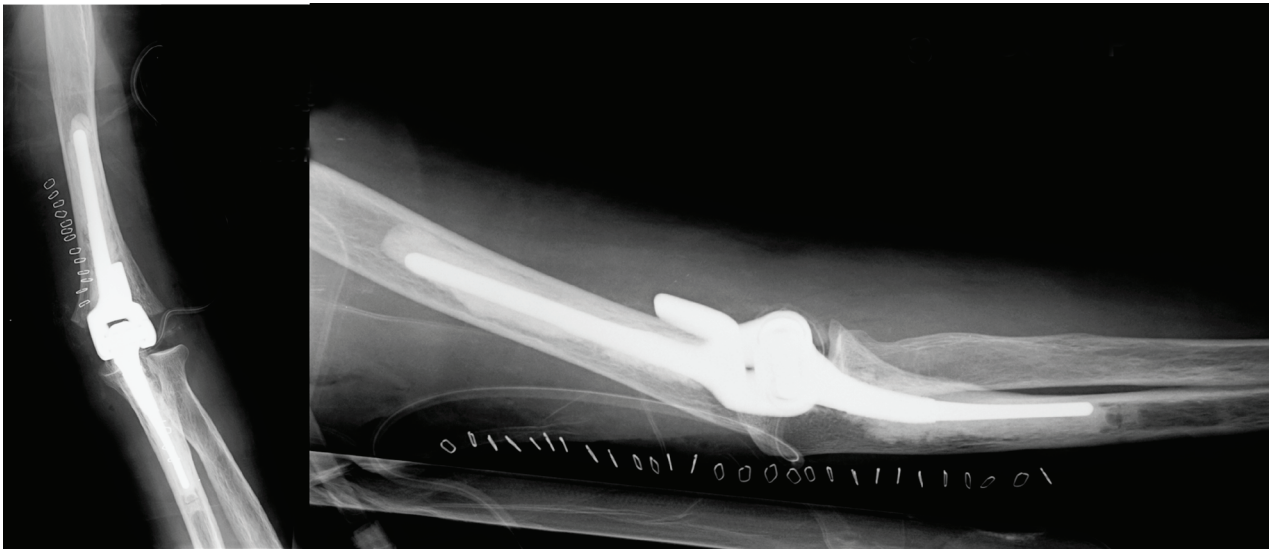


Figure 1b. Postoperative X-rays of Conrad-Morrey implant; grade 2 PE-Morrey criteria.

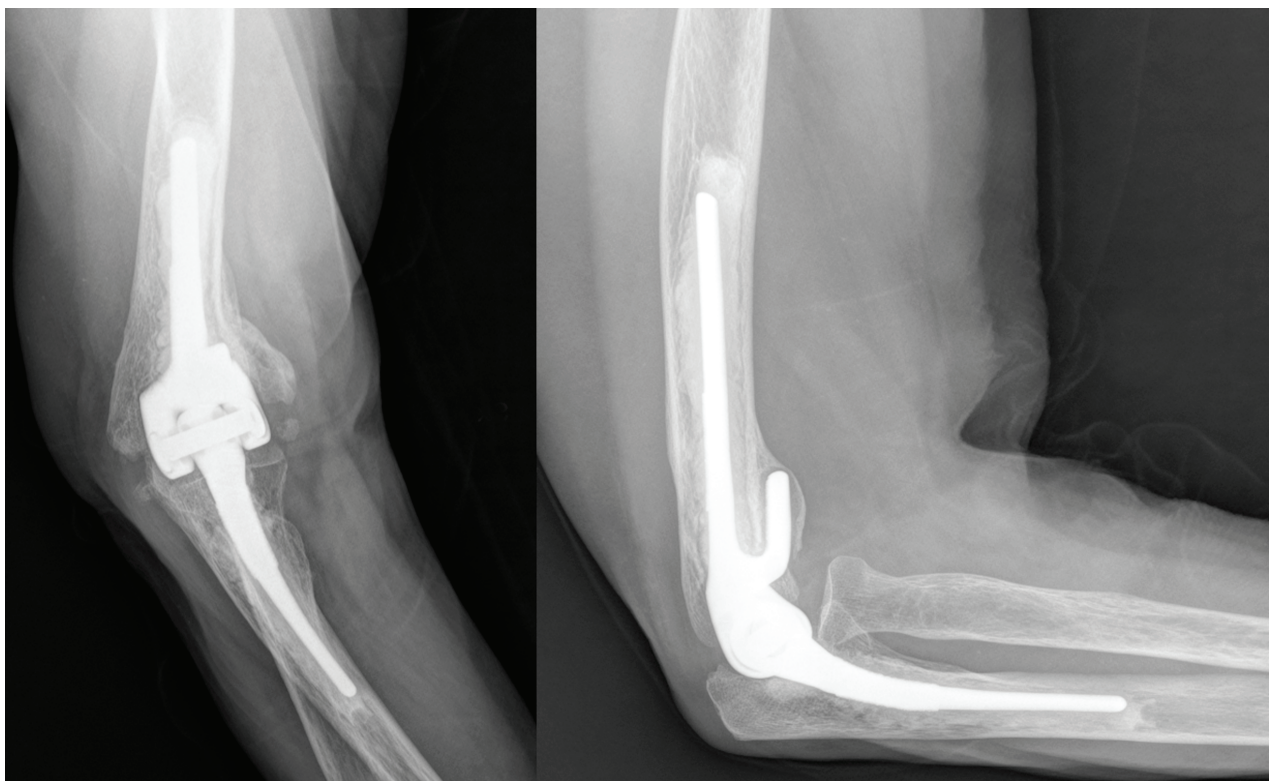


Figure 1c. X-rays at 3 years follow-up; grade 2 LE-Morrey criteria.

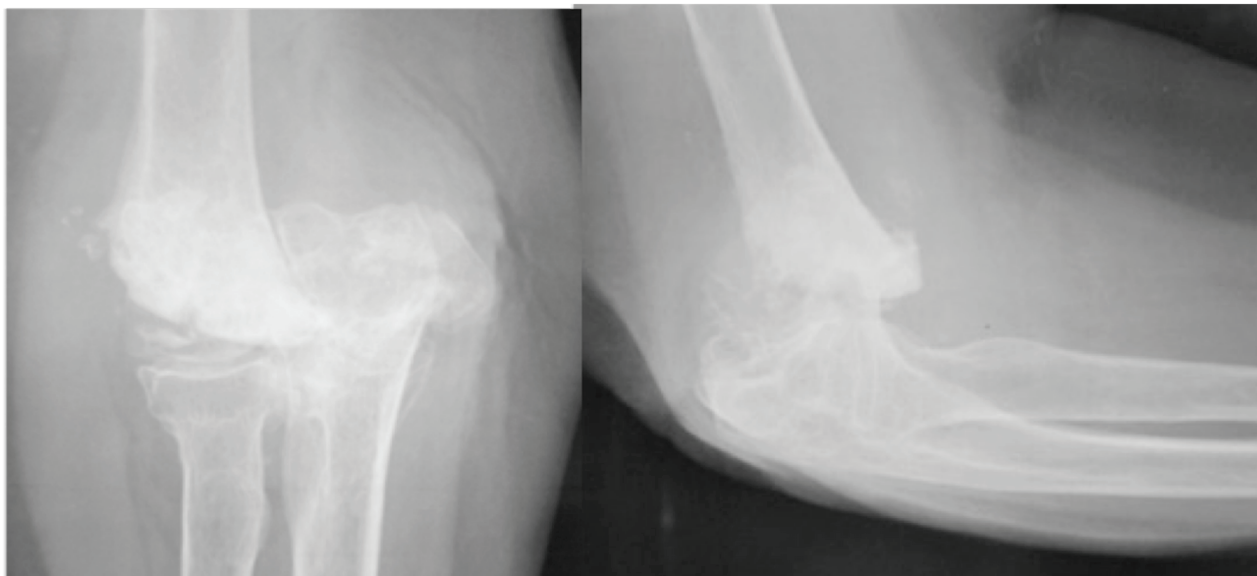


Figure 2a. X-rays – Type C fracture in 83 years-old female.

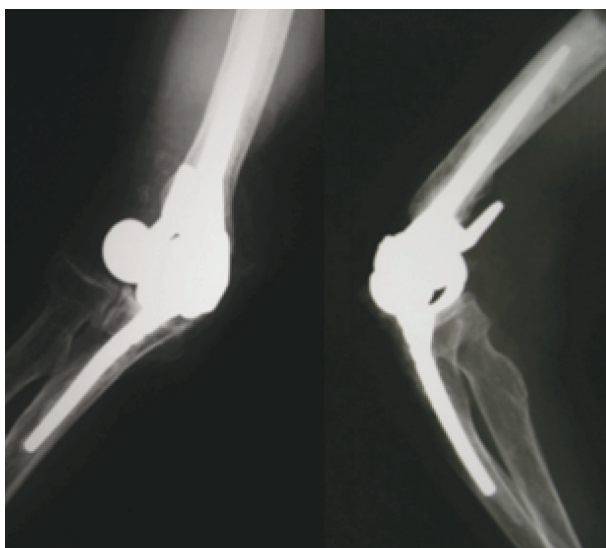


Figure 2b. Postoperative X-rays of Latitude implant; grade 1 PE-Morrey criteria.

documented comparing overall satisfaction and pain in these two groups.

Polyethylene bushing wear at the hinge were registered of grade 2 in one subject at last follow-up and is remarkable that this patient is the only one who showed a type 4 of radiolucency following LE-Morrey criteria.

Discussion

Comminuted intra-articular distal humeral fractures are difficult injuries to treat. These are particularly demanding in the elderly population because of a number of commonly encountered factors, including underlying osteoporotic bone, poor soft tissue, and significant articular and metaphyseal comminution. Treatment options for these patients include nonoperative treatment, ORIF, and TEA. Although nonoperative treatment has been used extensively in the past and continues to be appropriate in a minority of cases, it is associated with a high complication rate and poor functional outcomes (16,17).

Moreover, sequelae of an articular incongruence after elbow fracture can be more difficult to treat with subsequent conservative approach differently from hip and knee (18,19).

A prior RCT of elderly patients with Orthopaedic Trauma Association type 13-C fractures demonstrated that in 25% of cases, the fracture was not amenable to surgical fixation and required intraoperative conversion from ORIF to TEA (20). Similarly, another study regarding elderly patients reported failure of fixation in approximately 25% of patients who underwent ORIF, in whom conversion to TEA was then required (21).

Internal fixation remains the reference treatment, and we need to be cautious, reserving TEA for type B and C fracture in over-70 years-old subjects.

A persistent concern regarding the use of primary TEA in the treatment of elderly patients with distal humeral fractures has been the unknown long-term durability of the prosthesis. Although data up to 2 years have been reported in literature with good results (2,3,4,5,21), long-term data were recently reported only in few studies. A Scottish registry of 1146 primary TEA procedures reported that 12% were performed for trauma, with 10- and 18-years survival rates of 98% (22). Another study of 37 non-rheumatoid patients treated with TEA for distal humeral fractures reported a high mortality rate at 10 years, with only 53% of patients surviving (23). Of the 19 patients with minimum 10-years follow-up data, 3 underwent revision surgery: 1 for aseptic loosening, 1 for bushing polyethylene exchange, and 1 underwent a 2-stage revision for infection prior to the 10-years follow-up. The authors indicated that implant survivorship was 89.5% at 10 years in those patients followed up for a minimum of 10 years. A recent study reported on 44 patients undergoing TEA for distal humeral fractures and found a 18% rate of implant revision or resection at 10 years' follow-up (24).

Deghan et al. registered a high mortality rate (60% in the TEA group) in this elderly patient population, and only 1 of 25 TEAs required revision arthroplasty at a mean of 12.6 years postoperatively (25). These Authors reported that among the 25 patients with TEAs who were long term followed up 28% were still living with their original arthroplasty and were contacted by telephone, 60% had died with a well-functioning implant in situ, 12% were lost at follow-up and 4% (1 of 25) had required an early revision (25).

The high mortality who affects this group of patients could be a partial explanation of the shortage of studies reporting long-term follow-up. However, the small available data show an acceptable survival rate and incidence of complication.

Periprosthetic osteolysis and bone reabsorption around the implant in the elbow could be a problem in a long-term perspective and a recent study of Lee et al. documented as this phenomenon could be the cause of stem fracture for fatigue failure (26). Unfortunately,

not much literature exists about osteolysis due to metallosis in the elbow.

Bonnheim et al. estimated that, on the basis of the conservative assumption of 1 million steps per year, a fatigue fracture of a femoral stem could occur after 28 years in the case of proximal bone support and after 7.3 years in the case of purely distal fixation (27). Moreover, recent designs and material improvement have certified a decrease of periprosthetic osteolysis with better integration for the components of total hip arthroplasty and total knee arthroplasty (7,8,28).

However, Lee et al. reported that 13 component fractures occurred within 4 years and 9 out of 13 were TEA performed for distal humeral fracture or nonunion, with loss of condylar support for the distal part of the prosthesis (26). These Authors particularly registered the importance of polyethylene bushing wear which is ultimately responsible for periarticular osteolysis leading to stress concentration and fatigue fracture of the ulnar and humeral stems as well as of most periprosthetic elbow fractures (26).

In this study this relation seems to be confirmed, considering that the only patient who showed polyethylene bushing wear is the one with the worse type of radiolucency following LE-Morrey criteria.

Limitations of this study include the retrospective design without a control group and the small sample size which might decrease its validity. Varus and valgus radiographic views were unavailable for bushing wear analysis and this could be considered another limitation because these views may help to assess polyethylene bushing wear more accurately. The two different types of implanted prosthesis could make our cohort not homogeneous for type of implant creating a potential bias. Finally, the 1 to 10-point survey was an expedient but unproven technique for assessing patients' pain and function and may not be a reproducible method of assessing outcomes.

Conclusion

TEA is an effective and reliable procedure for comminuted fractures of the distal humerus in elderly patients.

On the basis of the results of this study long-term survival of the implant is good. The incidence of complications can not be considered low but TEA implanted by expert surgeons remains a considerable option of treatment in the elderly and low-demand population. For the overwhelming majority of these patients, a well-performed TEA will give them a well-functioning elbow for the rest of their life and be the last elbow procedure they require. Particular attention should be placed to polyethylene bushing wear and periprosthetic osteolysis because these could lead to possible critical complications.

Conflict of Interest: Each author declares that he has no commercial associations (e.g. consultancies, stock ownership, equity interest, patent/licensing arrangement etc.) that might pose a conflict of interest in connection with the submitted article.

References

- Pogliacomì F, Schiavi P, Pedrazzini A, Nosenzo A, Tocco S, Ceccarelli F. Modified Mason type III and IV radial head fractures: results of different surgical treatments. *Acta Biomed* 2015 Dec 14; 86(3): 242-50.
- Chalidis B, Dimitriou C, Papadopoulos P, Petsatodis G, Giannoudis PV. Total elbow arthroplasty for the treatment of insufficient distal humeral fractures. A retrospective clinical study and review of the literature. *Injury* 2009; 40: 582-90.
- Cobb TK, Morrey BF. Total elbow arthroplasty as primary treatment for distal humeral fractures in elderly patients. *J Bone Joint Surg Am* 1997; 79: 826-32.
- Ray PS, Kakarlapudi K, Rajsekhar C, Bhamra MS. Total elbow arthroplasty as primary treatment for distal humeral fractures in elderly patients. *Injury* 2000; 31: 687-92.
- Pogliacomì F, Schiavi P, Defilippo M, et al. Total elbow arthroplasty following complex fractures of the distal humerus: results in patients over 65 years of age. *Acta Biomed* 2016 Sep 13; 87(2): 148-55.
- Kim SC, Lim YW, Jo WL, Park SB, Kim YS, Kwon SY. Long-Term Results of Total Hip Arthroplasty in Young Patients With Osteonecrosis After Allogeneic Bone Marrow Transplantation for Hematological Disease: A Multi-center, Propensity-Matched Cohort Study With a Mean 11-Year Follow-Up. *J Arthroplasty* 2020 Sep 14: S0883-5403(20)30986-4.
- Wallace CN, Chang JS, Kayani B, Moriarty PD, Tahmassebi JE, Haddad FS. Long-Term Results of Revision Total Hip Arthroplasty Using a Modern Extensively Porous-Coated Femoral Stem. *J Arthroplasty* 2020 Dec; 35(12): 3697-702.
- Pogliacomì F, Schiavi P, Grappiolo G, Ceccarelli F, Vaienti E. Outcome of short versus conventional stem for total hip arthroplasty in the femur with a high cortical index: a five year follow-up prospective multicentre comparative study. *Int Orthop* 2020 Jan; 44(1): 61-8.
- Zhang X, Li Z, Wang W, Liu T, Peng W. Mid-term results of revision surgery using double-trabecular metal cups alone or combined with impaction bone grafting for complex acetabular defects. *J Orthop Surg Res* 2020; 15(1): 301-6.
- Miettinen HJ, Miettinen SS, Kettunen JS, Jalkanen J, Kröger H. Revision hip arthroplasty using a porous tantalum acetabular component. *Hip Int*. 2020 Apr 20:1120700020913294. doi: 10.1177/1120700020913294.
- Loppini M, Schiavi P, Rocca AD, Traverso F, Rocca FD, Mazziotta G, Astore F, Grappiolo G. Double-trabecular metal cup technique for the management of Paprosky type III defects without pelvic discontinuity. *Hip Int* 2018; 28: 66-72.
- Plaschke HC, Thillemann TM, Brorson S, Olsen BS. Implant survival after total elbow arthroplasty: a retrospective study of 324 procedures performed from 1980 to 2008. *Orthop Traumatol Surg Res* 2014; 23: 829-36.
- Jenkins PJ, Watts AC, Norwood T, Duckworth AD, Rymaszewski LA, Mceachan JE. Total elbow replacement: outcome of 1,146 arthroplasties from the Scottish Arthroplasty Project. *Acta Orthop* 2013; 84: 119-23.
- Morrey BF, Bryan RS, Dobyns JH, Linscheid RL. Total elbow arthroplasty. A five-year experience at the Mayo clinic. *J Bone Joint Surg Am* 1981; 63: 1050-63.
- Lee BP, Adams RA, Morrey BF. Polyethylene wear after total elbow arthroplasty. *J Bone Joint Surg Am* 2005; 87: 1080-7.
- Gambirasio R, Riand N, Stern R, Hoffmeyer P. Total elbow replacement for complex fractures of the distal humerus. An option for the elderly patient. *J Bone Joint Surg Am* 2001; 83: 974-8.
- Obert L, Ferrier M, Jacquot A, et al. Distal humerus fractures in patients over 65: complications. *Orthop Traumatol Surg Res* 2013; 99: 909-13.
- Pogliacomì F, Schiavi P, Paraskevopoulos A, et al. When is indicated viscosupplementation in hip osteoarthritis? *Acta Biomed*. 2018 Dec 18;90(1-S): 67-74.
- Xu Z, He Z, Shu L, Li X, Ma M, Ye C. Intra-Articular Platelet-Rich Plasma Combined With Hyaluronic Acid Injection for Knee Osteoarthritis Is Superior to Platelet-Rich Plasma or Hyaluronic Acid Alone in Inhibiting Inflammation and Improving Pain and Function. *Arthroscopy*. 2020 Oct 20: S0749-8063(20)30843-4.
- McKee MD, Veillette CJH, Hall JA, et al. A multicenter, prospective, randomized, controlled trial of open reduction-internal fixation versus total elbow arthroplasty for displaced intra-articular distal humeral fractures in elderly patients. *J Shoulder Elbow Surg* 2009; 18: 3-12.

21. Frankle MA, Herscovici D Jr, DiPasquale TG, Vasey MB, Sanders RW. A comparison of open reduction and internal fixation and primary total elbow arthroplasty in the treatment of intraarticular distal humerus fractures in women older than age 65. *J Orthop Trauma* 2003; 17: 473-80.
22. Jenkins PJ, Watts AC, Norwood T, Duckworth AD, Rymaszewski LA, Mceachan JE. Total elbow replacement: outcome of 1,146 arthroplasties from the Scottish Arthroplasty Project. *Acta Orthop* 2013; 84: 119-23.
23. Prasad N, Ali A, Stanley D. Total elbow arthroplasty for non-rheumatoid patients with a fracture of the distal humerus. *Bone Joint J* 2016; 98-B: 381-6.
24. Barco R, Streubel PN, Morrey BF, Sanchez-Sotelo J. Total elbow arthroplasty for distal humeral fractures: a ten-year-minimum follow-up study. *J Bone Joint Surg Am* 2017; 99: 1524-31.
25. Dehghan N, Furey M, Schemitsch L, Ristevski B, Goetz T, Schemitsch EH; Canadian Orthopaedic Trauma Society (COTS), McKee M. Long-term outcomes of total elbow arthroplasty for distal humeral fracture: results from a prior randomized clinical trial. *J Shoulder Elbow Surg.* 2019 Nov; 28(11): 2198-204.
26. Lee H, Vaichinger AM, O'Driscoll SW. Component fracture after total elbow arthroplasty. *J Shoulder Elbow Surg* 2019 Aug; 28(8): 1449-56.
27. Bonnheim N, Gramling H, Ries M, Shukla S, Iliescu B, Pruitt L. Fatigue fracture of a cemented Omnifit CoCr femoral stem: implant and failure analysis. *Arthroplasty Today* 2017; 3: 234-8.
28. Pitta M, Esposito CI, Li Z, Lee YY, Wright TM, Padgett DE. Failure After Modern Total Knee Arthroplasty: A Prospective Study of 18,065 Knees. *J Arthroplasty* 2018 Feb; 33(2): 407-14.

Received: 10 October 2020

Accepted: 20 November 2020

Correspondence:

Paolo Schiavi

Orthopaedic Clinic, Department of Medicine and Surgery,
University Hospital of Parma, Parma, Italy

Tel. 0039 3394886940

E-mail: francesco.pogliacomini@unipr.it