

Decision/therapeutic algorithm for acetabular revisions

Alessandro Aprato¹, Matteo Olivero¹, Paolo Di Benedetto²⁻³, Alessandro Massè¹

¹Università degli studi di Torino, Torino, Italy; ²Clinica Ortopedica, Azienda Sanitaria Universitaria Friuli Centrale, Udine, Italy; ³Dipartimento di Area Medica, Università degli Studi di Udine, Udine, Italy

Summary

Background and aim: Paprosky's classification is currently the most used classification for periacetabular bone defects but its validity and reliability are widely discussed in literature. Aim of this study was to introduce a new CT-based Acetabular Revision Algorithm (CT-ARA) and to evaluate its validity. The CT-ARA is based on the integrity of five anatomical structures that support the acetabulum. Classification's groups are defined by the deficiency of one or more of these structures, treatment is based on those groups. **Methods:** In 105 patients the validity of the CT-ARA was retrospectively evaluated using preoperative X-rays, CT-scan and surgery reports. The surgical indications suggested by Paprosky's algorithm and by CT-ARA were compared with the final surgical technique. Patients were divided into two groups according to time of surgery. **Results:** We reported concordance of indications in 56,2% of cases with the Paprosky's algorithm and in 63,8% of cases with the CT-ARA. Analysing only the most recent surgeries (group 2), we reported even higher difference of concordance (67,3% Paprosky's algorithm and 83,7% CT-ARA). The concordance of the CT-ARA among Group 1 and Group 2 resulted significantly different. **Conclusions:** the CT-ARA may be a useful tool for the preoperative decision-making process and showed more correlation with performed surgery compared to the Paprosky's algorithm.

Key words: acetabular revision, bone loss, revision indications, CT-based algorithm

Background

Total hip arthroplasty (THA) is considered one of the most successful procedure in orthopaedic surgery. The number of THA performed every year is projected to rise of 71% within the next 10 years and, consequently, the number of revision cases is expected to rise as well (1). Management of periacetabular massive bone loss is one of the most challenging aspect of hip revision surgery and often requires advanced reconstructive techniques (2,3). Properly identification and classification of acetabular bone loss are essential to formulate a detailed pre-operative planning and guide the proper implant choice. Several classifications of acetabular bone loss have been proposed (4) but,

the classification proposed by Paprosky (5) in 1994 is still the gold standard and the most reported in literature (6). Moreover, the same authors (7), published an algorithmic approach, based on his classification, suggesting the revision technique for each category of acetabular bone loss (Figure 1).

However, the validity of the Paprosky's classification is widely debated in literature and poor intra- and interobserver reliability are reported (8–10). Furthermore, several authors demonstrated higher sensitivity of the CT-scan in the identification of periacetabular bone loss compared to X-ray evaluation (9,11,12). To the best of our knowledge, no CT-based classifications of acetabular bone defect are actually available in literature. Secondly, the most established algorithm for

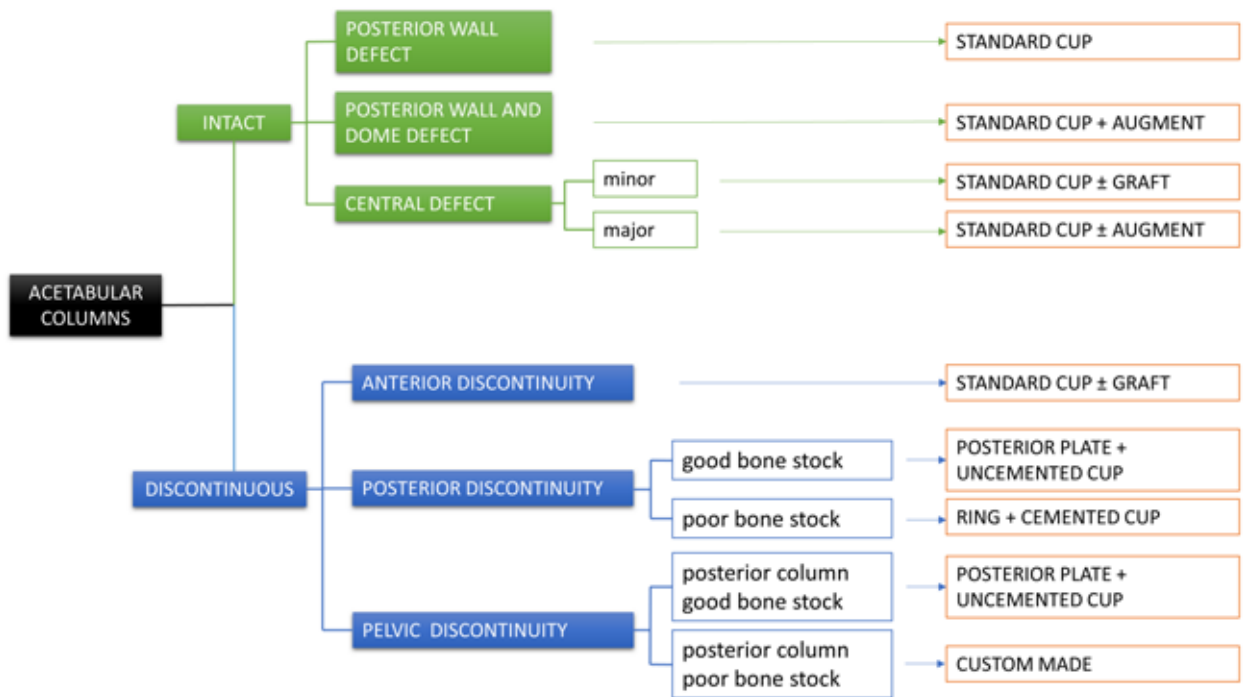


Figure 1. Paprosky's algorithm for acetabular revision

acetabular revisions (7) has been introduced more than 10 years ago and an update that includes the application of modern diagnostic and therapeutic technologies is needed.

Aim of the study

The aim of this retrospective study was to introduce a new CT-based algorithm for preoperative evaluation of bone defect and planning of acetabular revision, to evaluate its validity and to compare it with the validity of Paprosky's algorithm (7).

Methods

Algorithm development

We developed our CT-based Acetabular Revision Algorithm (CT-ARA) on the anatomically based

Letournel's theory that define the anterior and posterior column as a "Y" shaped structure that support the acetabulum (13). We then identify three others bone structures that, as also reported by Paprosky et al. (5), are fundamental for the support of the acetabular cup: the posterior wall, the superior dome and the medial wall. By determining, on the pre-operative CT-scan, the integrity or deficiency of one or more of those structures, we defined 9 possible categories of periacetabular bone defects as reported in Table 1. We defined a deficiency of the posterior wall as an absence of more than 60% of its structure, a defect of the dome as a superior migration of more than 2 cm, anterior column as an absence of at least 1 cm³ of good quality bone along the iliopubic line, minor and major central defects according to central migration of the center of rotation (respectively between 0.5 and 1 cm and more than 1 cm), posterior column as an absence of at least 1 cm³ of good quality bone along the ilioischial line,

pelvic discontinuity as an absence of at least 1 cm³ of good quality bone either in the anterior either in the posterior column.

We finally define, based on our experience and data available in literature (7,14–19), the indications of the type of acetabular revision suggested in each category of bone defects as showed in Figure 2.

Algorithm evaluation

Data were obtained from patients who underwent acetabular cup or THA revision, performed in a large orthopaedic hospital from April 2009 to October 2019. Study’s protocol was approved by the local institution’s research ethics committee.

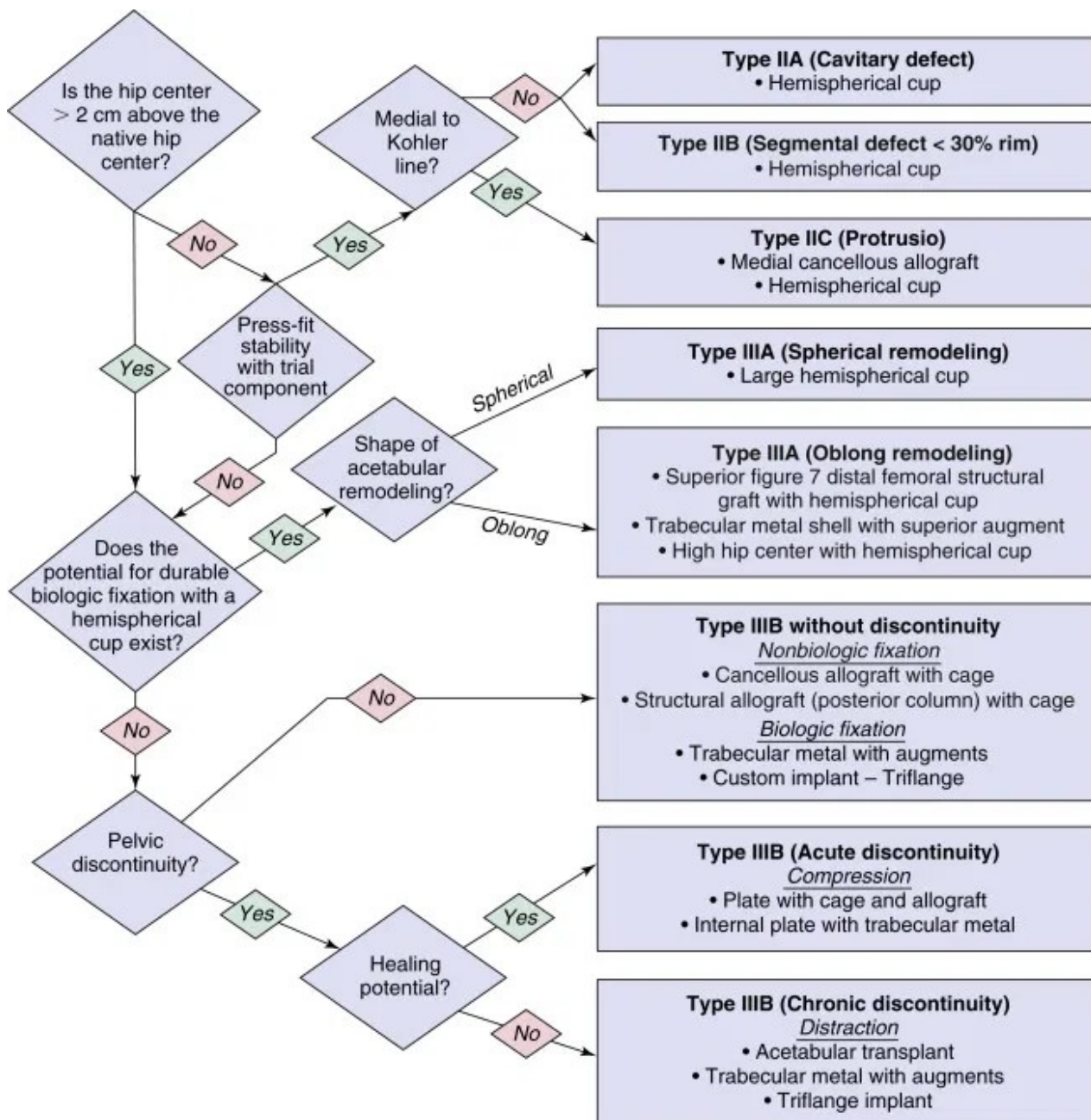


Figure 2. Algorithm for acetabular revision based on periacetabular bone defects (CT-ARA)

Table 1. Categories of periacetabular bone defects.

Periacetabular bone defects
Posterior wall isolated defect
Posterior wall and superior dome defect
Minor central defect (fundus)
Major central defect (fundus)
Anterior column discontinuity
Posterior column discontinuity, good bone stock
Posterior column discontinuity, poor bone stock
Pelvic discontinuity, posterior column good bone stock
Pelvic discontinuity, posterior column poor bone stock

We included in the study all patients underwent revision of the acetabular cup regardless of the diagnosis and the periacetabular bone loss. Patients were instead excluded from the study if the surgical report was incomplete and did not mention the residual bone stock or if preoperative pelvic X-ray and pelvic CT-scan were of insufficient quality or not available in our database.

We collected patient's characteristics, including age, sex, BMI, side, diagnosis, previous surgeries, implant type removed, implant type inserted, time from X-rays and CT-scan to surgery, post-operative indications and intra-operative and post-operative complications.

Patients were divided into two groups according to the date of surgery. Group 1: patients who underwent surgery between April 2009 and June 2015. Group 2: patients who underwent surgery between July 2015 and October 2019.

Two orthopaedic surgeons (AA and MO), separately, reviewed the surgical report, the preoperative X-ray and the preoperative CT-scan and classified the acetabular bone loss according to the Paprosky's classification and according to the CT-ARA. In case of disagreement a third senior orthopaedic surgeon (AM) defined the classification.

For each patient, the surgical indications suggested by the Paprosky's algorithm and by the CT-ARA were evaluated and compared with performed technique. The concordance between the indications of both algorithms and surgical technique were calculated.

Independent Samples t-test was used to evaluate the differences, between the two groups, of average age and time from CT-scan to surgery. Pearson's Chi square test was instead used to identify differences, between the two groups, of sex, periacetabular bone loss according to the Paprosky's classification and concordance between the indications of the CT-ARA and the surgeries performed.

Results

In total, 174 acetabular revisions were identified. Each patient's medical records were retrieved and 5 patients were excluded from the study for incomplete description of bone stock in the surgical report. For the remaining patients, preoperative pelvic X-ray and CT-scan were searched in our database: 8 patients were excluded for the poor quality of the CT-scan and 56 were excluded for the lack of preoperative CT-scan in our database. Study cohort was therefore composed of 105 acetabular revisions in 105 patients divided in Group 1, 56 patients, and Group 2, 49 patients. Baseline data are shown in Table 2.

No statistically significant differences were identified between Group 1 and Group 2 regarding Age (Samples t-test p value: 0,141; O'Brien's test for homogeneity of variance: 0,133), Sex (χ^2 test p value: 0, 478; Pearson's Chi Square statistic: 0,504) and Time between CT-scan and surgery (T-test p value 0,425; O'Brien's test for homogeneity of variance: 0,024).

In 66 patients (62,86%) the revision was due to cup mobilization, aseptic in 56 cases and septic in 10 cases. The others more frequent diagnosis were recurrent dislocations (14 patients, 13,33%), metallosis (8 patients, 7,62%) and polyethylene wear (7 patients, 6,67%). No statistically significant differences were identified about distribution of diagnosis between Group 1 and Group 2.

Distribution of periacetabular bone defects classified according to Paprosky's classification and according to the CT-ARA are reported in Table 3 and 4.

In 47 patients (44,76%) the revision was performed with a standard cup. Rings and cemented cup were used in 21 revisions (20%), standard cup + graft in 17 cases (16,2%), standard cup + augment in 12 cases

Table 2. Baseline data.

Baseline data		Total	Group 1	Group 2
Patients (n)		105	56	49
Age (years)	Median	67,9	69,7	65,9
	IQR	17-87	41-87	17-86
Sex	Male	37 (35,23%)	18 (32,14%)	19 (38,77%)
	Female	68 (64,77%)	38 (67,86%)	30 (61,23%)
Side	Right	50 (47,62%)	25 (44,64%)	25 (51%)
	Left	55 (52,38%)	31 (55,36%)	24 (49%)
Surgery	Cup revision	70 (66,67%)	35 (62,5%)	35 (71,42%)
	Cup re-revision	4 (3,81%)	3 (5,36%)	1 (2,04%)
	THA revision	30 (28,57%)	17 (30,36%)	13 (26,53%)
	THA re-revision	1 (0,95%)	1 (1,78%)	0 (0%)
Time between CT scan and surgery (days)	Median	80,52	87,52	72,53
	IQR	1-454	1-454	1-252

Table 3. Distribution of periacetabular bone defects according to Paprosky's classification.

Paprosky's classification	Total	Group 1	Group 2
1	21 (20%)	9 (16,1%)	12 (24,5%)
2A	16 (15,2%)	10 (17,9%)	6 (12,2%)
2B	15 (14,3%)	11 (19,6%)	4 (8,2%)
2C	19 (18,1%)	7 (12,5%)	12 (24,5%)
3A	26 (24,8%)	15 (26,8%)	11 (22,5%)
3B	8 (7,6%)	4 (7,1%)	4 (8,2%)

(11,4%), custom made implants in 5 cases (4,76%) and posterior plate and uncemented cup in 3 cases (2,85%). The distribution of the different acetabular revisions among Group 1 and Group 2 is reported in Table 5.

The indications of the Paprosky algorithm and the implants actually used in the revisions were concordant in 59 cases (56,2%), 26 (46,4%) in Group 1 and 33 (67,3%) in Group 2. Instead, comparing the CT-ARA and the revisions performed concordance was found in 67 cases (63,8%), 26 (46,4%) in Group 1 and 41 (83,7%) in Group 2. The difference among

Table 4. Distribution of periacetabular bone defects according to the CT-ARA.

CT-ARA	Total	Group 1	Group 2
Posterior wall defect	3 (2,9%)	1 (1,8%)	2 (4,1%)
Posterior wall and superior dome defect	10 (9,5%)	6 (10,7%)	4 (8,2%)
Minor central defect	42 (40%)	16 (28,6%)	26 (53,1%)
Major central defect	8 (7,6%)	4 (7,1%)	4 (8,2%)
Anterior column discontinuity	12 (11,4%)	6 (10,7%)	6 (12,2%)
Posterior column discontinuity, good bone stock	2 (1,9%)	2 (3,6%)	0 (0%)
Posterior column discontinuity, poor bone stock	9 (8,6%)	5 (8,9%)	4 (8,2%)
Pelvic discontinuity, good bone stock	2 (1,9%)	2 (3,6%)	0 (0%)
Pelvic discontinuity, poor bone stock	17 (16,2%)	14 (25%)	3 (6,1%)

Table 5. Distribution of different revision implant types used.

Revision implant type	Total	Group 1	Group 2
Standard cup	47 (44,8%)	18 (32,1%)	29 (59,2%)
Standard cup + augment	12 (11,4%)	5 (8,9%)	7 (14,3%)
Standard cup + graft	17 (16,2%)	12 (21,4%)	5 (10,2%)
Posterior plate + uncemented cup	3 (2,9%)	2 (3,6%)	1 (2,1%)
Ring + cemented cup	21 (20%)	17 (30,4%)	4 (8,2%)
Custom made	5 (4,76%)	2 (3,6%)	3 (6,1%)

Group 1 and Group 2 about concordance between the CT-ARA and the surgery performed was statistically significant (χ^2 test p value < 0,001).

Discussion

Management of periacetabular bone loss represents a challenging aspect in hip arthroplasty revisions. Correct identification of bone loss and a meticulous pre-operative planning are essential to obtain successful results. Pre-surgical evaluation with plain radiography can provide limited information regarding the location and extension of bone loss. In literature, the sensitivity of a single radiograph for the identification of periacetabular bone defect, is reported from 15% to 72% depending on the location and size of the lysis (12,20). In particular, limited accuracy was reported for defects of the posterior column and wall due to the presence of the radiopaque implants (6,21). Nowadays, modern CT-scan with high-resolution acquisition and metal artefact suppression, is considered the gold standard in the evaluation of periprosthetic osteolysis and bone loss with reported accuracy superior to 80% (9,11). The worldwide known Paprosky's classification and algorithm (5,7) are based on single anterior-posterior radiograph. This can limit their efficacy in the preoperative planning and, in literature, poor intra- and interobserver reliability are reported (8–10). This classification system was introduced in the '90s and inevitably does not consider the last diagnostic

and therapeutic technologies advancement. Moreover, to the best of our knowledge, no CT-based classifications of acetabular bone defect are actually available in literature.

In this scenario, we developed the CT-ARA with the objective to introduce an intuitive and user-friendly algorithm based on the CT evaluation of the supporting structures of the acetabulum. The therapeutic indications of the CT-ARA are recommendations based on our clinical practice and experiences, experts opinions and current literature (3,6,15–17,19).

In the CT-ARA, the evaluation of the posterior column plays a crucial role. In all patients with integrity of the posterior column, standard hemispherical cup can be used, alone or in association with trabecular metal augments or cancellous bone grafts according to the different bone defects. As showed in Figure 2, the use of metal augments is indicated in associated posterior wall and superior dome defects and eventually in patients with major central defects. Instead, cancellous bone graft can be used to fill minor central defects and in isolated discontinuity of the anterior column.

Meanwhile, if discontinuity of the posterior column is identified in the preoperative CT, the surgical strategy depends on the quality of the remaining bone stock of the posterior column. In case of good remaining bone stock, independently of the continuity or discontinuity of the anterior column, our recommendation is to reconstruct the posterior column with a plate to support the implant of an uncemented hemispherical cup. Instead, in poor quality remaining bone stock we suggest application of a ring with iliac and ischiatic flange to span the defect, associated with cemented cup.

Finally, in conditions of pelvic discontinuity with poor quality of remaining bone stock, the authors recommend the use of a custom-made acetabular component.

In our study, we evaluated the concordance of indications of Paprosky's algorithm and the CT-ARA and the surgeries effectively performed. We reported concordance of indication in 56,2% of cases with the Paprosky's algorithm and in 63,8% of cases with the CT-ARA. Analysing only the most recent patients (Group 2) we reported even higher difference of concordance (67,3% Paprosky's algorithm and 83,7% CT-ARA).

Moreover, the concordance of the CT-ARA among Group 1 and Group 2 was significantly different. This difference may be justified by the fact that Group 2 represents the more recent cohort. The surgical strategy for these patients may be influenced by the increasing use of high quality preoperative CT. Secondly, the progressive spread of new prosthetic materials and designs could have influenced surgeons' decisions also without a determined algorithm.

There are some limitations in this study. First, the retrospective design of the study may influence its validity. The second weakness is that some categories of the CT-ARA are represented only by few patients. Finally, a limitation of all classifications and algorithms with therapeutic indications is the necessity of further updates for the continuous advancement of diagnostic and therapeutic technologies.

Conclusions

Management of periacetabular massive bone loss is one of the most challenging aspects of hip revision surgery. Meticulous pre-operative planning is essential to achieve stable and long-lasting fixation of the acetabular cup. The proposed CT-based Acetabular Revision Algorithm (CT-ARA) may be a useful tool for the preoperative decision-making process.

Conflict of Interest: Each author declares that they have no commercial associations (e.g. consultancies, stock ownership, equity interest, patent/licensing arrangement etc.) that might pose a conflict of interest in connection with the submitted article

References

- Sloan M, Premkumar A, Sheth NP. Projected volume of primary total joint arthroplasty in the u.s., 2014 to 2030. *J Bone Jt Surg - Am Vol.* 2018;100(17):1455–60.
- Fehring KA, Howe BM, Martin JR, Taunton MJ, Berry DJ. Preoperative Evaluation for Pelvic Discontinuity Using a New Reformatted Computed Tomography Scan Protocol. *J Arthroplasty* [Internet]. 2016;31(10):2247–51.
- Aprato A, Olivero M, Iannizzi G, Bistolfi A, Sabatini L, Masse A. Pelvic discontinuity in acetabular revisions: does CT scan overestimate it? A comparative study of diagnostic accuracy of 3D-modeling and traditional 3D CT scan. *Musculoskelet Surg* [Internet]. 2020;104(2):171–7.
- Telleria JJM, Gee AO. Classifications in brief: Paprosky classification of acetabular bone loss. *Clin Orthop Relat Res.* 2013;471(11):3725–30.
- Paprosky WG, Perona PG, Lawrence JM. Acetabular defect classification and surgical reconstruction in revision arthroplasty. A 6-year follow-up evaluation. *J Arthroplasty.* 1994;9(1):33–44.
- Wirtz DC, Jaenisch M, Osterhaus TA, et al. Acetabular defects in revision hip arthroplasty: a therapy-oriented classification. *Arch Orthop Trauma Surg* [Internet]. 2020;140(6):815–25.
- Paprosky WG, O'Rourke M, Sporer SM. The treatment of acetabular bone defects with an associated pelvic discontinuity. *Clin Orthop Relat Res.* 2005;(441):216–20.
- Gozzard C, Blom A, Taylor A, Smith E, Learmonth I. A comparison of the reliability and validity of bone stock loss classification systems used for revision hip surgery. *J Arthroplasty.* 2003;18(5):638–42.
- Horas K, Arnholdt J, Steinert AF, Hoberg M, Rudert M, Holzapfel BM. Acetabular defect classification in times of 3D imaging and patient-specific treatment protocols. *Orthopade.* 2017;46(2):168–78.
- Paprosky WG, Cross MB. CORR insights® : Validity and reliability of the Paprosky acetabular defect classification. *Clin Orthop Relat Res.* 2013;471(7):2266.
- García-Cimbrelo E, Tapia M, Martín-Hervas C. Multislice computed tomography for evaluating acetabular defects in revision THA. *Clin Orthop Relat Res.* 2007;(463):138–43.
- Leung S, Naudie D, Kitamura N, Walde T, Engh CA. Computed Tomography in the Assessment of Periacetabular Osteolysis. *J Bone Jt Surg.* 2005;87-A(3):592–7.
- Judet R, Judet J, Letournel E. Fractures of the acetabulum. Classification and surgical approaches for open reduction. Preliminary report. *J Bone Jt Surg.* 1964;(46):1615–36.
- Aprato A, Olivero M, Vergano LB, Massè A. Outcome of cages in revision arthroplasty of the acetabulum: A systematic review. *Acta Biomed.* 2019;90:24–31.
- García-Cimbrelo E, García-Rey E. Bone defect determines acetabular revision surgery. *HIP Int.* 2014;24(2):S33–6.
- Massè A, Aprato A, Turchetto L, et al. Reconstruction with rib graft for acetabular revision in pelvic discontinuity: An extreme solution? *Tech Orthop.* 2015;30(4):269–74.
- Sporer SM. How to do a revision total hip arthroplasty: Revision of the acetabulum. *J Bone Jt Surg—Ser A.* 2011;93(14):1359–66.
- Sporer SM, O'Rourke M, Paprosky WG. The treatment of pelvic discontinuity during acetabular revision. *J Arthroplasty.* 2005;20(SUPPL. 2):79–84.
- Volpin A, Konan S, Biz C, Tansey RJ, Haddad FS. Reconstruction of failed acetabular component in the presence of severe acetabular bone loss: a systematic review. *Musculoskelet Surg* [Internet]. 2019;103(1).

20. Claus AM, Engh CAJ, Sychterz CJ, Xenos JS, Orishimo KF, Engh CAS. Radiographic definition of pelvic osteolysis following total hip arthroplasty. *J Bone Joint Surg Am.* 2003 Aug;85(8):1519–26.
21. Yu R, Hofstaetter JG, Sullivan T, Costi K, Howie DW, Solomon LB. Validity and reliability of the paprosky acetabular defect classification hip. *Clin Orthop Relat Res.* 2013;471(7):2259–65.

Received: 10 October 2020

Accepted: 20 November 2020

Correspondence:

Alessandro Aprato, MD

Università degli Studi di Torino,

Viale 25 aprile, 137

Torino, 10133 Italy

Phone: 338 6880640

E-mail: ale_aprato@hotmail.com