

Infinity ankle arthroplasty with traditional instrumentation and PSI prophecy system: preliminary results

Piero Giardini¹, Paolo Di Benedetto², Domenico Mercurio³, Renato Gisonni², Marco Molinari¹, Araldo Causero², Fabrizio Cortese³

¹Department of Orthopaedic Surgery, Fiemme Hospital, Cavalese (TN), Italy; ²Department of Orthopaedic Surgery, University Hospital of Udine, Italy, ³Department of Orthopaedic Surgery, S. Maria della Misericordia Hospital, Rovereto (TN), Italy

Abstract

Background and aim: Ankle arthrodesis has been considered for many years the surgical Gold Standard for the treatment of advanced ankle arthritis; prosthetic replacement of the tibio-talar joint played a secondary role in the treatment of the degenerative pathology of the ankle in relation to the higher rate of failures and complications compared to ankle fusion. The introduction of last generation ankle prostheses lead to better outcome, a lower rate of complication and a longer survival of the implants. Patient Specific Instrumentation (PSI) represents one of the most recent innovations introduced on the market of ankle arthroplasty: PSI is proposed as a surgical technique capable of making ankle arthroplasty more accurate and more reproducible compared to ankle replacements performed with standard referencing guides. **Methods:** Aim of the study is to report early clinical (AOFAS score) and radiographic outcomes (alignment of tibial component) obtained from a single surgeon experience (FC) by implanting the same ankle prosthesis (Infinity, Wright Medical Technologies) using a standard (STD) or a PSI instrumentation. **Results:** Unlike no difference in the average increment of normalized sub score related to function in each group (PSI vs STD), the analysis of normalized pain sub score pointed out a greater average improvement in the PSI group (+75%) compared to the STD group (+62%); this result has been advocated to the absence of post operative gutter impingement syndrome in the PSI group compared to the STD referencing group. The analysis of post operative radiographic angles revealed a more accurate and reproducible positioning of the components in the PSI group compared to the STD group. Furthermore, ankle arthroplasty performed with PSI instrumentation reported a reduction of both surgical times and the need of intraoperative fluoroscopy compared with a standard instrumentation. **Conclusions:** With limitations related to the short follow up and the low number of patients, PSI ankle arthroplasty achieved more accurate and reproducible clinical and radiographic results compared to standard referencing instrumentation; long-term follow-up are needed to demonstrate whether a better positioning of the implant is associated with an increased survival of the prosthesis and therefore justifies the additional costs associated with this technology. (www.actabiomedica.it)

Key words: Ankle Arthroplasty, Prophecy, Ankle Arthritis

Introduction

Unlike osteoarthritis of the hip and of the knee, ankle arthritis is prevalently post-traumatic in up to 70% of cases; arthritis of the ankle is the consequence of a fracture in 37% of cases (**Figure 1 A-C**), of ankle

instability in 16% of cases (**Figure 1 D-E**) and the consequence of a single sprain trauma in 13.7% of cases (18).

The different etiopathogenesis of hip or knee and ankle arthritis depends on specific anatomical, biomechanical and biological peculiarities of these joints (17).

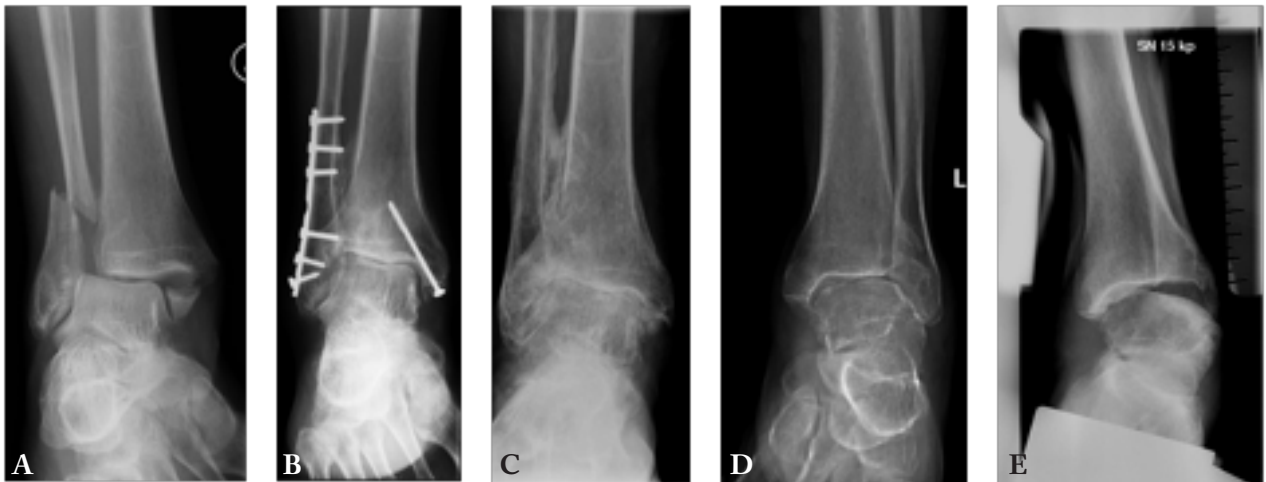

Figure 1. Bimalleolar ankle fracture (A) treated with open reduction and internal fixation (B); post-traumatic ankle arthritis ten years after the fracture (C). Radiographic ankle arthritis (D) due to a severe lateral instability demonstrated on stress radiograph (Telos) (E).

Due to its etiology, the age of patients suffering from end stage osteoarthritis of the ankle is lower than that of patients with osteoarthritis of the hip or of the knee (1).

The age of patients suffering from osteoarthritis of the ankle is a relevant aspect to consider since this has both an economic and a social impact; the morbidity perceived by patients with osteoarthritis of the ankle is comparable to that perceived by patients with chronic renal failure or congestive heart failure (51).

Supra-malleolar realignment osteotomies, debridement procedures and distraction arthroplasty are surgical alternatives with variable results reported in the literature and whose indications are restricted to a limited number of patients (2).

Ankle arthrodesis (AA) (Figure 2) has been for long considered the surgical Gold Standard for severe ankle arthritis (3, 4); AA, although not an optimum from a biomechanical point of view, was classically considered superior to the implantation of a total ankle arthroplasty (TAA) due to the good outcomes associated with the reduction of pain and a lower complication rate compared to ankle prosthesis (3).

Due to the high rate of short-term complications (5), ankle arthroplasty remained for a long time a restricted surgical indication for elderly patients with poor functional demand.

The introduction on the market of a new generation of ankle implants lead to good results both from a functional point of view and from a patient-perceived point of view in association with lower rates of postoperative complications (6).

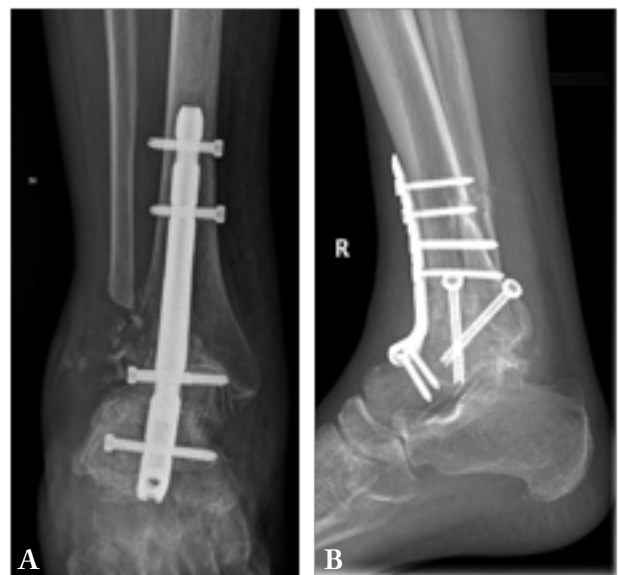

Figure 2. Tibiotalocalcaneal fusion performed with retrograde intramedullary nailing (A). Tibio talar arthrodesis made with an anterior locking compression plate and lag screws (B).

In the most recent meta-analyses, ankle prosthesis resulted to be an effective and comparable surgical approach to ankle fusion in relieving pain (8) with the advantage of ensuring a certain degree of post-operative movement and a reduced incidence of secondary arthritis in the adjacent joints (7).

The evolution of prosthetic materials and designs, the understanding of the importance of soft tissue management, the introduction of new alignment and ligament balancing instruments have determined the incidence of fewer complications, greater patient satisfaction and, ultimately, an extension of implant survival.

One of the most recent innovations in the field of ankle arthroplasty was the introduction of customized alignment jigs produced on the basis of a preoperative planning based on computed tomography (CT) (5, 7, 8).

The present work aims to compare short term clinical and radiographic results obtained by a single surgeon (FC) using the same ankle prosthesis (Infinity, Wright Medical Technologies) alternatively implanted with a traditional extramedullary alignment instrumentation or with a patient specific alignment instrumentation (PSI) customized on the basis of a preoperative CT planning (PROPHECY system) (Figure 3 B, C).

The Infinity ankle prosthesis (Wright Medical Technology) (Figure 3A) is a last generation two-component ankle prosthesis; it is characterized by minimal bone resections, small tibial fixation pegs that avoid the use of long stems, absence of cementation and an anatomical talar component that reproduces the geometry of the native talus (28).

The introduction of PSI technology in ankle arthroplasty is therefore proposed as an innovative technique with the aim of increasing the accuracy and reproducibility in the positioning of the prosthetic components; component alignment in ankle arthroplasty play an important role for the peculiar anatomy of the tibio talar joint in which small misalignments produce a decrease in the contact surfaces and an increase of peak pressure with consequent potential wear of the polyethylene and early implant failure (30, 32).

Some preliminary studies report further potential advantages associated with the PROPHECY system: decrease surgical times, prediction of the size of the components, decrease of the use of intraoperative fluoroscopy with a consequent reduction of exposure to ionizing radiation both for the patient and for the surgeon and a simplification of the surgical technique compared to traditional instruments (30, 32, 41).

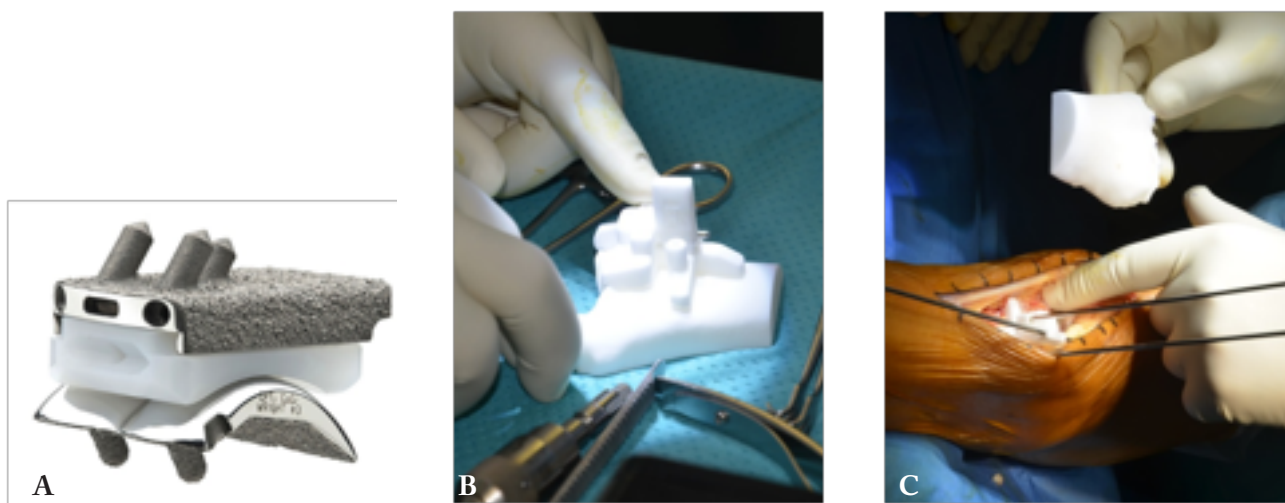


Figure 3. Picture (A) represents the components of the Infinity Ankle Arthroplasty: a talar dome, a tibial platform and an UHMWPE fixed-bearing component. The surgeon uses the bone model (B) as a tactile and visual confirmation of the correct positioning of the tibial guide on the bone of the patient (C).

Materials and Methods

The present work aims to analyze the short-term clinical and radiographic results obtained by a single operator (FC) implanting a third generation ankle prosthesis (Infinity, Wright Medical Technologies) for the treatment of advanced ankle arthritis.

In the period January 2017—December 2019 at the Orthopedics and Traumatology Unit of the Hospital of Rovereto, 49 patients (49 ankles) suffering from symptomatic arthritis of the ankle and not responsive to conservative therapies were surgically treated. Of these 49 patients, 15 (15 ankles) underwent fusion of the tibio talar joint, the remaining 34 patients (34 ankles) underwent the implantation of an ankle arthroplasty; among the patients who underwent ankle prosthesis, in 17 patients an Infinity implant was used.

Among the patients who received an Infinity ankle prosthesis, in 7 cases (7 ankles) a traditional extramedullary alignment instrumentation was used (STD group), while in the remaining 10 cases a patient specific instrumentation (PSI group) was used; the assignment to one of the two groups was performed randomly.

At the time of the preoperative visit, an AOFAS (American Orthopedic Foot and Ankle Society's ankle-hindfoot scale) was calculated for the patients of both groups; this clinical score, used in its Italian validated version (31), is based on the compilation of a questionnaire, divided into three sections concerning pain (0–40 points with 0 equal to pain always present and 40 equal to no pain), function (0–50 points with 0 equal to maximum limitation and 50 equal to no limitation) and rearfoot alignment (0–10 points with 0 equal to severe misalignment and 10 equal to no misalignment).

The degree of preoperative coronal deformity was calculated on the radiographs of the patients of both groups on loading radiographs of the ankles; this calculation was performed using a digital image processing program (Synapse RAD Mobility) by calculating the Medial Distal Talar Angle (MDTA) (33). This angle is calculated from the intersection of a straight line passing through the anatomical axis of the tibia with the one passing through a tangent to the surface of the tibial plafond (Fig. 4A).

The patients belonging to the PSI group also underwent a CT study of the ankle according to the PROPHECY protocol (Fig. 4B). Preoperative planning and positioning of the tibial component in the

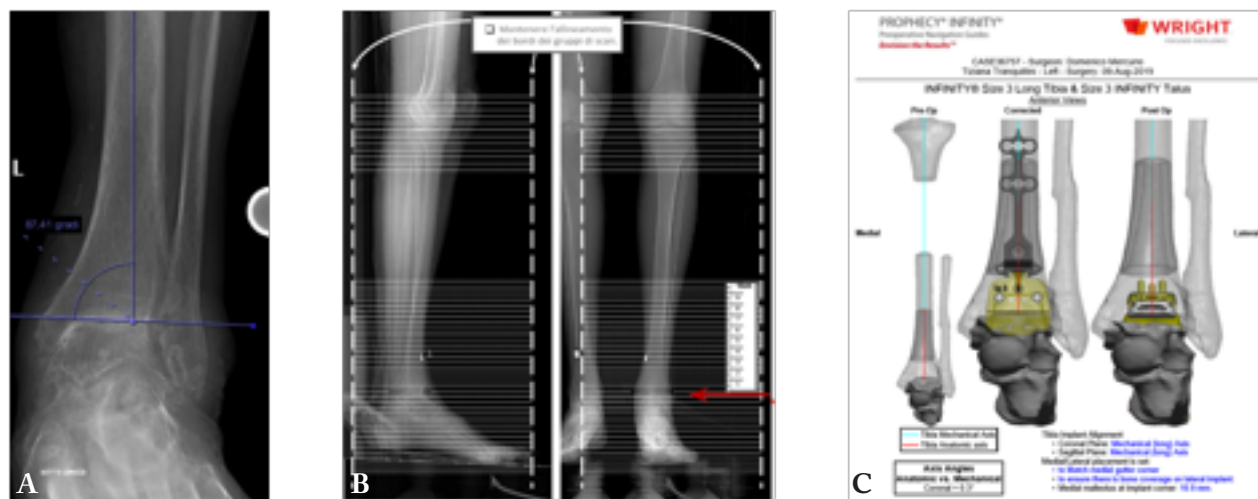


Figure 4. The MDTA represents the angle considered by the intersection of a straight line passing through the anatomical axis of the tibia with the one passing through a tangent to the surface of the tibial plafond (A). The PROPHECY TC protocol requires scans 5 cm above and 5 cm beneath the knee joint line and scans of the ankle 10 cm above the tibio talar joint and including distally the whole foot (B). On the basis of the preoperative TC, a preoperative planning of the positioning of the ankle arthroplasty implant is created (C).

PSI group were carried out in all patients following the mechanical axis to obtain a neutral positioning of the tibial component (**Fig. 4C**).

The validation of the preoperative planning and the prosthetic ankle implants were performed in all patients by the same surgeon (FC); as mentioned, all patients received the same Infinity ankle prosthesis. At the last post-operative follow-up visit, patients were again tested with the AOFAS questionnaire and exposed to weight bearings radiography of the ankles.

The change in AOFAS score between pre and post-operative was used as an index of patient satisfaction following the implantation of the ankle prosthesis.

On post-operative radiographs, the MDTA was recalculated as the angle between the anatomical axis of the tibia and a tangent to the surface of the tibial prosthetic component (Fig. 51, 52). A post-operative MDTA of 90°, corresponding to a neutral positioning of the tibial component, represented the final goal of implantation of the prosthesis in both groups of patients.

For immediate understanding, the absolute value of MDTA, both pre and post operative, was expressed as a difference from 90°; to simplify the measurements, a rounding down for decimals lower than 0.5 and upwards for decimals higher than 0.5 has been carried out.

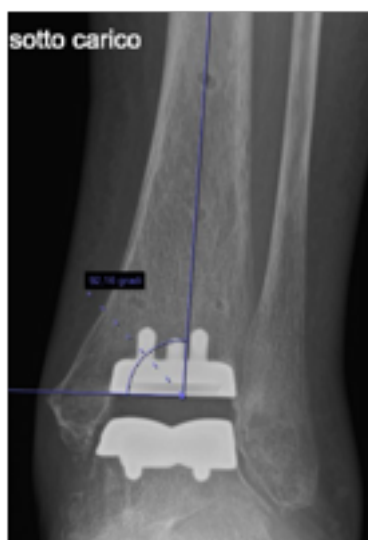

Figure 5. Postoperative MDTA is calculated as the angle created by the anatomical axis of the tibia and the tangent to the inferior surface of the tibial component.

Since traditional instrumentation do not allow alignment on the mechanical axis, the calculation of the MDTA on the post-operative radiographs of the PSI group was corrected for each patient for the difference in degrees between the anatomical axis and the mechanical axis; this difference is a data provided by preoperative planning and the same calculation method was used in a recently published study (3).

The degrees of deviation of the tibial component from the neutral axis were used as an index of the accuracy and reproducibility of the instruments used (STD vs PSI).

For each procedure, some data relating to the surgical intervention were extrapolated: the surgical times (considered from the incision of the skin to the end of the suture) and any accessory surgical procedures carried out simultaneously with the implantation of the ankle prosthesis were detected from the operating register. From the final report produced by the fluoroscopy amplifier were extrapolated data concerning the number of scans performed and the time of exposure to ionizing radiation during each procedure.

Patients of both groups underwent the same post-operative rehabilitation protocol regardless of the accessory procedures performed.

Any intra, peri and post-operative complications were recorded and reported through clinical follow-up and through the SIO (Hospital Information System).

Results

Of the 17 patients who underwent Infinity ankle prosthesis implantation a total of nine left ankles and eight right ankles were implanted.

The two groups were homogeneous due to sex, age and the etiopathogenesis of ankle arthritis which led to ankle prosthesis.

The patients of the STD Group were re-evaluated at an average follow-up of 18 months (minimum 15, maximum 22) while the patients of the PSI group at an average f.up of 12 months (minimum 6, maximum 22).

The AOFAS score of the two groups overall increased from a mean of 55.77 in the pre-operative to a 81.77 in the post-operative and corresponds to a score increase of 46.62% (**Figure 6**).

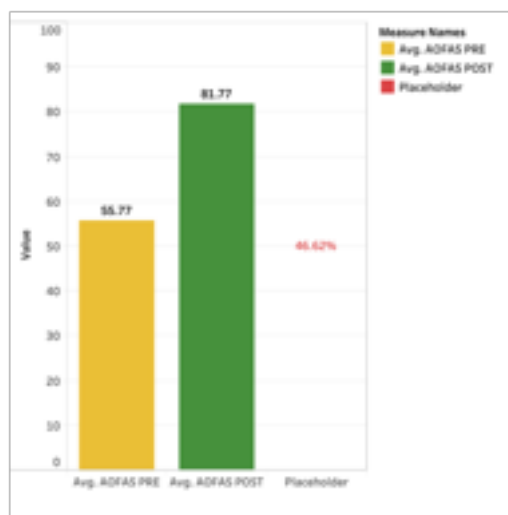


Figure 6. Cumulative average preoperative (yellow column) and post operative (green column) AOFAS score.

An average preoperative AOFAS score of 59.0 in the STD group (min 27, max 65) and 50.6 in the PSI group (min 34, max 71) emerged from the analysis of the AOFAS files divided into groups. The mean post-operative AOFAS score was 84.38 in the STD group (min 71, max 88), 77.60 in the PSI group (min 75, max 95); these values correspond to an increase in the AOFAS score of 43.01% in the STD group and 53.36% in the PSI group (**Figure 7**).

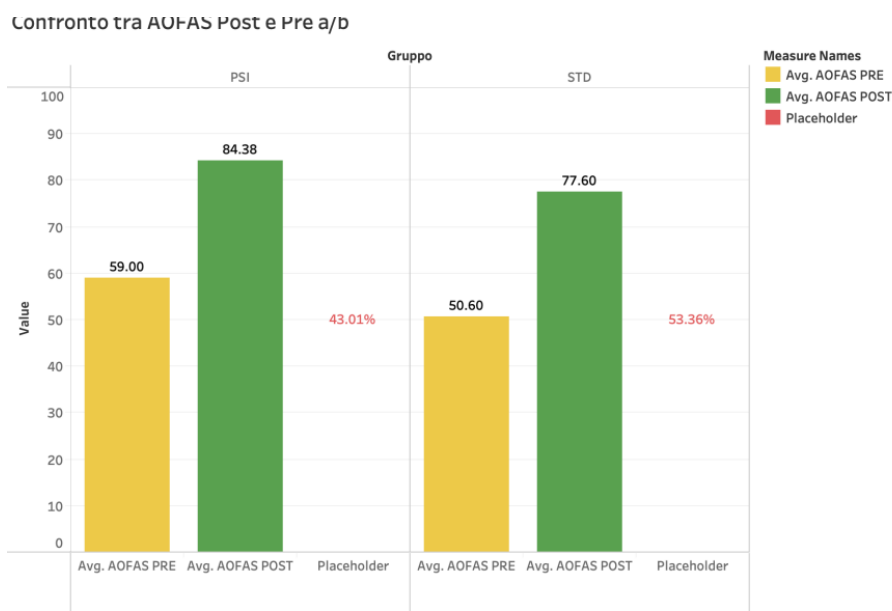


Figure 7. Pre and post operative AOFAS score distinguished in the two groups (STD and PSI).

The AOFAS score was analyzed not only as an overall score but also in its pain and function categories; since these categories have different scales (0-40 for pain, 0-50 for function), the numerical values have been normalized in order to be made comparable.

Figure 8 and **9** consider the percentage change in the normalized AOFAS score for the function and pain categories without considering the patients divided by group; graph 3 shows an improvement in the AOFAS score relating to pain of 66.67% between pre and post operative; in the category related to function (**Figure 9**), the AOFAS score marked an increase of 32.19%.

The analysis of the normalized AOFAS scores for pain and function categories carried out considering the patients distinguished by group of study (STD and PSI) (**Figure 10** and **11**) highlighted results as follows: the category related to pain showed an improvement of 75% in the PSI group and 62.5% in the STD group while in the category related to function an increase of 34.48% in the PSI group and 30.92% in the STD group.

In the PSI group, the implanted prosthetic size corresponded to the preoperative pianification in 100% of cases for the tibial component and in 80% of cases for the talar component.

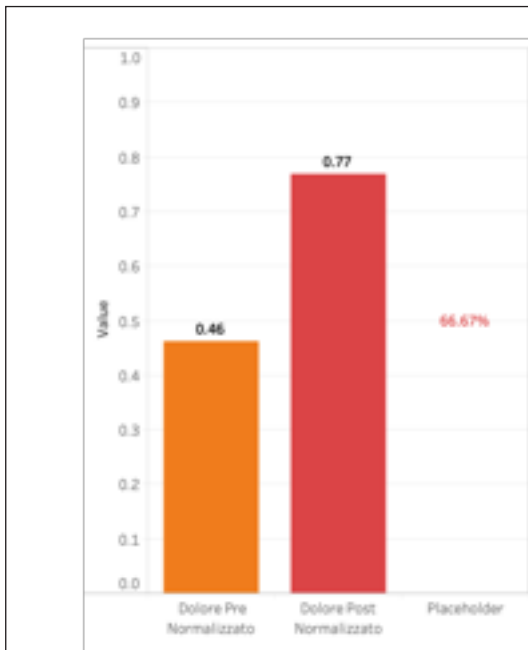


Figure 8. Cumulative average modification of the pain subscore between preoperative (yellow column) and post operative (red column).

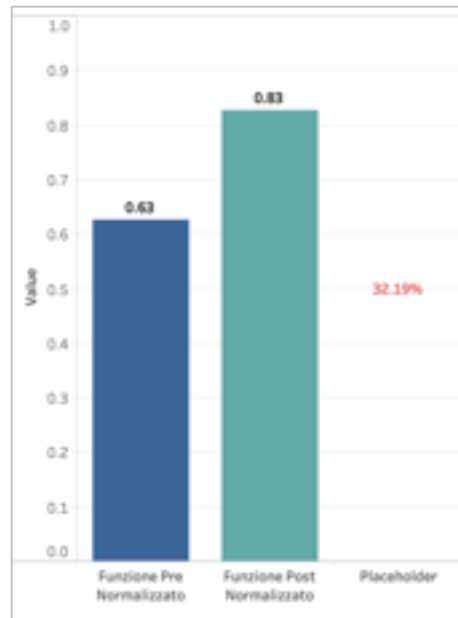


Figure 9. Cumulative pre (blue column) and post operative (light blue) functional sub score.

The analysis of the distributions of the MDTA showed an average preoperative deformity in the two groups of 3.7° in varus (max 11° of valgus and 10° of varus); the mean preoperative deformity was 2° in varus in the PSI group and 5.4° in varus in the STD group (**Figure 12A**).

In the PSI group it was possible to trace the difference between the anatomical axis and the mechanical axis of the tibia from the preoperative planning for each patient; this difference was on average 1.65° (min 0.1°, max 5.1°).

The post-operative alignment analysis (**Figure 12B**) highlight a lower dispersion (red circle) of the measurements in the PSI group compared to those of the STD group.

The cumulative distribution analysis of post-operative angles (**Figure 13**) resulted within 1° of neutral alignment (+1°, -1°) in 87.5% of patients and within 3° of optimal neutral alignment in 100% of patients in the PSI group.

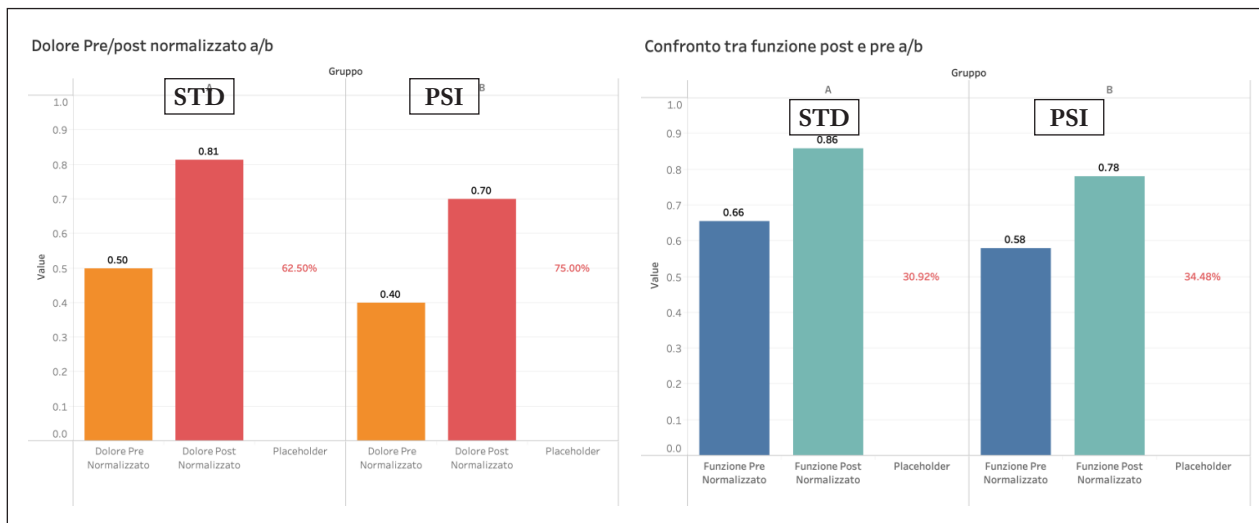
In the STD group, 40% of patients achieved a compressed alignment between + 3° and -3° from the neutral alignment; the graph relating to the

distribution of the MDTA in the STD group also highlights a more variable distribution than that of the PSI group.

The analysis of intraoperative data revealed an average surgical time in the STD group of 124 minutes (minimum 85 min, maximum 155 min), while in the PSI group it was 126 minutes (minimum 97 min, maximum 190).

The mean number of fluoroscopic controls performed in the operating room in the STD group was 62.2 (min 50, max 75), in the PSI group it was 32.25 (18 min, 35 max); these data correspond to an average exposure time in the STD group of 60.6 seconds (min 41, max 76), while in the PSI group an average time of 32.06 sec (min 11, max 38).

In the PSI group, a single procedure associated with the implantation of the ankle prosthesis was performed in 62.5% of cases, in 25% of patients two associated procedures were performed and the remaining 12.5% of the prosthetic implants did not require the execution of associated procedures; in the STD group a single accessory time was performed in 60% of patients, in the remaining 40% there were two



Figures 10–11. Pre and post operative AOFAS subscore distinguished in the two groups (STD and PSI); Figure 10 reports the modifications of the sub score related to pain, Figure 11 express changes of the functional sub score.

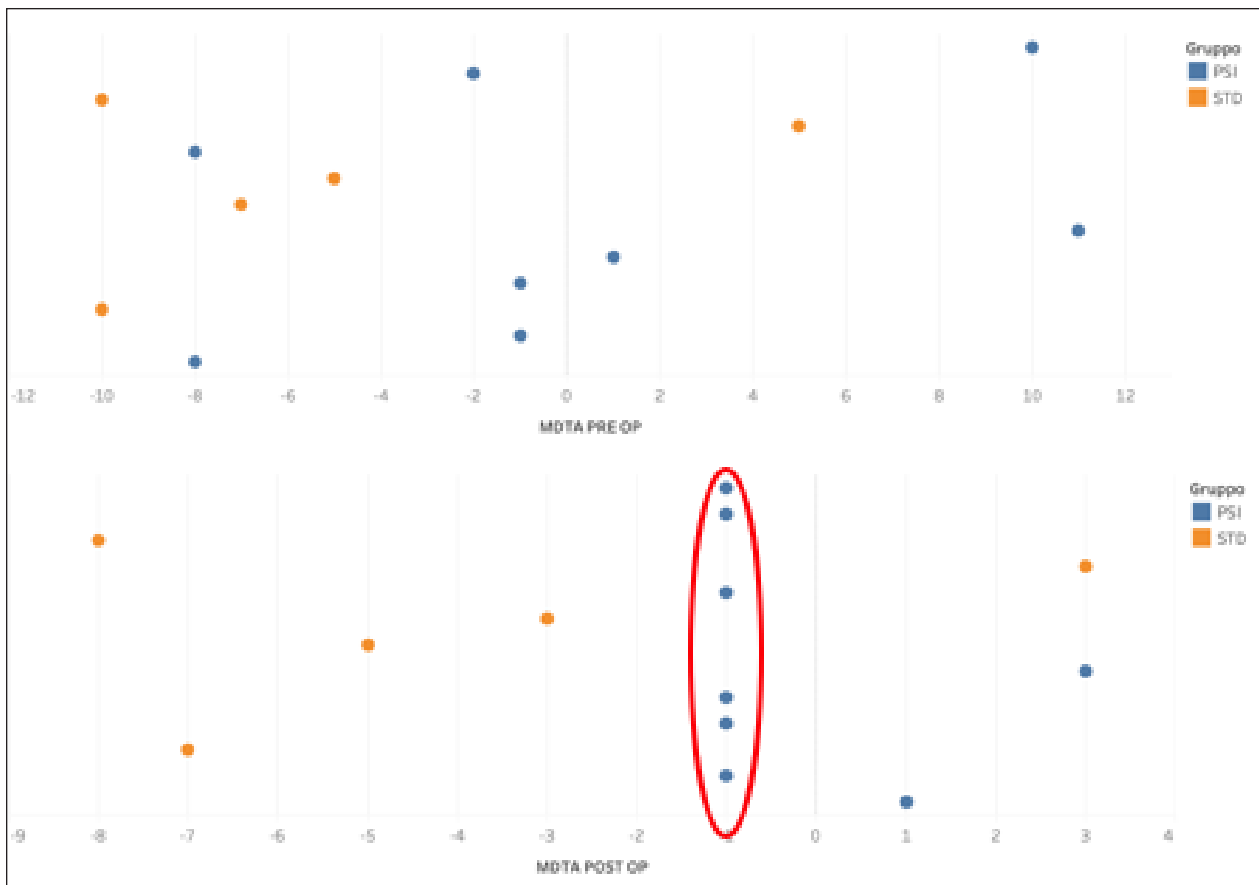


Figure 12A. represents the cumulative distribution of preoperative deformity (MDTA) in the two groups. Figure 12B. demonstrates post operative alignment of the tibial component; it is possible to highlight a lower dispersion in the PSI group (red circle) compared to the STD group.

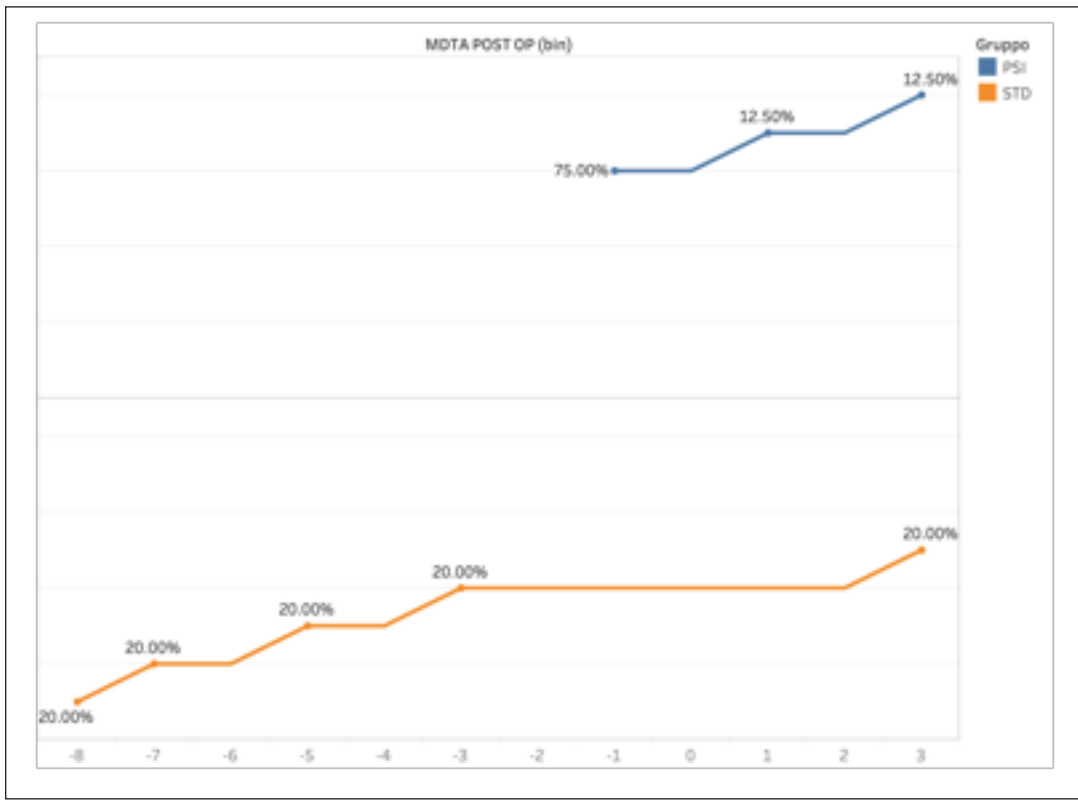


Figure 13. Frequency graph of post operative alignment; it is possible to point out that 87.5% of the patients belonging to the PSI group is within 1° of neutral alignment while in the STD group 40% of the patients achieved an alignment between +3 and -3° from neutral.

gestures associated with the implantation of the ankle prosthesis.

The gastrocnemius recession and the Z-lengthening of the Achilles tendon were performed overall in 94% of patients and were by far the most performed accessory surgical procedure in association with the implantation of the ankle prosthesis. In the PSI group, 87% of patients underwent an Achilles tendon lengthening or gastrocnemius recession, 12.5% underwent a subtalar arthrodesis, another 12.5% a removal of fixation devices and 25% of patients had immediately more than an accessory surgical gesture. In the PSI group, any additional procedures were performed only in one patient.

In the STD group, 80% of patients underwent gastrocnemius recession or Z-lengthening of the Achilles tendon, 40% with subtalar arthrodesis and 20% with syndesmosis stabilization; 20% of patients undergoing ankle replacement have undergone more than one

accessory surgery. No ankle prosthesis was performed in any patient without any additional surgical actions.

In regards with complications, a single serious complication was recorded in the perioperative period in a patient belonging to the PSI group (occlusion of the tibial vessels in the lower third of the leg); this complication involved revascularization by thrombectomy of the anterior distal tibial arteries and pedidia which were performed at the interventional radiology department of the same hospital (Fig. 59 and 60).

In regards with post-operative complications, two patients experienced mild complications associated with wound management (dehiscence secondary to superficial infection) which did not require additional surgical treatments but only serial dressings; this management led to proper wound healing in both cases. Patients who showed this complication each belonged to one of the two study groups.

Considering the patients of both groups, mild complications had an incidence of 13% and serious ones of 6%. No early onset of loosening, osteolysis or component rupture was detected in either patient of either group.

Discussion

Hip and knee arthroplasty are considered the surgical gold standard for the treatment of severe and symptomatic arthritis of these joints. Sub-optimal biomechanical results obtained from ankle fusion and the evolution of prosthetic ankle implants have made ankle arthroplasty a convenient and effective option for the treatment of symptomatic end-stage ankle arthritis. (46). Although ankle arthroplasty is still far from representing a therapeutic gold standard, the indications for its use are expanding and the implants carried out in the world are continuously increasing (45, 52).

The Infinity ankle arthroplasty used in the study represents one of the most frequent—last generation—two-component implant used; the English registry, which currently represents the largest ankle prosthetic registry in the world, revealed in its latest edition that the Infinity prosthesis was the implant most frequently performed (6).

Since its recent introduction on the market, the literature concerning the Infinity prosthesis is updated to a short-medium term follow-up (28, 29, 33, 47, 48) and our case series, with an average f.up inferior than two years, is no exception in this respect.

The number of patients undergoing ankle arthroplasty considered for the study is rather small; this aspect largely depends on the low epidemiological prevalence of the arthritis of the ankle in the general population. It has been previously reported that the sum of ankle fusion and ankle implants performed worldwide is approximately 24 times lower than knee implants alone.

A strong point of this work is represented by the fact that it is a case study of a single surgeon; this aspect differs from some previous multicentre case series in the literature that report the results obtained by different surgeons (33). This aspect is not insignificant considering that the implantation of an ankle prosthesis is considered a demanding surgery and characterized by a long and flat learning curve.

Although the two groups compared in the study (STD vs PSI) were small, the two groups had similar preoperative fetatures both from a clinical point of view (mean AOFAS score of 59 and 50.60 respectively) and from a radiographic point of view (mean preoperative deviation of 5.4° vs 2°). Furthermore, the two groups of patients were homogeneous for age (64 years old of average in both groups) and similar to that of other studies (32). These data agree with recent literature and emphasizes that the indication for ankle prosthesis no longer represents a surgical indication limited to older patients with poor functional demands (50).

With regards to the clinical measurement scale, the AOFAS score is the most used survey in the literature concerning ankle arthroplasty; nonetheless, there is little evidence concerning the use of the AOFAS in terms of reliability and interpretation in this type of surgery (44). Limitations in the AOFAS may be the presence of few answer options in some sub-categories or the evaluation of objective measures such as range of motion; the latter limitation represents a disadvantages in some categories of patients, such as those undergoing a contextual subtalar arthrodesis (SA); these patients, although they may be completely satisfied with the post-operative outcome obtained, lose 8 points in the AOFAS subcategory concerning function due to the fusion of the sub talar joint.

The analysis of the AOFAS denoted an improvement of 46.62% in the overall score between the pre and post operative measurements (**Figure 6**); this data reflects the good result perceived by the patient following the implantation of an ankle prosthesis. The increase in the AOFAS score, as expected, was not significantly different in the two groups of patients (**Figure 7**); this result is not surprising and could be the consequence of the short clinical follow-up and related to that the same ankle prosthesis was implanted in the two groups.

The detailed analysis of the normalized scores related to function and pain categories revealed a non-symmetrical improvement in the two categories; the normalized score values referring to the pain category showed an overall improvement of 66.67% between pre and post operative analysis (**Figure 8**) while in the category related to function an increase of the score of 32.19% (**Figure 9**). These data agree with various

studies in the literature: ankle prosthesis, although guarantee a certain degree of joint mobility, has a main effect on the resolution of painful symptoms rather than on the recovery of joint mobility. Furthermore, the simultaneous execution of a subtalar arthrodesis in 23% of patients undergoing ankle prosthesis implantation certainly contributed to this result.

The detailed analysis of the normalized scores related to function within the two groups also highlighted a similar post-operative percentage increase in the two groups (**Figure 11**): in detail, an increase of 34.48% in the PSI group and an increase of 30.92% in the STD group.

Conversely, the post-operative improvement in normalized pain score was different in the PSI group compared to the STD group (**Figure 10**); in detail, the PSI group showed an improvement of the normalized pain score of 75% compared to a lower increase of 62.5% in the STD group.

The inferior result on the resolution of pain in the STD group was attributed to the higher incidence of post-operative pain localized in the tibio-talar gutter; gutter impingement was the main cause of incomplete satisfaction of patients belonging to the STD group and this was in agreement with recent findings by Saito using the same prosthetic model (33). Analyzing the incidence of post-operative gutter impingement we revealed an incidence of 60% in patients belonging to the STD group; this data correlates with other studies that consider tibio talar impingement a complication of fixed-bearings ankle implants with an incidence that reaches 54% (33). None of the patients belonging to the PSI group showed gutter impingement symptoms post-operatively.

The impingement syndrome of the talar component in tibial and / or fibular gutter can have different etiopathogenesis: implant design, size of the talar component or of the polyethylene insert, presence of hypertrophic bone, valgus / varus thrust or malalignment of the components on the axial plane (34).

Patients suffering from gutter impingement underwent further diagnostic examination by computerized tomography (CT); ankle CT allowed to highlight in a patient belonging to the STD group an overhanging of the talar component due to an oversizing of the talar component (Figure 14).

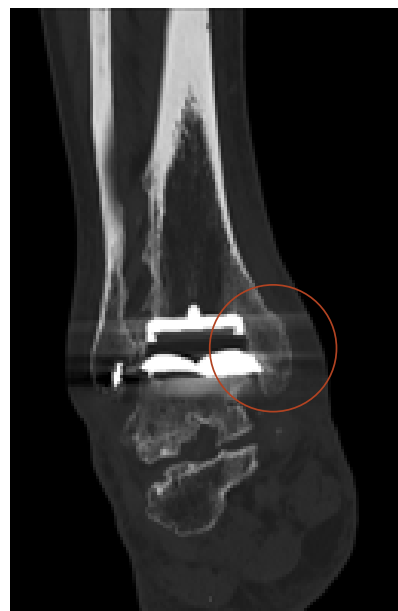

Figure 14. Postoperative ankle CT of a patient belonging to the STD group: the red circle point out the impingement on the medial malleolus do to an overhang of the talar component.

In the remaining patients belonging to the STD group and suffering from gutter impingement, CT scans did not allow to detect any other macroscopic reason of post operative impingement in the tibio talar gutters.

In these patients symptoms may depend on an uncorrect positioning of the components in the axial plane. This highly relevant topic is little known and is currently the subject of very recent clinical studies (35, 36, 37).

It is known that the axial rotation of the distal tibia is significantly variable due to degenerative disease of the ankle and tibial gutters, individual variability and the frequent post traumatic sequelae. Each prosthetic model has different orientation landmarks (e.g. the TTA, the II metatarsal bone...) for the positioning of the prosthetic components on the axial plane (36). Traditional instrumentation for the implant of the Infinity prosthesis rely on a guide positioned in the medial gutter to determine the rotation of the tibial component; on the contrary, the Prophecy system entrusts to pre-operative planning for the rotation in the axial plane of the tibial component which is aligned on the bisection

of the angle formed by the tangents to the medial and lateral malleoli (36).

The preoperative planning of the patients of the PSI group highlighted that the bisection of the angle formed by the tangents to the medial and lateral for-nixes had a variability up to 10° (min 2° , max 12.1°) (**figure 15**); it is therefore clear that such variability does not allow to standardize the positioning of the tibial component in the axial plane.

Similarly, the preoperative planning showed an elevated variability of the position of the tibial component in regard to a fixed anatomical landmark as the II metatarsal bone; using this landmark, we could demonstrate a variability of the position of the tibial component from 0.9° to 29.3° in relation to the position of the foot (**Figure 16**).

Supporting our findings, a study by Najefi in 2019 showed that in a series of patients undergoing Infinity ankle arthroplasty implantation with STD instrumentation after carrying out a planning with the Prophecy, the tibial component would be positioned in over 50% of patients with more than 5° of internal rotation compared to what was previously planned by the PSI (36). The same work reports how the use of the PSI system has reduced the post operative incidence of gutter impingement.

Fixed bearing ankle prosthesis—such as the Infinity – require a correct orientation in the axial plane of the components to reduce a potential cause of gutter impingement.

Hinterman demonstrated the considerable inter-individual intra and postoperative variability existing

in the reciprocal positioning between the tibial component and the polyethylene using a mobile bearing prosthesis (35); this study revealed the impossibility of identifying a technique that relies on standardized landmarks to determine the rotation of the components in the axial plane.

This aspect is particularly relevant in the positioning of a fixed-bearing prosthesis in which the implantation of the tibial component influences the axis of rotation of the talus (35, 37). On the contrary, using a three-component prosthesis, the mobile insert allows

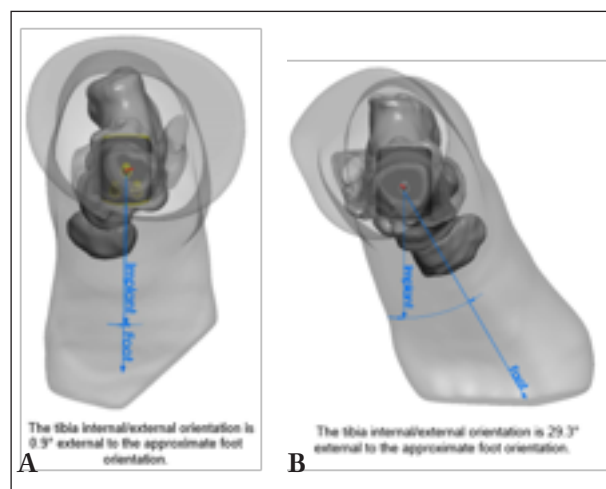


Figure 16. High variability of the axial positioning of the tibial component in regards to the orientation of the foot (II metatarsal bone): from 0.9° (**A**) to 29.3° (**B**) of external orientation.

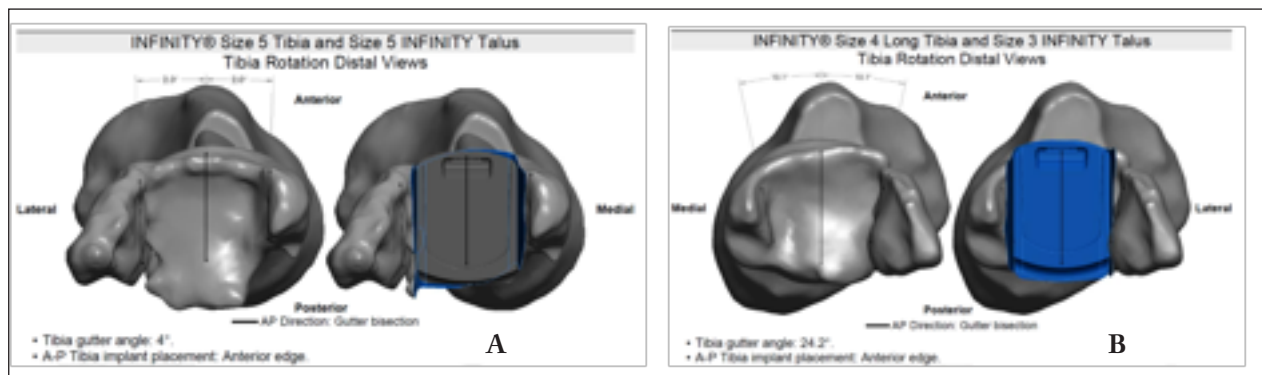


Figure 15. Preoperative planning of two patients belonging to the PSI group demonstrate the high variability on the rotational alignment of the tibial component in regard with the bisection of the tibia gutter angle: 2.0° in picture **A** vs 12.1° in picture **B**.

to compensate for any misalignment of the prosthetic components in the axial plane (36).

In a recent study by Gagne (37) it was reported that the mean rotation difference of the tibial component between PSI and STD instrumentation was 7.5° (77% of patients had a rotation difference relying on the two different instruments between -4° and $+4^\circ$ with respect to the preoperative planning); in a similar manner Najefi (36) found a difference between the two instrumentation between 1.7 and 9.4° ; these data are surprising considering that these wide variations concern the implantation of the the same prosthetic components. In the same study, the transition from a traditional instrumentation to a PSI instrumentation resulted in a decrease of gutter impingement around 1.9% with an average value in the literature of 7% (36).

In this regard, it is therefore not surprising that patients suffering from a painful symptomatology of the tibio talar fornix belonged in 100% of cases to the STD group and that this complication was not detected in any patient of the PSI group.

Post operative gutter impingement syndrome required a reoperation in two patients; in one case a revision of the talar prosthetic component was performed while in the second a debridement of the medial and lateral tibial fornix was performed.

A routinary debridement of the tibio talar fornixes at the time of ankle replacement is not considered a viable option since it potentially leads to joint instability, weakening of the malleoli and loss of bone stock if performed in an aggressive manner (**Figure 17**).

This study has shown an excellent predictivity of the Prophecy on the prosthetic size; at the tibial level, a 100% correspondence was found between the planned size and the implanted size, while at the talar level the correspondence was 80%. The accuracy of the PROPHECY system in predicting the prosthetic size is a topic of discussion in recent works; unlike what Saito reported (3), our experience with PSI appears to be completely comparable to what Daigre described with a predictivity for the tibial component of 98% and for the talar component of 80% (32). Most of the studies agree that the poorest prediction on the talar component rather than on the tibial depends on the greater or lesser aggressiveness in carrying out the debridement of the tibio talar gutter.

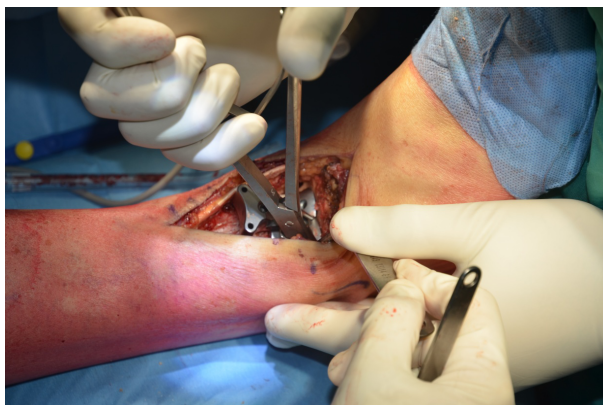

Figure 17. Intraoperative photograph represents a debridement of the tibial talar gutter; this surgical gesture, although it could potentially reduce the incidence of gutter impingement, it is not considered free from complications.

In regard to the accuracy on the positioning of the tibial component with respect to the desired neutral axis, the PSI group of this study presented a better accuracy and greater implant reproducibility than the STD group; these data differs from that reported by recent works in which the PROPHECY system has not shown any advantages in this sense compared to traditional alignment instruments (3, 29, 32).

The analysis of the distribution of post-operative alignments (**Figure 12B**) highlights a clear lower dispersion of the results of the PSI group compared to those of the STD group; in addition to a lower dispersion, the data relating to the alignment of the tibial component in the PSI group were very close to the neutral alignment, in particular considering that the numerical values have been rounded up. The analysis of the frequency graph of post-operative alignment (**Figure 13**) was in fact within 1° of neutral alignment ($+1^\circ$, -1°) in 87.5% of patients and within 3° of optimal neutral alignment in 100% of patients in the PSI group. In the STD group, on the contrary, only 40% of patients achieved an alignment included between $+3^\circ$ and -3° from the neutral alignment; the graph relating to the distribution of the alignment in the STD group highlighted a more variable distribution compared to that of the PSI group.

Although the data obtained allow us to confirm that the PROPHECY guarantees a reliable and reproducible ankle prosthesis implantation (32), the small

number of the sample and the short follow-up do not allow us to draw conclusions about the greater chances of survival of a system aligned in an optimal way compared to one more deviated from a neutral alignment.

Overall, the analysis of intraoperative data confirms what has already been shown by other preliminary studies on the use of PSI in ankle arthroplasty (3, 30, 32).

Unlike what was expected, the average surgery time was not significantly lower in the PSI group than in the STD group (126 vs 124 min) and this probably in relation to the accessory surgical procedures simultaneously performed with the implantation of the ankle prosthesis.

However, by analyzing the surgical times of prosthetic implantation without considering the accessory times, the data are in line with what is described in the literature (53) and the minimum implant time in the PSI group was 65 min while in the STD group it was

85 min. These data are confirmed by the cumulative frequency graph relating to the duration of the intervention (**Figure 18A**): if a target of implantation of 120 min is considered, the graph shows that 87% of patients in the PSI group fall within this time while in the STD group only 40% of patients are included.

The data relating to the use of the image intensifier agree with what has already been reported in the literature (3): the PSI technique requires an absolute lower number of scopes than the STD technique and this correlates with both a reduction of fluoroscopy times and with exposure to ionizing radiation. In absolute terms, the number of scopes in the PSI group was about half of the STD group (32.25 vs 62.2) with an obvious decrease in the total radiation emitted (399.37 vs 531.4 Mgc^{m2}). The analysis of the cumulative frequency graph by number of scopes underlines these data (**Figure 18B**): with a supposed threshold of 40 scopes, we demonstrated that 100% of patients in the

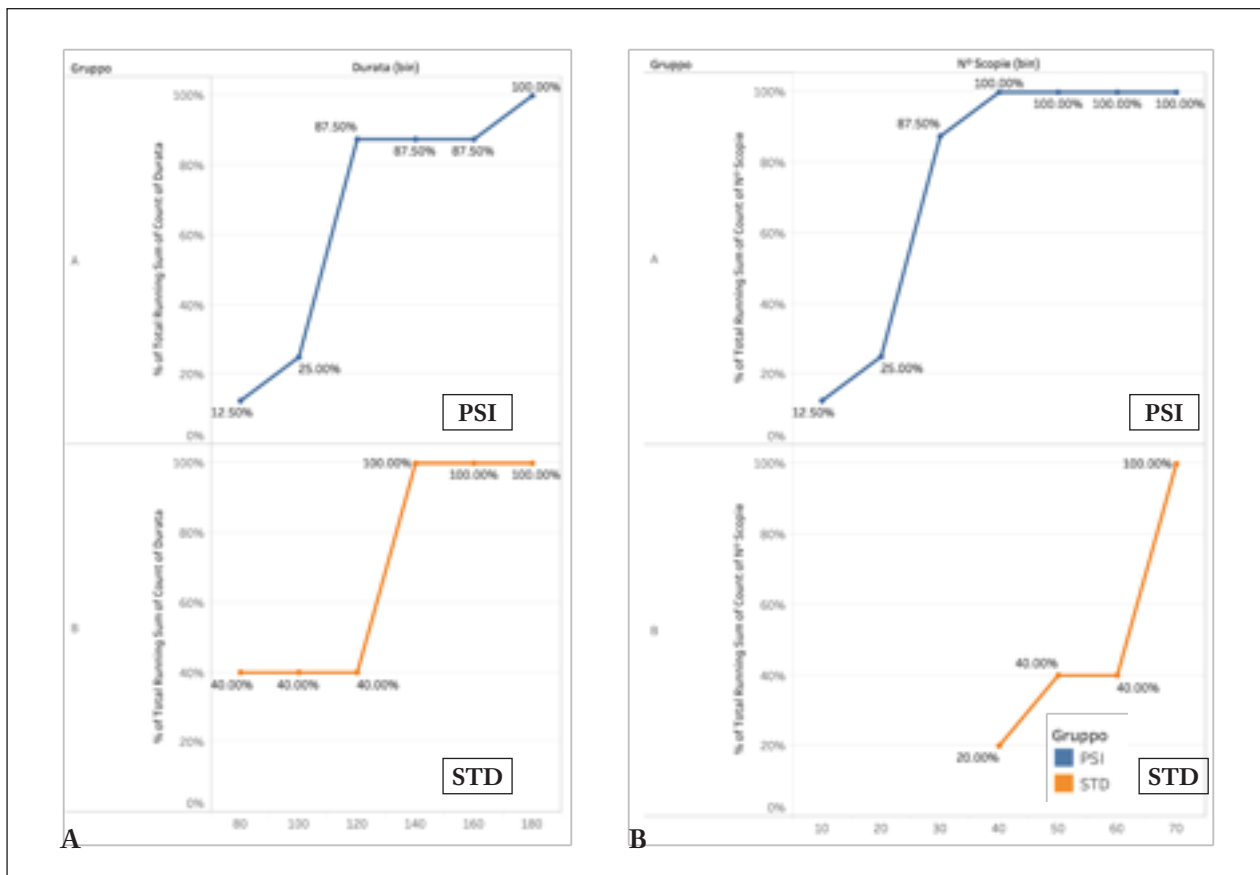


Figure 18A. Frequency graph related to surgical times: the blue line belongs to the PSI group while the yellow line appertains to the STD group. **Figure 18B.** is the frequency graph related to the number of scopes in the two groups.

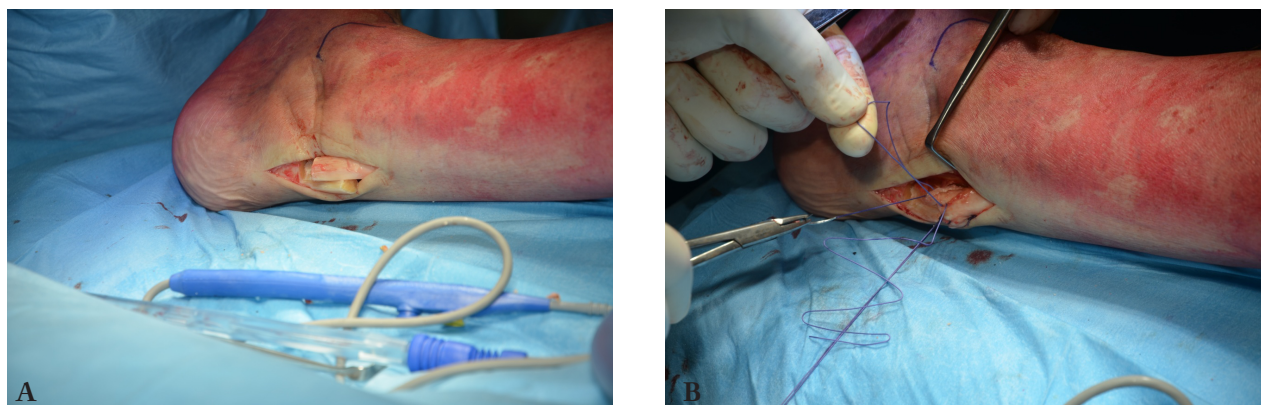

Figure 19. Intraoperative photograph of the Z lengthening (A) and of the suture of the Achilles tendon (B)/.

PSI group were below this limit while only 20% of patients belonging to the STD group fall within this threshold.

By far the most performed accessory surgical procedure (overall in 96% of patients) was the release of the posterior compartment (Achilles tendon lengthening – **Figure 19**—or gastrocnemion recession); this finding agrees with that reported with other studies that used the same prosthesis (28, 47, 48) and denotes the importance of soft tissues for balancing range of motion and ankle stability after ankle replacement

Although the only serious complication was recorded in the PSI group, this occurrence does not appear to be related to the instrumentation and did not affect the outcome of the surgery.

Overall, 87% of patients did not require a re-surgery after the implantation of the ankle prosthesis while 13% required a second surgical procedure which in 6.5% of cases involved the revision of a component and in the remaining 6.5% required a joint debridement; we haven't detect any early mobilization or breakage of the polyethylene insert (55). These data appears in line with a recent study performed by Rushing in which he described the results in series of Infinity ankle replacement at a short follow-up of 1.8 years (28); our data agree also with regard to the survival of the prosthetic components (93.5% in our series vs 98% in that of Rushing). These results appear more reassuring compared with recent findings by Cody (48) with a loosening rate of the tibial component of 3.8%

at 13 months and with an appearance of periprosthetic tibial radiolucencies of 7.4% at one year; the better survival at a short follow-up of the implants in our study can correlate with the accuracy of implantation of the components achieved: this aspect is a fundamental part in the use of a low-profile prosthesis such as the Infinity as previously pointed out by Haddad (54).

Conclusion

Despite the limitations related to the short duration of the follow up and the small size of the sample, it is possible to confirm that the Infinity ankle prosthesis represents a safe and effective surgical treatment for the replacement of end-stage and symptomatic ankle arthritis.

The AOFAS score normalized by category, with the intrinsic limitations related to the use of this survey in ankle replacement, permitted to reveal that patient satisfaction in the post-operative period correlate more with the decrease of pain rather than with functional recovery.

The implantation of the Infinity ankle prosthesis with the PSI—PROPHECY—system has demonstrated to be more accurate and reproducible than the implantation of the same prosthesis with traditional instrumentation. Longer follow-up studies are needed to detect whether higher accuracy in component placement correlates with longer implant survival;

this aspect is also relevant in order to justify the higher costs incurred deriving from a patient specific technology.

In spite of other studies, few complications were found in the present work. Prosthetic impingement in the tibio-talar gutter represents the most frequent short to medium term complication and is correlated, in the absence of other detectable causes, to an axial misalignment of the tibial component; the PSI has drastically reduced the incidence of this complication compared to the STD instrumentation thanks to the study of the patient's anatomy and the planning of the position of the components.

With the Infinity prosthesis associated with the PROPHECY system, a safe and effective ankle prosthetic replacement system has been introduced on the market; correct surgical indication, surgeon's experience and the reliability of the latest generation implants could lead ankle arthroplasty to achieve the results of hip and knee replacement.

For all the above advantages, it is possible to state that the PSI could allow an extension of the indication to the implantation of an ankle prosthesis even to patients suffering from osteoarthritis of the ankle with more marked deformity, still today a relative contraindications for this type of surgery (30).

Acknowledgements

PG thanks Dr Ida Giardini for her impressive work in making the statistical analysis and the graphic processing of the data; PG would also like to thank all the other Authors whose work in his years of Residency made this project a reality.

Conflict of Interest: Each author declares that he or she has no commercial associations (e.g. consultancies, stock ownership, equity interest, patent/licensing arrangement etc.) that might pose a conflict of interest in connection with the submitted article

References

1. Le V, Veljkovic A, Salat P, Wing K, Penner M, Younger A. Ankle Arthritis, *Foot & Ankle Orthopaedics* 2019; 4 (3): 1-16
2. Barg A, Amendola A, Beaman N, Saltzman L. Ankle Joint Distraction Arthroplasty: Why and How? *Foot and Ankle-Clin N Am* 2013; 18: 459-470
3. Lawton D, Butler A, Dekker G, Prescott A, Kadakia R. Total ankle arthroplasty versus ankle arthrodesis – a comparison of outcomes over the last decade, *Journal of Orthopaedic Surgery and Research* 2017; 86: 12:76
4. Pedowitz D, Kane JM, Smith GM, Saffell HL, Comer C, Raikin SM. Total ankle arthroplasty versus ankle arthrodesis, *The Bone and Joint Journal* 2016; 98 B: 634-40
5. Shane A, Sahli H. Total Ankle Replacement Options, *Clin Podiatr Med Surg* 2019; 36: 597-607
6. Jeyaseelan L, Park S-H, Al-Rumaih H, Veljkovic A, Penner J, Younger A. Outcomes Following Total Ankle Arthroplasty – A Review of the Registry Data and Current Literature, *Orthop Clin N Am* 2019; 50: 539-548
7. Aicale R, Maffulli N. Lower limb joint repair and replacement: an overview, *F1000 Research* 2019; 8: 2122
8. Cody A, Scott J, Easley E. Total Ankle Arthroplasty – A Critical Analysis Review. *Journal of Bone & Joints Surgery* 2018; 6 (8): e8
9. Lord G, Marotte JH. Total Ankle Prosthesis. Techniques and first results. Apropos of 12 cases, *Rev Chir orthop Reparatrice Appar Mot*, 1973, 39, 139-151
10. Lord G, Marotte JH. Total Ankle Replacement, *Rev Chir orthop Reparatrice Appar Mot*, 1980, 66, 527-530
11. Vickerstaff J.A, Miles W, Cunningham L. A brief history of total ankle replacement and a review of the current status, *Medical Engineering & Physics* 2007; 29: 1056-1064
12. Sodha S, Wei Y, Okereke E. Evolution of Total Ankle Arthroplasty, *The University of Pennsylvania Orthopaedic Journal* 2000; 13: 18-21
13. Yu J, Sheskier S. Total Ankle Replacement: Evolution of the Technology and Future Applications, *Bull Hosp Jt Dis*. 2014; 72(1): 120-8
14. Saltzman L, Salamon L, Blanchard M et al. Epidemiology of ankle arthritis: report of a consecutive series of 639 patients from a tertiary orthopaedic center, *Iowa Orthop J* 2005; 25: 44-46
15. Glazebrook M, Daniels T, Younger A. Comparison of Health-Related Quality of Life Between Patients with End-Stage Ankle and Hip Arthrosis, *J Bone Joint Surg Am*. 2008; 90: 499-505
16. Desai J, Glazebrook M, Penner J et al. Quality of Life in Bilateral Vs. Unilateral End-Stage Ankle Arthritis and Outcomes of Bilateral Vs. Unilateral Total Ankle Replacement, *J Bone Joint Surg Am*. 2017; 99(2): 133-140
17. Thomas H, Daniels R. Ankle Arthritis, *The Journal of Bone & Joint Surgery* 2003; 85: 923-936
18. Thomas C, Hubbard-Turner T, Wikstrom A, Palmieri-Smith M. Epidemiology of Posttraumatic Osteoarthritis, *J Athl Train*. 2017; 52(6): 491-496.
19. Valderrabano V, Horisberger M, Russell I, Dougall H, Hintermann B. Etiology of Ankle Osteoarthritis, *Clin Orthop Relat Res* 2009, 467: 1800-1806

20. Merrill K, Ferrandino M, Hoffman R, Ndu A, Shaffer W. Comparing 30-day all-cause readmission rates between tibiotalar fusion and total ankle replacement, *Foot and Ankle Surgery* 2019; 25(3): 327-331
21. Ewalefo O, Dombrowski M, Hirase T et al. Management of Posttraumatic Ankle Arthritis: Literature Review, *Current Reviews in Musculoskeletal Medicine* 2018; 11: 546-557
22. Michael A. Gentile. Nonsurgical Treatment of Ankle Arthritis, *Clin Podiatr Med Surg.* 2017; 34: 415-423.
23. Goldberg J, Zaidi R, Thomson C et al. Total ankle replacement versus arthrodesis (TARVA): protocol for a multi center randomised controlled trial, *BMJ Open.* 2016; 6: e012716.
24. Muller P, Skene S, Chowdhury K, Cro S, Goldberg J, Doré J. A randomised, multi-centre trial of total ankle replacement versus ankle arthrodesis in the treatment of patients with end stage ankle osteoarthritis (TARVA): statistical analysis plan, *Trials.* 2020; 18; 21(1): 197.
25. Chopra V, Stone P, Ng A. Supramalleolar Osteotomies, *Clin Podiatr Med Surg* 2017; 34: 445-460.
26. Barp A, Erickson G, Hal L. Arthroscopic Treatment of Ankle Arthritis, *Clin Podiatr Med Surg* 2017; 34: 433-444.
27. Labib A, Raikin M, Lau T et al. Joint preservation Procedures for Ankle Arthritis, *Foot Ankle Int* , 2013; 34: 1040-7.
28. Rushing J, Kibbler K, Hyer F, Berlet C. The Infinity Total Ankle Prosthesis—Outcomes at Short-Term Follow-Up, *Foot Ankle Spec.* 2020; 8: 1938640020946199.
29. King A, Bali N, Kassam A., Hughes A., Talbot N., Sharpe I. Early outcomes and radiographic alignment of the Infinity total ankle replacement with a minimum of two year follow-up data, *Foot Ankle Surg.* 2019; 25(6): 826-833.
30. Waly J, Yeo E, Penner J. Computed navigation Guidance for Ankle Replacement in the Setting of Ankle Deformity, *Clin Podiatr Med Surg.* 2018;35(1): 85-94
31. Leighab M, Janicka P, Andorno S, Marcuzzi A, Magnani C, Grassi F. Italian translation, cultural adaptation and validation of the “American Orthopaedic Foot and Ankle Society’s (AOFAS) ankle-hindfoot scale”, *Acta Biomed.* 2016; 6; 87(1): 38-45
32. Daigre J, Berlet G, Van Dyke B, Peterson S, Santrock R. Accuracy and Reproducibility Using Patient-Specific Instrumentation in Total Ankle Arthroplasty, *Foot Ankle Int.* 2017; 38(4): 412-418.
33. Saito H, Sanders E, Netto C, O’Malley J, Ellis J, Demetracopoulos A. Short-Term Complications, Reoperations, and Radiographic Outcomes of a New Fixed-Bearing Total Ankle Arthroplasty, *Foot Ankle Int.* 2018; 39(7): 787-794
34. Schubert J, Wood A, Christensen C. Gutter Impingement in Total Ankle Arthroplasty, *Foot Ankle Spec.* 2016; 9: 145-58
35. Hintermann B, Susdorf R, Krahenbuhl N, Ruiz R. Axial Rotational Alignment in Mobile-Bearing Total Ankle Arthroplasty, *Foot & Ankle International* 2020, Vol. 41: 521-528
36. Najefi A, Ghani Y, Goldberg A. Role of Rotation in Total Ankle Replacement, *Foot Ankle Int.* 2019; 40: 1358-1367
37. Gagne J, Veljkovic A, Townshed D, Younger A, Wing J, Penner J. Intraoperative Assessment of the Axial Rotational Positioning of a Modern Ankle Arthroplasty Tibial Component Using Preoperative Patient-Specific Instrumentation Guidance, *Foot Ankle Int.* 2019; 40: 1160-1165
38. Kraus VB, Kilfoil TM, Hash TW et al, Atlas of radiographic features of osteoarthritis of the ankle and hindfoot, *Osteoarthritis and Cartilage* 23 (2015) 2059-2085
39. Gougoulas E, Khanna A, Maffulli N. History and evolution in total ankle arthroplasty, *Br Med Bull.* 2009; 89: 111-51
40. Barg A, Wimmer M, Wieworski M, Wirtz C, Pagensert I, Valdeerrabano V. Total Ankle Replacement, Indications, Implant Designs, and Results, *Dtsch Arztebl Int.* 2015; 112: 177-84.
41. Omar M, Abboud F, Youngner M. Imaging of Total Ankle Arthroplasty: Normal Imaging Findings and Hardware Complications, *Semin Musculoskelet Radiol* 2019; 23: 177-194
42. Wilkinson H, Rowbotham L, Grainger J. Imaging in Foot and Ankle Arthritis, *Semin Musculoskelet Radiol.* 2016; 20: 167-74
43. Cody A, Lachman R, Gausden B, Nunley A, Easley E, Lower Bone Density on Preoperative Computed Tomography Predicts Periprosthetic Fracture Risk in Total Ankle Arthroplasty, *Foot Ankle Int.* 2019; 40 (1): 1-8
44. Naal D, Impellizzeri M, Rippstein S. Which Are the Most Frequently Used Outcome Instruments in Studies on Total Ankle Arthroplasty? *Clin Orthop Relat Res.* 2010; 468(3): 815-26.
45. Rodriguez-Merchan E, Moracia-Ochagavia I. Total Ankle Arthroplasty: long-term Survival and factors that Influence it, *Int. J. Of Orth.* 2019; 6 (4): 1124-1128
46. Reeves L, Shane M, Vazales R. Current Concepts Regarding Total Ankle replacement as a Viable Treatment Option for Advanced Ankle Arthritis. What You Need to Know, *Clin Podiatr Med Surg.* 2017; 34: 515-527
47. Penner M, Davis W, Wing K, Bemenderfer T, Waly F, Anderson B. The Infinity Total Ankle System, Early Clinical Results With 2—to 4 – Year Follow-up, *Foot Ankle Spec.* 2019; 12 (2): 159-166
48. Cody A, Taylor A, Nunley A, Parekh G, DeOrio K. Increased early revision rate With the INFINITY Total Ankle Prosthesis, *Foot Ankle Int.* 2019; 40 (1): 9-17
49. Editorial Board of Foot & Ankle International, Total Ankle Arthroplasty: Minimum Follow-up Policy for Reporting Results and Guidelines for Reporting Problems and Complications Resulting in Reoperations, *Foot Ankle Int* 2017; 38(7): 703-704
50. Lee G-W, Seon J-K, Kim N-S, Lee K-B. Comparison of Intermediate-term Outcomes of Total Ankle Arthroplasty in Patients Younger and Older Than 55 Years. *Foot Ankle Int* 2019; 40(7): 762-768.
51. Saltzman et al, Impact of comorbidities on the measurement of health in patients with ankle osteoarthritis, *J Bone Joint Surg [Am]*2006; 88-A: 2366-2372.

52. Law T, Sabeih G, Rosas S, Hubbard Z, Altajar S, Roche W. Trends in total ankle arthroplasty and revisions in the Medicare database, *Ann Transl Med* 2018; 6(7): 112
53. Hamid S, Matson P, Nwachukwu U, Scott J, Mather C, DeOrio K. Determining the Cost-savings threshold and Alignment Accuracy of patient-Specific Instrumentation in Total Ankle Replacements, *Foot Ankle Int* . 2017; 38 (1): 49-57.
54. S. L. Haddad, Letter regarding: Increased Early Revision rate With the INFINITY Total Ankle Prosthesis, *Foot Ankle Int*. 2019; 40 (1): 124-126.
55. Anugraha A, Pillai A. The CT gap sign, a case of failure to seat the polythene componnet in total ankle replacement (infinity), *J Surg Case Rep*. 2020 Mar 24; 2020(3): rjz363.

Correspondence:
Received: 27 October 2020
Accepted: 23 November 2020
Piero Giardini, MD
Department of Orthopaedic Surgery,
Fiemme Hospital
Via Dossi 21
Cavalese (TN), 38033 Italy
Phone: +39 3405566971
E-mail: piero.giard@gmail.com