

Laparoscopic partial splenectomy using the harmonic scalpel for parenchymal transection: two case reports and review of the literature

Davide Di Mauro, Angelica Fasano, Mariannita Gelsomino, Antonio Manzelli

Royal Devon and Exeter NHS Foundation Trust, Department of Upper GI Surgery, Exeter, United Kingdom

Abstract. Laparoscopic splenectomy is nowadays widely performed for the treatment of benign and malignant diseases of the spleen. However, removing the spleen increases the risk of postoperative infections, therefore patients need long-life antibiotics. Advancement in surgical technique and instrumentation have led to the development of partial splenectomy, which is mainly indicated to treat localized lesions of the spleen. The main advantage is the preservation of the immune function, so that long-life prescription of antibiotics is no longer needed. The introduction of the laparoscopic approach to laparoscopic splenectomy seems to add further benefits, namely a faster recovery. We report two cases of benign splenic cysts, which were treated by laparoscopic partial splenectomy. Technical aspects on the parenchymal transection and data from the most recent literature are discussed as well. (www.actabiomedica.it)

Key words: Laparoscopic splenectomy, partial splenectomy, splenic cyst

Introduction

Elective laparoscopic splenectomy has gained widespread popularity among surgeons (1-3). The advantages of the mini-invasive approach over the open surgery include better anatomical view, reduced postoperative pain and prompt patient's recovery (4). However, removing the spleen increases the risk of overwhelming post-splenectomy infections (OPSI) and thrombophilia (5,6). The growing knowledge of splenic physiology and the advancement in surgical techniques has led to the development of partial splenectomy. The preservation of viable splenic tissue maintains the immune response against encapsulated bacteria like *Streptococcus Pneumoniae*, *Haemophilus Influenzae* and *Neisseria Meningitidis* (7). The procedure can be performed laparoscopically, adding the advantages of the mini-invasive approach (8).

We report two cases of laparoscopic partial splenectomy (LPS). Data review of recent literature is described as well.

Case Report

Case 1

A 35-year-old woman with unspecific, mild discomfort in the upper abdominal quadrants underwent an abdominal ultrasound scan (USS), in 2012. The scan showed a 4.4 cm anechoic rounded area in the superior pole of the spleen, in keeping with a simple cyst. Since patient's symptoms were not deemed to be related to the cyst, she was enrolled in a 2-year USS follow-up. On the repeat scan, the cyst grew up to 6.9 cm, but the patient did not report any symptom.

Therefore, a conservative management was advocated. Two years later, the new onset of left upper quadrant pain prompted a computed tomography (CT) scan of the abdomen. The CT confirmed the presence of a simple cyst, sized 11.8 x 11 x 12.5 cm, displacing the left kidney inferiorly (Figures 1a, 1b). Serology for Echinococcus was negative. The indication for surgery was discussed with the patient, who underwent LPS. No intraoperative blood loss was recorded. The early postoperative course was uneventful and the patient was discharged 2 days after surgery. No antibiotics were prescribed. Histopathology demonstrated an epithelial cyst of the spleen. A follow-up abdominal ultrasound was performed 14 months after surgery; it showed no abnormalities in the spleen and the patient remained asymptomatic.

Case 2

A 26-year-old woman complaining of left upper abdominal pain underwent an abdominal USS, in 2014. The scan reported the presence of a 15.6 cm x 12 cm x 12 cm anechoic area, with well-defined margins, in the left upper quadrant. The lesion displaced the pancreas to the right of the midline, the left kidney and the spleen downwards towards the left lower quadrant. An abdominal CT scan confirmed the finding of a simple

cyst arising from the superior pole of the spleen, measuring 13.5 x 12 x 12 cm. Serology for Echinococcus was negative. Surgical indications were discussed with the patient, who underwent LPS. No intraoperative blood loss was recorded. The early postoperative course was uneventful and the patient was discharged 2 days after surgery. No antibiotics were prescribed. Histopathology demonstrated an epithelial cyst of the spleen. A follow-up abdominal ultrasound was performed 14 months after surgery; it showed no abnormalities in the spleen and the patient remained asymptomatic.

Surgical Technique

Both the patients received a triple vaccination for Streptococcus Pneumoniae Type B, Haemophilus Influenzae and Neisseria Meningitidis. LPS was performed with the patient in the 45 degrees right lateral decubitus, using 4 trocars. After the splenocolic ligament is transected, the short gastric vessels are divided with the harmonic scalpel. Subsequently the upper polar vessels are divided between clips at the hilum (Figures 2a, 2b). After the selective vascular ligation is achieved, the splenic parenchyma within that vascular territory becomes ischemic, showing a “mulberry-like”

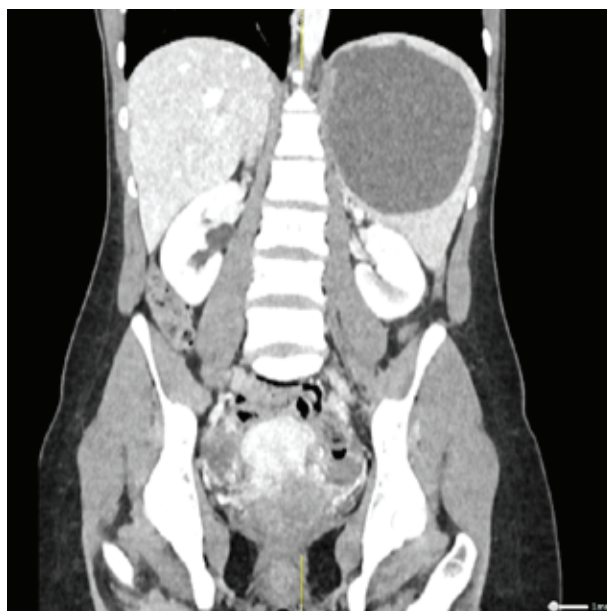


Figure 1a. Computerized Tomography of the abdomen (coronal view).

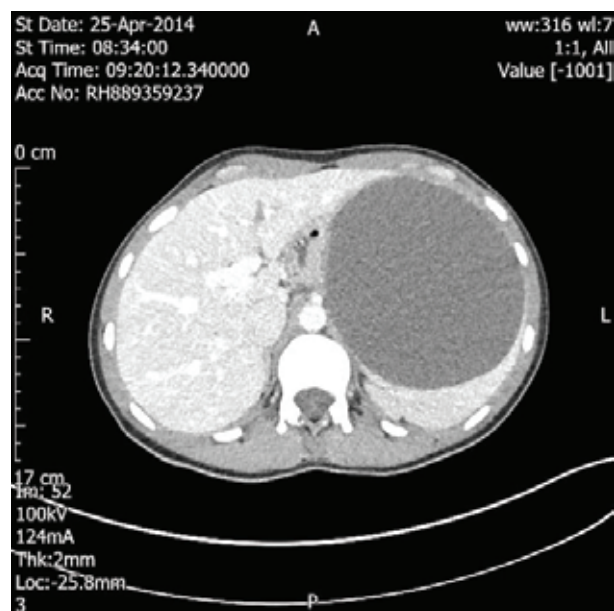


Figure 1b. Computerized Tomography of the abdomen (axial view).

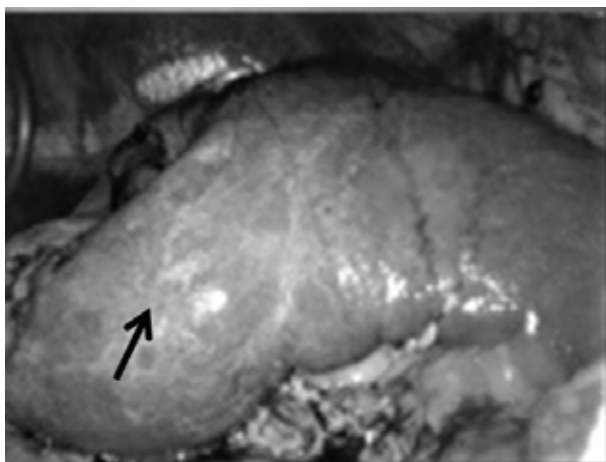


Figure 2a. Intraoperative view of the splenic cyst (arrow).

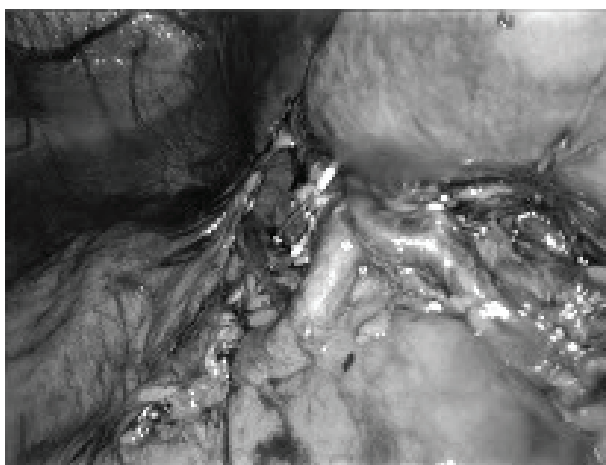


Figure 2b. Selective ligation of the superior vascular pedicle.

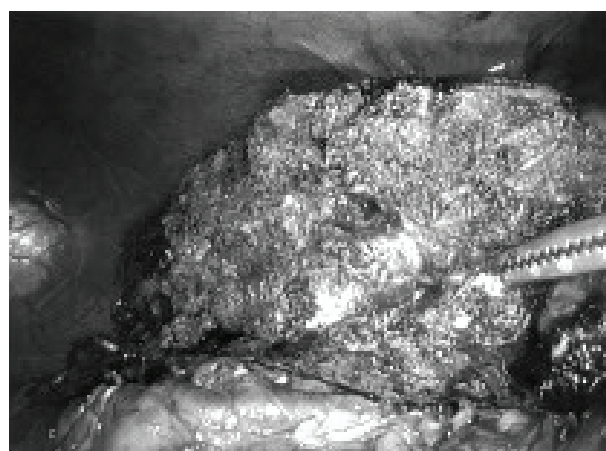


Figure 3. Splenic remnant after parenchymal transection

color (9,10). The parenchymal transection is carried out at the demarcation line between the ischemic and non-ischemic parenchyma, using the harmonic scalpel (Figure 3). Haemostasis of the splenic remnant is achieved with fibrin glue. The spleno-renal ligament is then taken down to allow the specimen extraction. Retrieval is accomplished by widening the port site incision in the left upper quadrant to 4 cm, without morcellation or cyst aspiration.

Discussion

Elective splenectomy is indicated in several conditions, including cysts, abscess and neoplasms of the spleen. In the asplenic patient, thrombocytosis and reduced immune-competency are well recognized conditions. Hence, although there is still debate about that, splenectomy can potentially lead to thromboembolic events, arteriosclerosis and pulmonary hypertension (5). Moreover, despite the routine preoperative vaccination and the life-long postoperative use of antibiotics, the risk of post-surgical OPSI remains a major concern (9).

The first case series of partial splenectomy was published in 1994 by Uranüs (10). Preserving at least 25% of well-perfused splenic parenchyma, maintains the organ immune function and reduces the incidence of postoperative thromboembolic events (11,12). Moreover, it has been reported that the remaining splenic tissue grows again in the first year following surgery (13,14). Since then, the laparoscopic approach to partial splenectomy has been introduced and reports showed good outcomes of LPS for localized non-haematologic splenic diseases; in particular, LPS yields less postoperative discomfort, shorter hospital stay and better cosmetic results, when compared to open surgery (15).

In the cases we presented, the indication for surgery was a symptomatic simple cyst. Although splenic cysts can be safely treated with laparoscopic deroofing, such a procedure is associated with a disease recurrence rate of up to 33% (16); in the light of that, LPS was the authors' preferred technique. Published series seem to confirm that (17, 18), while less frequently benign splenic tumors represent another indication for LPS (Table 1). Several reports in the literature support the

Table 1. Published data on laparoscopic partial splenectomy (LPS)

	Indication	Age	Gender	Surgical technique	Postoperative course	Outcome
Ho ⁸	Cyst	19	F	Vascular control with endoscopic stapling device	Uneventful postoperatively. Hospital stay: 2 days	Follow-up: 30 months, no recurrence
Wang ¹²	Lymphangioma	51	F	Parenchymal transection with RFA [†]	Uneventful postoperatively. Hospital stay: 7 days	Follow-up: 3 months, no recurrence. Normal platelets count
Iimuro ¹⁶	Cyst	23	F	LPS and cyst unroofing	Uneventful postoperatively	Follow-up: 6 months, no recurrence.
Fan ¹⁷	Cyst	30	M	LPS	Uneventful postoperatively	Follow-up: 12 months, no recurrence. Normal platelets count
Hong ¹⁹	Cyst	20	M	Single-port technique. Parenchymal transection with ultrasonic scissors and electrocautery device	Uneventful postoperatively. Hospital stay: 4 days	Follow-up: 6 months, no recurrence.
Dudi-Venkata ²⁰	Cyst	19	F	Parenchymal transection with RFA [†]	Uneventful postoperatively. Hospital stay: 4 days	Follow-up: 1 month, no recurrence.
Dudi-Venkata ²⁰	Cyst	56	F	Parenchymal transection with rigid resectoscope and electro-coagulation	Uneventful postoperatively. Hospital stay: 4 days	Follow-up: 1 month, no recurrence.
Okano ²¹	Haemangioma	37	M	Hand-assisted technique. Parenchymal transection with electro-coagulation	Uneventful postoperatively. Hospital stay: 7 days	Follow-up: 5 months, no recurrence. Normal platelets count
Mignon ²²	Hamartoma	23	F	Vascular control with selective splenic embolization. Delayed surgery	Not reported	Not reported
Hao ²⁶	Wandering spleen	24	F	Parenchymal transection with RFA [†] , splenopexy	Uneventful postoperatively. Hospital stay: 11 days	Follow-up: 11 months, no recurrence. Normal platelets count
Gumbs ²⁷	Cyst	25	F	Parenchymal transection with RFA [†]	Uneventful postoperatively. Hospital stay: 5 days	Follow-up: 1 month, no recurrence. Normal platelets count
Itamoto ²⁸	Cyst	19	M	Parenchymal transection with RFA [†]	Uneventful postoperatively. Hospital stay: 9 days	Follow-up: 4 month, no recurrence. Normal platelets count

[†]Radiofrequency ablation

safety of the selective vascular ligation at the splenic hilum (19,20). In our cases, the control of the polar vessels was achieved with laparoscopic clips. Dudi-Venkata (21) compared different techniques of selective hilar vascular ligation, during open and LPS. The author found no difference in outcomes whether ligatures, clips or staplers were used. Another option to control the splenic vessels is selective splenic embolization (22, 23). This interventional radiologic procedure is indicated in several conditions, including bleeding control in splenic traumatic injuries, gastroesophageal varices or splenic artery aneurysm (24, 26). Despite its efficacy, this technique has some limitations, since it can be performed only in haemodynamically stable patients.

Moreover, very often the radiological suite is not located in the same surgical theatre area; in the context of LPS, the embolization is performed before surgery, therefore demanding for synchronous radiologic and surgical schedules.

In our mini-series, the parenchymal transection was performed with the harmonic scalpel, which proved to be effective in achieving a good haemostasis. Radiofrequency ablation (RFA) is an alternative technique to transect the splenic parenchyma; it is traditionally used in liver surgery allowing for a nearly bloodless parenchymal transection (10, 18, 19, 27, 29). However, if an excessive amount of energy is used for haemostasis, this technique can result in a large rim of necrotic parenchymal tissue (30).

In the cases we presented both patients were discharged two days after surgery, and no early postoperative morbidity and mortality occurred. Other authors reported uneventful postoperative course and early discharge after LPS (Table 1).

Conclusions

LPS is a safe and effective procedure for the treatment of localized splenic diseases and does not require the prescription of life-long antibiotics. The mini-invasive nature of the approach allows for a faster postoperative recovery, shorter hospital stay and better cosmetic results.

Disclosures

Each author declares that he or she has no commercial associations (e.g., consultancies, stock ownership, equity interest, patent/licensing arrangement etc.) that might pose a conflict of interest in connection with the submitted article.

References

1. Makgoka M. Outcomes of hilar pedicle control using suture ligation during laparoscopic splenectomy. *S Afr J Surg.* 2017 Jun;55(2):72-73.
2. Fisichella PM, Wong YM, Pappas SG et al. Laparoscopic splenectomy: perioperative management, surgical technique, and results. *J Gastrointest Surg.* 2014 Feb;18(2):404-10.
3. Somasundaram SK, Massey L, Gooch D, Reed J, Menzies D. Laparoscopic splenectomy is emerging 'gold standard' treatment even for massive spleens. *Ann R Coll Surg Engl.* 2015 Jul; 97(5):345-8.
4. Gamme G, Birch DW, Karmali S. Minimally 124 invasive splenectomy: an update and review. *Can J Surg.* 2013 Aug; 56(4):280-5.
5. Schilling RF. Spherocytosis, splenectomy, strokes, and heart attacks. *Lancet.* 1997;350:1677-1678.
6. Lynch AM, Kapila R. Overwhelming postsplenectomy infection. *Infect Dis Clin North Am.* 1996 Dec; 10(4):693-707.
7. Dahyot-Fizelier C, Debaene B, Mimoz O. Management of infection risk in asplenic patients. *Ann Fr Anesth Reanim.* 2013 Apr; 32(4):251-6.
8. Ho CM. Splenic cysts: a new approach to partial splenectomy. *Surg Endosc.* 2002 Apr;16(4):717.
9. Holdsworth RJ, Irving AD, Cuschieri A. Postsplenectomy sepsis and its mortality rate: actual versus perceived risks. *Br J Surg.* 1991 Sep; 78(9):1031-8.
10. Uranis S, Kronberger L, Kraft-Kine J. Partial splenic resection using the TA-stapler. *Am J Surg.* 1994 Jul;168(1):49-53.
11. Bader-Meunier B, Gauthier F, Archambaud F, Cynober T, Mielot F, Dommergues JP, Warszawski J, Mohandas N, Tchernia G. Long-term evaluation of the beneficial effect of subtotal splenectomy for management of hereditary spherocytosis. *Blood.* 2001; 97:399-403.
12. Wang WD, Lin J, Wu ZQ, Liu QB, Ma J, Chen XW. Partial splenectomy using a laparoscopic bipolar radiofrequency device: a case report. *World J Gastroenterol.* 2015 Mar 21;21(11):3420-4.
13. Slater BJ, Chan FP, Davis K, Dutta S. Institutional experience with laparoscopic partial splenectomy for hereditary spherocytosis. *J Pediatr Surg.* 2010;45:1682-1686.

14. Morinis J, Dutta S, Blanchette V, Butchart S, Langer JC. Laparoscopic partial vs total splenectomy in children with hereditary spherocytosis. *J Pediatr Surg.* 2008; 43:1649–1652.
15. Wang X, Wang M, Zhang H, Peng B. Laparoscopic 149 partial splenectomy is safe and effective in patients with focal benign splenic lesion. *Surg Endosc.* 2014 Dec; 28(12):3273–8.
16. Chin EH, Shapiro R, Hazzan D, Katz LB, Salky B. A ten-year experience with laparoscopic treatment of splenic cysts. *JLS.* 2007;11(1):20–23.
17. Iimuro Y, Okada T, Sueoka H, Hai S, Kondo Y, Suzumura K, Fujimoto J. Laparoscopic management of giant splenic true cyst with partial splenectomy: a case report. *Asian J Endosc Surg.* 2013 Aug;6(3):226–30.
18. Fan H, Zhang D, Zhao X, Pan F, Jin ZK. Laparoscopic partial splenectomy for large splenic epidermoid cyst. *Chin Med J (Engl).* 2011 Jun;124(11):1751–3.
19. Ghuliani D, Agarwal S, Thomas S, Pathania OP. Giant cavernous haemangioma of the spleen presenting as massive splenomegaly and treated by partial splenectomy. *Singapore Med J.* 2008 Dec;49(12):e356–8.
20. Hong TH, Lee SK, You YK, Kim JG. Single-port laparoscopic partial splenectomy: a case report. *Surg Laparosc Endosc Percutan Tech.* 2010 Oct;20(5):e164–6.
21. Dudi-Venkata NN, Houli N, Weinberg L, Nikfarjam M. Laparoscopic partial splenectomy performed by monopolar saline-cooled radiofrequency coagulation. *J Laparoendosc Adv Surg Tech A.* 2014 Jul;24(7):502–5.
22. Okano K, Kakinoki K, Suto H, Oshima M, Akamoto S, Hagiike M, Usuki H, Suzuki Y. Hand-assisted laparoscopic partial splenectomy using an endopath monopolar sealer. *Surg Laparosc Endosc Percutan Tech.* 2011 Dec;21(6):e291–4.
23. Mignon F, Brouzes S, Breitel DL, Bastie JN, Poirier H, Legendre C, Briard P. Preoperative selective embolization allowing a partial splenectomy for splenic hamartoma. *AnnChir.* 2003 Mar;128(2):112–6.
24. Olthof DC, van der Vlies CH, Joosse P et al. Consensus strategies for the nonoperative management of patients with blunt splenic injury: a Delphi study. *J Trauma Acute Care Surg.* 2013 Jun;74(6):1567–74.
25. Stone PA, Phang D, Richmond B. Splenic artery 174 embolization for the treatment of bleeding gastric varices secondary to splenic vein thrombosis. *Ann Vasc Surg.* 2014 Apr;28(3):737
26. Ho MF, Chan YC, Cheng SW. Successful endovascular management of giant splenic artery aneurysms. *Vascular.* 2013 Oct;21(5):317–22.
27. Hao F, Wang W, Yang X. Radiofrequency-assisted partial splenectomy plus splenopexy. A modified surgical procedure for wandering spleen: a case report. *J Laparoendosc Adv Surg Tech A.* 2015 Sep;25(9):760–2.
28. Gumbs AA, Bouhanna P, Bar-Zakai B, Briennon X, Gayet B. Laparoscopic partial splenectomy using radiofrequency ablation. *J Laparoendosc Adv Surg Tech A.* 2008 Aug;18(4):611–3.
29. Itamoto T, Fukuda S, Tashiro H, Ohdan H, Asahara T. Radiofrequency-assisted partial splenectomy with a new and simple device. *Am J Surg.* 2006 Aug;192(2):252–4.
30. Zacharoulis D, Katsogridakis E, Hatzitheofilou C. A case of splenic abscess after radiofrequency ablation. *World J Gastroenterol.* 2006; 12:4256–4258.

Correspondence:

Arrived: 9 July 2020

Accepted: 15 July 2020

Davide Di Mauro,

Royal Devon and Exeter NHS Foundation Trust, Department of Upper GI

Surgery, Barrack Road, Exeter EX25DW, United Kingdom.

Phone: +44 1392 406296.

Email: davidedimauro@nhs.net