

C A S E R E P O R T

Subcutaneous emphysema, pneumomediastinum and spinal epidural emphysema as complications of violent coughing: a case report

Fevzi Yılmaz and Ökkeş Zortuk

Health Sciences University, Antalya Education and Research Hospital; Department of Emergency Medicine, Antalya, Turkey

Abstract. Spontaneous pneumomediastinum (SPM) is a rare condition characterized by chest pain of sudden onset, difficulty breathing, dysphagia, dysphonia, and subcutaneous emphysema, which are sometimes accompanied by pain in the neck or back. This condition typically has a benign character that limits itself, and supportive therapy is all that is needed; however, life-threatening consequences may occur, such as upper respiratory tract obstruction, esophageal injury, and tracheal damage, requiring surgery. We report here a man aged 19 years who coughed vigorously due to acute allergic asthma, which led to subcutaneous emphysema starting from the neck down to the chest, mediastinum and spinal epidural space. This case report stresses the importance of including SPM in the differential diagnosis of cough and chest pain in the young. (www.actabiomedica.it)

Key words: Pneumomediastinum, Subcutaneous Emphysema, Emergency

Introduction

Pneumomediastinum, also known as mediastinal emphysema, refers to air existing in the mediastinal space (1). It can be either spontaneous or trauma induced. The latter is a result of chest trauma, whether blunt or penetrating due to external forces, or occurs by iatrogenic mediastinal air leakage such as that occurring during thoracic operations. Mechanical ventilation typically leads to pneumomediastinum by creating barotrauma. SPM is infrequent, constituting only 0.0025% of all emergency department (ED) admissions (2). SPM is typically a benign condition that limits itself; the most common symptoms of SPM include chest pain and dyspnea, especially in the young males (3). A sudden increase in thoracic pressure causing alveolar rupture, followed by dissection of bronchoalveolar tree and opening into the mediastinum, is the usual etiology of SPM. Although vigorous coughing or retching are able to produce SPM, such culprits may be absent in some cases. Underlying factors

associated with SPM are respiratory disease affecting lungs, and smoking (4).

Herein, we report a young male admitted to the ED with cough, neck and chest pain; he ultimately received the diagnosis of subcutaneous emphysema and pneumomediastinum.

Case Report

A young male aged 19 years presented to ED with cough, neck pain, and chest pain with intermittent intensification which had persisted for 1 week. His personal and familial medical histories were non-remarkable for any medical condition, nor he was using any regular drug. He had been involved in a traffic accident three years earlier; he had also undergone excision of his hypertrophied adenoids and reactive lymph nodes in the neck. He reported having seasonal allergic rhinitis for which he was intermittently using antihistaminic agents and intranasal steroid-based

medications when his asthma exacerbated. He was a non-smoker and gave no history of drug allergy.

On admission, his oxygen saturation was 99% while breathing room air; his blood pressure was 139/78 mmHg, a pulse rate of 100 beats per minute, and a respiratory rate of 24 breaths per minute. He was alert and orientated with a Glasgow Coma Scale of 15/15. His blood glucose was 98 mg/dl, and his body temperature 36.5°C. His examination was notable for widespread wheezes in both lungs and subcutaneous crepitation and emphysema in his neck and upper thorax, but without lymphadenopathy in the region. Other systems were found normal upon examination. His laboratory tests revealed the following: WBC: 17800/mm³, Hb: 17.4 g/dL, Htc: %44.2 platelet count:321000/ mm³, glucose: 84 mg dL, Urea: 13.6 mg/dL, creatinine: 0.82 mg/dL, lactic dehydrogenase: 136 u/l, and CRP: 0.4 mg/l. He had a high sensitivity troponin T level of less than 3 ng/L and a D-Dimer level of 38 micrograms/L. The patient's ECG showed normal sinus rhythm.

Among imaging tests, a posterior-anterior (PA) chest X-RAY showed diffuse emphysema affecting the neck and the mediastinal region (Figure 1). A

computerized tomography (CT) involving the neck and chest regions revealed bilateral free air in the neck, posterior aspect of the right-sides chest wall, mediastinal paraspinal region, and thoracic epidural space. Free air was also noted to extend to paraspinal regions bilaterally as shown in upper abdominal sections (Figure 2). Internal medicine and general surgery departments were consulted with preliminary diagnosis of esophageal rupture leading to diffuse subcutaneous emphysema and pneumomediastinum; a thoracic surgery consultation was also requested for a possible thoracic condition giving rise to pneumomediastinum. The patient was then admitted to hospital for further workup and treatment of pneumomediastinum. His oral intake was stopped; he was monitored noninvasively, and administered analgesics, oxygen (5L/min), bronchodilator medications via inhalation, intravenous steroids, and omeprazole for peptic ulcer prophylaxis.

His follow-up was notable for a dramatic decline of the quantity of free air in the neck and mediastinal space on physical examination and chest X-Rays, with the patient having felt better and non-symptomatic by his third day of admission. A final chest X-Ray showed

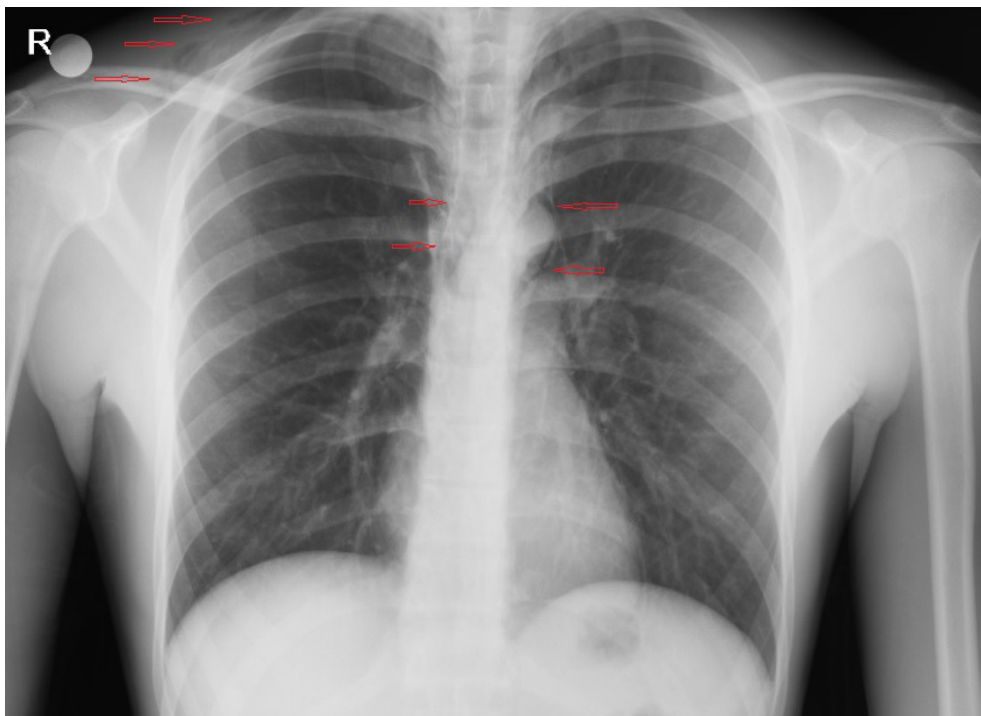


Figure 1. Posterior-anterior (PA) chest X-RAY showed diffuse subcutaneous emphysema in neck and chest wall along with pneumomediastinum.

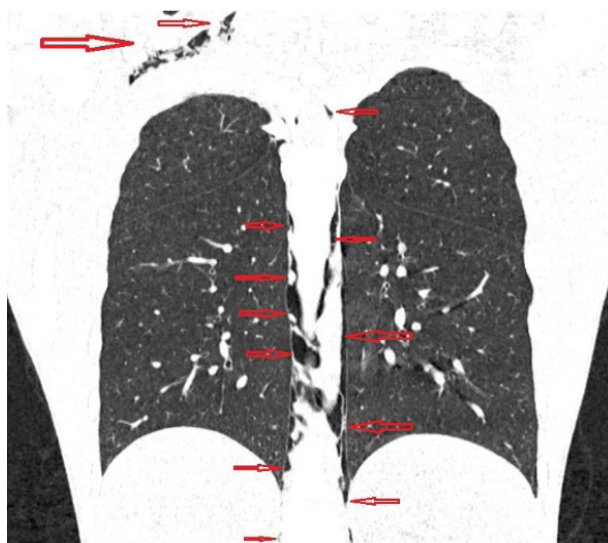

Figure 2. CT scan showed widespread emphysema and pneumomediastinum extend to paraspinal regions.

complete resolution of air (Figure 3), and the patient was discharged home at the fourth day of admission. He was prescribed to take Budesonide 200 µg bid with the help of the AeroChamber device, and to avoid strenuous exercise to prevent a pneumothorax or airway bullae from developing.

Discussion

Pneumomediastinum, referring to free air in the mediastinal cavity, was described in 1819 by Laennec for the first time in the literature; the first case reported by him was secondary to trauma. Hamman described the first case SPM and named the sign of the condition after himself (5). Pneumomediastinum is a condition with types caused by multiple different factors, of which spontaneous and traumatic varieties are the most common. SPM is a condition that usually involves young adult males. The traumatic type, on the other hand, occurs as a consequence of trauma to the head, neck, chest and oral region (6, 7).

The pathophysiology of pneumomediastinum involves an abrupt increase of pressure within alveoli, leading to disruption of alveolar integrity and air leak to the pulmonary interstitial space (interstitial emphysema). When severe enough, free air in the

interstitial space can run to the hilar region and have access to pleural or mediastinal space, giving rise to pneumomediastinum/pneumothorax; alternatively, free air can make its way to peripheral lung parts and reside below the pleural lining, termed as subpleural bullae. If sufficiently large in amount, free air may even dissect fasciae of the neck and thoracic wall on its path, eventually reaching subcutaneous tissue, which is termed as subcutaneous emphysema (8–10). According to our view, our patient was prone to subcutaneous emphysema and pneumomediastinum due to his history of trauma and adenoid surgery, which weakened mucosae and made them likely to rupture through a tear made by a vigorous cough attack.

Carolan et al reported a patient with SPM, the latter extending into cervical and thoracic parts of the spinal canal, which they explained by air dissecting soft tissue planes and neural foramina to enter the spinal canal from the mediastinum, neck, and back (11). For that new finding, they coined the term “spontaneous pneumorrhachis”. Cervical CT examination of our patient showed free air in the cervical and thoracic paraspinal regions and in the epidural space.

The clinical presentation of SPM can vary widely, and ranges between mild symptoms to the potentially fatal Sudden Respiratory Distress Syndrome (ARDS). The patients most commonly complain of chest pain, odynophagia, subcutaneous emphysema, symptoms of varying degrees of mediastinal pressure (dyspnea, bruising), and symptoms of pneumothorax (12).

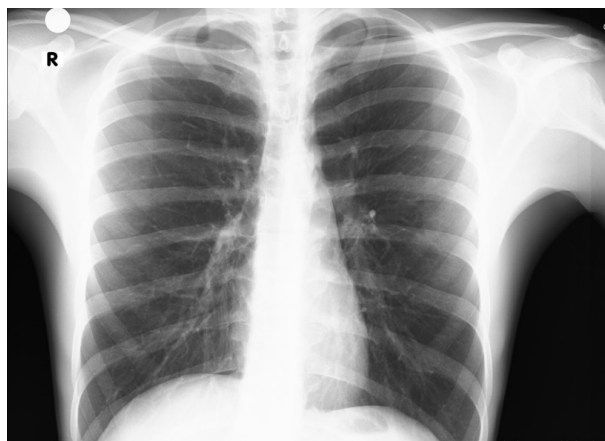

Figure 3. Repeat chest radiograph showed a significant reduction in the pneumomediastinum after 4 days.

Increased intra-alveolar and intra-bronchial pressure causing pneumomediastinum and subcutaneous emphysema can result from a variety of conditions and activities, such as asthmatic bronchospasm, increased intrathoracic pressure due to physical exercise, forceful cough, sneezing, vomiting, gagging, heavy lifting, rapid vaginal delivery, Valsalva maneuver, barotrauma, and cocaine or other drugs taken via nasal route (13). Our patient also suffered neck and chest pain after a cough attack lasting for a week earlier.

As SPM is potentially fatal, timely diagnosis is the key for treatment success. Plain chest films of the neck and chest are typically adequate for diagnosis of cervical subcutaneous emphysema and pneumomediastinum. However, the definitive diagnosis of subcutaneous emphysema is made by CT. The latter is able to detect substantial amounts of air in the various layers of the neck, mediastinum, and the epidural space, quantifying and localizing the emphysema (6, 7). This was also the case in our patient, with an admission CT having localized and quantified emphysema in the regions of the neck, mediastinum, and epidural space. Tracheal or esophageal rupture as a cause of pneumomediastinum can be ruled out by esophagoscopy and bronchoscopy among other diagnostic tests. The treatment is usually directed at the causative condition, with surgery preserved for cases requiring corrective intervention for above emergencies. As we did our patient, consultations should be done with the departments of internal medicine, general surgery, and thoracic surgery to correct any tracheal or esophageal injury, if any. We also admitted our patient for further workup of the condition.

Pneumomediastinum is usually treated by supportive treatment and close follow-up unless a tracheal or esophageal injury is present, or persistent air leakage occurs due to a primary pulmonary condition. The treatment principles include close observation, bed rest, pain alleviation, antibiotic prophylaxis, and prevention of exacerbating events such as straining or performing Valsalva maneuver for any reason (3). Despite rare, respiratory compromise may happen due to massive air entrapment and airway compression at any stage, prompting endotracheal intubation or performing tracheotomy as necessary (14). Serious complications are best treated by mediastinal needle aspiration,

cervical mediastinotomy, tracheostomy or emergency thoracotomy. We detected no tracheal or esophageal injury and deemed conservative management sufficient.

Conclusion

Pneumomediastinum is among the several etiologies and should be definitely remembered in patients with chest and neck pain accompanied by vigorous and long-lived cough attacks. Individuals at risk of SPM should be timely evaluated to identify them in order to avoid the condition's morbidity and mortality in missed cases.

Conflict of interest: Each Author declares that he or she has no commercial associations (e.g. consultancies, stock ownership, equity interest, patent/licensing arrangement etc.) that might pose a conflict of interest in connection with the submitted article.

References

1. Mason R, Broaddus V.C, Martin T. Pneumomediastinum and mediastinitis, in Murray and Nadel's Textbook of Respiratory Medicine, 5th Edition, 2010, Elsevier Health Sciences.
2. Fitzwater JW, Silva NN, Knight CG, Malvezzi L, Ramos-Irizarry C, Burnweit CA. Management of spontaneous pneumomediastinum in children. *J Pediatr Surg* 2015; 50 (6): 983-6.
3. Song IH, Lee SY, Lee SJ, Choi WS. Diagnosis and treatment of spontaneous pneumomediastinum: experience at a single institution for 10 years. *Gen Thorac Cardiovasc Surg* 2017; 65(5): 280-4.
4. Paul N, Vasudev R, Nanavati S, et al. Spontaneous pneumomediastinum complicated by pneumopericardium after a single use of inhaled methamphetamine. *Lung India* 2019; 36(3): 271-3.
5. Chu CM, Leung YY, Hui JY, et al. Spontaneous pneumomediastinum in patients with severe acute respiratory syndrome. *Eur Respir J* 2004; 23(6): 802-4.
6. Cervellin G, Bellini C, Tarasconi S, Bresciani P, Lippi G. Massive pneumomediastinum following orbital fracture. *Am J Emerg Med* 2017; 35(10): 1585.e1-1585.e2.
7. Ong WC, Lim TC, Lim J, Sundar G. Cervicofacial, retropharyngeal and mediastinal emphysema: a complication of orbital fracture. *Asian J Surg* 2005; 28(4): 305-8.
8. Özhasenekler A, Gökhan Ş, Yılmaz F, Tan Ö, Nasır A. Pneumomediastinum and Pneumothorax After Blunt Neck Trauma. *Journal of Emergency Medicine Case Reports* 2010; 1(2): 17-9.

9. Girard C, Khouatra C, Cordier JF, Cottin V. Spontaneous pneumomediastinum associated with pneumorachis. *Am J Respir Crit Care Med* 2014; 189(11): e69.
10. Murayama S, Gibo S. Spontaneous pneumomediastinum and Macklin effect: Overview and appearance on computed tomography. *World J Radiol* 2014; 6(11): 850-4.
11. Carolan PL, Wright SL, Jha V. Spontaneous pneumorrhachis. *Pediatr Emerg Care* 2013; 29(4): 508-9.
12. Yilmaz F, Özlem M, Aslan Ö, Yel C. Orbital Emphysema and Orbital Floor Fracture following a Severe and Prolonged Sneezing Attack. *Hong Kong Journal of Emergency Medicine* 2015; 22(4): 256-8.
13. Vianello A, Caminati M, Chicco-Bianchi F, et al. Spontaneous pneumomediastinum complicating severe acute asthma exacerbation in adult patients. *J Asthma* 2018; 55(9): 1028-34.
14. Chiba Y, Kakuta H. Massive subcutaneous emphysema, pneumomediastinum, and spinal epidural emphysema as

complications of violent coughing: a case report. *Auris Nasus Larynx*. 1995; 22(3): 205-8.

Correspondence:

Arrived: 24 June 2020

Accepted: 8 July 2020

Fevzi YILMAZ, MD,

Associate Prof. Health Sciences University,

Antalya Education and Research Hospital,

Department of Emergency Medicine,

Antalya, TURKEY

Phone: +90 242 2494400;

fax: +90 242 249 44 87

Email: fevzi_yilmaz2002@yahoo.com