

Short communication: bioarchaeology

Bioarchaeology of affluence: Gold plate dentures as conspicuous consumption in the 19th century US South

Shawn M. Phillips

Human Osteology Laboratory, Department of Earth & Environmental Systems, Indiana State University, Terre Haute, IN, USA

Abstract. The first examples of gold plate dentures recovered from an archaeological context are presented. The field of archaeology has a robust literature on the notion of "conspicuous consumption," bioarchaeology, in contrast, has focused class-based research on differential measures of health, with an emphasis on poverty indicators rather than affluence. Recent bioarchaeological workers have suggested the mouth as a nexus for identity and class representation. This study presents gold plate dentures as a bioarchaeological artifact that reflects affluency and conspicuous consumption. Through the process of mastication, dentures interact directly with alveolar tissues and, simultaneously, serve purposes of functionality as well as markers of affluence and identity.

Key words: gold plate dentures, bioarchaeology of affluence, conspicuous consumption, class & identity

This communication reports the first examples of gold plate dentures recovered from an archaeological context (See Figure 1). Gold plate dentures represent a luxury item of affluence that reflect conspicuous consumption. While the field of archaeology has developed a robust literature on conspicuous consumption (Gerard-Little et al., 2016; Heinrich, 2014; Mathews, 2002), the field of bioarchaeology has yet to do so. The recovery of dentures, an artifact that interacts directly with the skeletal system via mastication, provides an opportunity for bioarchaeology to enter into this discussion. Gold plate dentures were briefly produced as an oral health care option in mid 19th century America until replaced by less expensive and more functional vulcanized rubber and plastics (Donaldson, 2012; French, 1854; Sprau, 1910). The dentures were recovered from a family cemetery and were associated with a married couple who were buried at different times, the husband in 1872 and the wife in 1878 (Phillips, 2010 & 2016). The history of dentistry describes the dentures as problematic due their heaviness and slippage issues. As a result, despite the expense, patients found the dentures uncomfortable and rarely wore them (French, 1854; Sprau, 1910). This study shows, however, that two lines of evidence contradict that assessment. Both sets of dentures reported here show occlusal attrition on the porcelain cusps on the right side and both individuals demonstrate well-developed maxillary and mandibular alveolar bony ridges, indicating a long-term osseous response to the pressure of denture wear. A goal for this study is to provide an example of dental work that, up till now, is only described through dental history and to suggest that such a luxury item represents a bioarchaeological artifact of conspicuous consumption linked directly to the body and identity.

The two pair of dentures were archaeologically recovered from the Vardeman-Holmes-Stephenson (VHS) family cemetery located in rural east, central Kentucky, USA. The cemetery was excavated and relocated, with family support, due to the threat of construction activities (Phillips, 2010). Phillips (2010) provides site background information, material culture analysis, and bioarchaeological analysis of the VHS

Figure 1. Image a. shows (anterior is down) the articulation surfaces of the upper and lower gold plate dentures of Eliza (Vardeman) Holmes. Image b. shows (anterior is down) the articulation surfaces of the upper and lower gold plate dentures of Samuel Holmes. Note the triagular impression in the upper plates of both dentures. This impression was in place to provide "atmospheric pressure," as in a suction force, to hold the upper dentures in place. Image c. shows the anterior view of Eliza (Vardeman) Holmes dentures in which the porcelain teeth are visible. The madibular lower right incisor was likely broken antermortem, a porcelain crown was not recovered in the excavation. Image d. shows the anterior view of Samuel Holmes dentures in which the porcelain teeth are visible. There is dark staining on the lower denture on the left buccual aspect of both sets of dentures. Tabacco use is a possible cause of the staining.

excavation. The family cemetery spans five generations from the late 1700s to the mid 20th century (Phillips, 2010 & 2016). The married couple, Samuel Holmes (1814-1872) and Eliza (Vardeman) Holmes (1812-1878) are second generation pioneers and represent an affluent generation that engaged in the emergent conspicuous consumption that accompanied wealth accumulation in mid 19th century America (Mathews et al., 2002; Velben, 1899). Along with their gold plate dentures, both were buried with a number of markers of affluence that included, but not limited to, an iron casket, marble headstone, and an expensive suit for Sam Holmes, and jet beads and a fine black silk dress for Eliza (Vardeman) Holmes (Phillips, 2010). Skeletal observations matched headstone and documentary data for individuals in their late 50s and 60s

(Phillips, 2010). Samuel Holmes was robbed and murdered on a train, with corresponding cranial and thoracic perimortem trauma. Eliza Holmes died from a chronic case of pleurisy that she suffered from for at least 25 years. Pleurisy, a lung condition, does not leave diagnostic skeletal markers.

Veblen (1899) introduced the social theory of leisure with "conspicuous consumption" as a lens to explain the purchase and use of unnecessarily expensive goods as a means to project and display status in societies where individuals have the potential to accumulate wealth. Gold plate dentures certainly fit this description, and in a time when unchecked tooth decay was commonplace, the display of such a luxury item literally apart of one's face may more accurately be considered a form of invidious consumption, an item used or worn to incite envy (Carolan, 2005; Veblen, 1899). The field of archaeology has a robust literature on various examples of material culture used as conspicuous consumption to reflect status (Heinrich, 2014), the production of affluence (Gerard-Little et al., 2016), and how consumption and display of objects can serve a dialectical social process to attain or maintain identity (Matthews et al., 2002). Bioarchaeological research has relied less on material culture to demonstrate class differences but instead has used measures of health differences such as frailty among the poor and lower classes to assess the impacts of social stratification. This is, perhaps, best reflected in the recent research into the social and health transitions that occurred from the medieval to the post-Industrial periods in regions of England (DeWitte et al., 2016; Marklein & Crews, 2022; Mays et al., 2009; and Newman et al., 2019). Examples of bioarchaeological "embodiment" and class include works that link the body as a product of a particular time and situate the individual (Matherna-Allen & Zuckerman, 2020), particularly the mouth, as a locus that entwines class, dental care, and identity (Hosek et al., 2020). Carolan (2005) suggests the notion of materialistic, consumptive display should be extended to include the body, that the individual themselves can embody conspicuous consumption. Gold plate dentures fit this model of conspicuous, or even perhaps invidious, consumption as a means to demonstrate affluence through a prominent facial display.

Gold has been used in various forms of dentistry for millennia (Donaldson, 1980 & 2012). The first possible form of gold use as a dental remedy was recovered in Giza, 3rd millennium BC (Junker, 1929). Early forms of gold dental appliances, such as wire, were comparatively crude by modern standards, however the early use of gold demonstrates the recognition of the metal's properties to not tarnish or degrade in the oral cavity when exposed to acidic or alkaline compounds or the digestive enzymes in saliva such as proteases, lipases and glycohydrolases (Donaldson, 1980 & 2012; Hilson, 2023; Ruhl, 2012). By the 19th century the use of gold became more sophisticated with advances and the professionalism of dentistry (Donalson, 2012). The most common use, perhaps, was gold foil to fill cavities. In addition, gold was used for other dental appliances such as bridges and caps (Donalson, 2012; Sprau, 1910). Pertinent to the current study, was the use of gold for denture plates (Donalson, 2012; French, 1854; Ladha & Varma, 2011; Sprau, 1910). For these dentures, a mold of a patient's mouth was made and gold, no less than 18 carat purity, was used (French, 1854). Once the mold was made, individual artificial porcelain teeth were placed (French, 1854; Proskauer, 1955). "Atmospheric pressure," as with a suction cup, was the means by which the dentures were to be held in place (French, 1854; Sprau, 1910). A problem for the dentures was that they were uncomfortably heavy and would slip when talking or eating. According to dental history, they were rarely worn and were quickly replaced with advances in vulcanized rubber and plastics and subsequent forms of less weighty, more comfortable forms dentures (French, 1854; Sprau, 1910).

Figure 1 shows images of the two sets of gold plate dentures recovered in the VHS excavation. Gold plate dentures were only in production in the US between the years circa 1850 to 1865, and, due to the expense, were not widely distributed (French, 1854; Sprau, 1910). The porcelain teeth were individually made to fit with the molded plate specific to the patient and for convenience in the event a replacement was needed (French, 1854; Proskauer, 1955). The dental formula prepared in the dentures is 2:1:2:2 reflecting a dental quadrant of 2 incisors, 1 canine, 2 premolars, and 2 molars rather than 3 molars. The second, right, mandibular incisor in Figure 1c is missing and was likely lost antemortem (it was not recovered during excavation). Since the couple has a matching set of dentures,

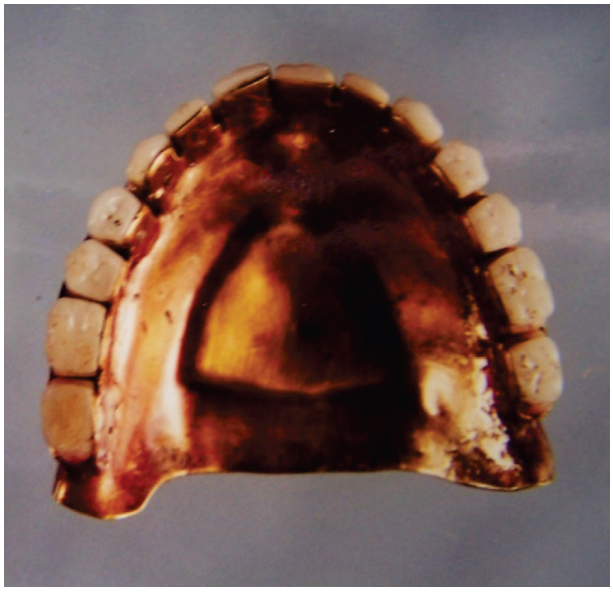

Figure 2. This view, anterior is up, of Samuel Holmes upper dentures shows the occlusal surfaces of the porcelain teeth. The cusps etched in to the premolars and molars gives the teeth a natural, realistic impression. Of note, the molar cusps on the right side exhibit more attrition than the left indicating masticatory wear and a right side chewing preference.

Figure 3. This image shows (anterior is right) Samuel Holmes edentulous mandible. Of note, all teeth were lost ante-mortem, some likely from dental extraction, and the sockets are all fully resorbed. Also, note the bony ridge protruding along the dental arch. The ridge is interpreted as a bony response to the pressure of wearing the heavy, gold plate dentures.

it is likely they were purchased around the same time. However, Eliza (Vardeman) Holmes outlived her husband by six years so it is assumed she had that much more use from them. Finally, in contradiction with dental history which asserts gold plate dentures were not worn (French, 1854; Sprau, 1910), both sets of dentures show occlusal attrition on the porcelain crowns with greater attrition on the right side (See Figure 2). This was determined by the observation that the cusps on the porcelain molars were more eroded. This is fairly direct evidence that the dentures were worn despite the problems of heaviness and slippage as reported in the history of dentistry (French, 1854; Sprau, 1910).

Other evidence that both dentures were worn comes directly from the skeletal record. The maxillae and mandibles of both Samuel Holmes and Eliza (Vardeman) Holmes show signs of bony response. Figure 3 shows an edentulous mandible with complete resorption of all aleveolar sockets. Bony response on both maxillae and mandibles is observed as an alveolar ridge of bone that resulted from the pressure of wearing the heavy dentures. Those observations indicate long term use in order for the ridge to form after resorption of the dental sockets. There is no means to estimate the formation of the bony response, however, it is likely more than 10 years but less than 20 years given the ages of both Samuel and Eliza and the timing of when the dentures were first developed and manufactured. The purchase and wearing of gold plate dentures are actions that stand in stark contrast to the modest and utilitarian pioneer generation that directly preceded Samuel and Eliza Holmes. It is suggested here that the recovery of the matching pair of dentures is an example of conspicuous consumption that is tied to identity and status and provided a facial display of the benefits of the accumulation of generational wealth.

In closing, this study reports the first examples of gold plate dentures to be recovered from an archaeological context. Dentures are a rare example of material culture artifacts that impact and spur a bony response from the skeletal system due to masticatory action. Contradicting dental history, there is evidence on the dentures and on the bone that the dentures were worn

for an extended time and likely regularly. Also of note is the rarity of the recovery of such an artifact. Clearly, gold plate dentures were expensive and a sign of affluence and represent an example of the body as the locus of conspicuous consumption. In this example, a married couple shared in the display of conspicuous, or perhaps invidious, consumption with a facial display of porcelain teeth embedded in gold in a time when unchecked tooth decay was commonplace. As such, the artifacts link identity, status, affluence and functionality in a manner that can demonstrate the mouth as a nexus of those markers.

Acknowledgements: Thanks to Joanna Phillips and Nathaniel Phillips for their constructive critiques and support. This project was supported by the Kentucky Transportation Cabinet and the Kentucky Heritage Council. This project benefited from a sabbatical which provided time for research and writing.

References

Austin, A. (2022). Dental health and dentistry in ancient Egypt: Possible evidence for dental filling and extraction at Deir el-Medina. *International Journal of Paleopathology, 38*, 95-106.

Carolan, M. (2005). The conspicious body: Capitalism, consumerism, class and consumption. *Worldviews: Global Religions, Culture, and Ecology*, *9*(1), 82-111.

DeWitte, S. N., Hughes-Morey, G., Bekvalac, J., & Karsten, J. (2016). Wealth, health and frailty in industrial-era London. *Annals of human biology*, *43*(3), 241-254.

Donaldson, J. A. (2012). The use of gold in dentistry: an historical overview. Part 2. *Journal of the History of Dentistry, 60*(3), 134-147.

Donaldson, J. A. (1980). The use of gold in dentistry: An historical overview. Part I. *Gold bulletin, 13*(3), 117-124.

French, M. D. (1854). Report upon the Rise, Progress and Prospects of Mechanical Dentistry. *The American Journal of Dental Science*, *4*(4), 531-51.

Gerard-Little, P. A., Moutner, A. K., Jordan, K. A., & Rogers, M. B. (2016). The production of affluence in Central New York: the archaeology and history of Geneva's White Springs Manor, 1806–1951. *Historical Archaeology*, *50*, 36-64.

Hilson, S. (2023). Dental Anthropology, 2nd ed. Cambridge University Press, Cambridge.

Heinrich, A. R. (2014). Cherubs or Putti? Gravemarkers demonstrating conspicuous consumption and the rococo fashion in the eighteenth century. *International Journal of Historical Archaeology, 18*, 37-64.

Hosek, L., Warner-Smith, A. L., & Watson, C.C. (2020). The body politic and the citizen's mouth: Oral health and dental care in nineteenth-century Manhattan. *Historical Archaeology, 54*, 138-159.

Junker, H. (1929). *Giza, Bericht über Grabungen aufdem Friedhof des Alten Reiches*. Wien, Leipzig.

Ladha, K., & Verma, M. (2011). 19th Century Denture Base Materials Revisited. *Journal of the History of Dentistry, 59*(1), 1-11.

Marklein, K. E., & Crews, D. E. (2022). Highs and lows of frailty: skeletal frailty differentials among socioeconomic groups in Postmedieval London. *Archaeological and Anthropological Sciences*, *14*(3), 1-22.

Mathena-Allen, S., & Zuckerman, M. K. (2020). Embodying industrialization: inequality, structural violence, disease, and stress in working-class and poor British women. In L.A. Tremblay and S. Reedy (Eds.), *The Bioarchaeology of Structural Violence: A Theoretical Framework for Industrial Era Inequality* (pp. 53-79). Springer Press.

Matthews, C. N., Leone, M. P., & Jordan, K. A. (2002). The political economy of archaeological cultures: Marxism and American historical archaeology. *Journal of social archaeology*, *2*(1), 109-134.

Mays, S., Ives, R., & Brickley, M. (2009). The effects of socioeconomic status on endochondral and appositional bone growth, and acquisition of cortical bone in children from 19th century Birmingham, England. *American Journal of Physical Anthropology, 140*(3), 410-416.

Newman, S. L., Gowland, R. L., & Caffell, A. C. (2019). North and south: A comprehensive analysis of non-adult growth and health in the industrial revolution (AD 18th–19th C), England. *American Journal of Physical Anthropology, 169*(1), 104-121.

Phillips, S. M. (2016). Bioarchaeology of a Kentucky Pioneer Family: The Vardeman-Holmes-Stephenson Cemetery Project, Lincoln County, Kentucky. *Ohio Valley Historical Archaeology*, *26*, 132-41.

Phillips, S. M. (2010). Bioarchaeology of the Holmes-Vardeman-Stephenson Cemetery Project: Report to the KY Transportation Cabinet. Unpublished report submitted to the Program for Archaeological Research, UK/Human Osteology Lab, Indiana State University.

Proskauer, C. (1955). Earliest porcelain teeth in America. *Bulletin of the History of Dentistry, 3*(3), 1-2.

Ruhl, S. (2012). The scientific exploration of saliva in the post-proteomic era: from database back to basic function. *Expert Rev Proteomics 9*(1), 85-96.

Sprau, R. (1910). *History of Kentucky Dentistry* 1636-1910. Kentucky Dental Association, Lexington.

Veblen, T. (1899). *The theory of the leisure class*: *An economic study of institutions*. B. W. Huebsch, New York.

Correspondence:
Shawn M. Phillips, Professor of Anthropology
Human Osteology Laboratory, Department of Earth & Environmental Systems, Indiana State University, Terre Haute IN, USA
E-mail: shawn.phillips@indstate.edu