

## SEVEN PATIENTS WITH CRYPTOGENIC ORGANIZING PNEUMONIA SUCCESSFULLY TREATED WITH CLARITHROMYCIN

*Fatma Ciftci, Özlem Özdemir Kumbasar*

Ankara University School of Medicine, Department of Chest Disease, Ankara, Turkey

**ABSTRACT.** Cryptogenic organizing pneumonia is a type of idiopathic interstitial pneumonia with a subacute presentation characterized by variable degrees of cough and dyspnea. As a consequence of the upregulation of inflammatory mediators in cryptogenic organizing pneumonia, it typically responds to anti-inflammatory therapy. Although the majority of patients recover completely with long term oral corticosteroids, relapse is common and their long term use is associated with many adverse effects. Macrolides antiinflammatory agents that appear effective and safe for the treatment of cryptogenic organizing pneumonia. Herein, we analyzed the clinical properties of seven cryptogenic organizing pneumonia patients without severe functional loss who were treated with clarithromycin. (*Sarcoidosis Vasc Diffuse Lung Dis* 2018; 35: 165-170)

**KEY WORDS:** cryptogenic organizing pneumonia, COP, COP treatment, macrolide, clarithromycin

### INTRODUCTION

Cryptogenic organizing pneumonia (COP) is a rare lung disease of unknown etiology characterized by pulmonary inflammation and fibrous proliferation (1). Histological findings demonstrate OP characterized by endoluminal buds of granulation tissue known as Masson bodies filling the alveoli and spreading to the alveolar ducts and terminal bronchioles, which form distinctive polyps with different amounts of inflammatory infiltrates and fibrosis (2).

Although it is typically associated with a favorable prognosis, it may also present in a progressive form (3). Glucocorticoids are the most commonly used agents for the treatment of COP and the majority of patients respond to these agents. However, a

long treatment duration with these agents are associated with serious side effects (4). Both glucocorticoid resistant cases and relapses after the cessation of glucocorticoids have been reported (5).

Macrolides reportedly possess various anti-inflammatory properties in addition to their antimicrobial effects. Some inflammatory mediators synthesized in the respiratory system, which are chemotactic for neutrophils, such as TNF- $\alpha$ , IL-8 and IL1-b, are reduced in concentration by macrolide therapy (6). Macrolides also possess some other anti-inflammatory effects including the inhibition of the elastase enzyme and the suppression of the granulocyte-macrophage colony stimulating factor and soluble adhesions molecules (7). Macrolide therapy also reduce the concentrations of the inflammatory mediators such as IL-6 and NO (6). Increased concentrations of these mediators and macrolides' non-specific anti-inflammatory actions are thought to play a role in their efficacy in COP (8). Clarithromycin (CLA) is the most commonly prescribed macrolide for this indication. It is used as the first-line treatment in cases free of severe conditions such as respiratory failure, or as an alternative to steroids in steroid resistant cases (9).

Received: 9 November 2017

Accepted after revision: 2 March 2018

Correspondence: Fatma Ciftci, MD, Specialist

Ankara University School of Medicine

Department of Chest Disease

Ankara, Turkey

Tel. +905055817946

E-mail: fciftci@ankara.edu.tr

Herein, we report the clinical properties of patients were diagnosed as COP and treated with CLA.

## METHODS

The clinical properties of 7 patients who were diagnosed as having COP and prescribed clarithromycin between 2011 and 2016 were reviewed. The criteria for starting this treatment included the absence of respiratory failure ( $\text{PaO}_2 > 55$ ,  $\text{PaCO}_2 < 45$ ), and severe respiratory functional loss ( $\text{DLCO} > 60\%$ ). COP was diagnosed on the basis of clinical signs, symptoms, and radiological findings suggestive of COP, a negative microbiological analysis, the absence of any clinical and radiological response to antibiotic therapy, and the exclusion of other causes (exposure to toxic substances, drugs or radiotherapy). The diagnosis was supported by BAL in 2 cases and trans-thoracic lung biopsy in 1 case. Surgical lung biopsy was not performed owing to high-probability clinical presentation and radiological signs, as well as the patients' refusal of invasive diagnostic procedures. The admission symptoms, physical examination findings, results of routine blood and urine analyses, and microbiological tests were analysed. Anti-nuclear antibodies, anti-neutrophil cytoplasmic antibodies, and rheumatoid factor were assessed. Chest X-ray and thorax high resolution computed tomography (HRCT) were interpreted by an experienced radiologist.

## RESULTS

The age range of the study population was 50-68 years; there were 3 women and 4 men. The general characteristics of the patients at initiation of therapy were presented on Table 1. There were 4 non-smokers and 3 former smokers with a history of cumulative smoking of 6, 15, and 20 years. The most common admission symptoms were, in the descending order of frequency, dyspnea ( $n=7$ ), cough ( $n=6$ ), weakness ( $n=5$ ), fever ( $n=2$ ), sweating ( $n=2$ ), sputum ( $n=1$ ), hemoptysis ( $n=1$ ), weight loss ( $n=1$ ), chest pain ( $n=1$ ), and palpitations ( $n=1$ ). The duration of symptoms was approximately 1 month in 6 patients and 2 months in 1 patient. All patients had received at least two different empirical antibiotic treatment

**Table 1.** Characteristics of COP patients

Age range, yr	50-68
Sex	
Female	3 (42.8)
Male	4 (57.1)
Smoking status	
Former smoker	3 (42.8)
Non-smoker	4 (57.1)
Cumulative smoking, pack/yr	6-20
Comorbidities	
Hypertension	2 (28.6)
Diabetes mellitus	3 (42.8)
Familial mediterranean fever	1 (14.3)
Gut	1 (14.3)
Symptoms	
Dyspnea	7 (100)
Cough	6 (85.7)
Weakness	5 (71.4)
Fever	2 (28.6)
Sweating	2 (28.6)
Sputum expectoration	1 (14.3)
Hemoptysis	1 (14.3)
Weight loss	1 (14.3)
Chest pain	1 (14.3)
Palpitations	1 (14.3)
Thorax HRCT	
Bilateral infiltrations	7 (100)
Consolidation	7 (100)
Air bronchogram	7 (100)
Ground glass opacities	7 (100)
Migration	5 (71.4)
Pleural fluid	-
Mediastinal LAP > 1cm	-
Hematocrit	34-43.9
WBC	6222-20040
Eosinophil count	20-300
ESR	16-80
CRP	1.8-164.9
ANA > 1:160, n	2 (28.6)

HRCT, high resolution computed tomography; LAP, lymphadenopathy; WBC, white blood cell count; ESR, erythrocyte sedimentation rate; CRP, C-reactive protein; ANA, anti-nuclear antibody

prior to receiving the diagnosis of COP. Two patients had received steroid treatment before study entry. A review of former therapies revealed that Case 6 had been diagnosed with COP 3 years ago. That patient had received oral deflazacort for periods of 6 months; she developed relapse at three months despite complete clinical and radiological recovery initially. Case 3 had been diagnosed 1.5 year ago and received methylprednisolone for 6 months. Having a relapse at first year and uncontrolled diabetes, that patient

was not administered corticosteroid therapy. Apart from these two patients, 5 other patients were newly diagnosed cases and administered CLA as the first-line therapy.

Two patients were detected to have anti nuclear antibody (ANA) positivity (1:160) although they were free of any rheumatological disease. All patients were negative for antineutrophil cytoplasmic antibody (ANCA) and rheumatoid factor (RF).

The maximal expiratory flows (FEV1, FVC) and carbonmonoxide diffusion capacities (DLCO) were presented on the Table 2. Three patients had FEV1 <80%; 2 patients had FVC <80%; 3 patients had DLCO <80%. Patients had a PaO<sub>2</sub> range of 58.1-89.4 and a SaO<sub>2</sub> range of 90-98%.

All patients had bilateral infiltration, consolidation, ground glass opacities, and air bronchogram on thoracic HRCT; five patients had migration of opacities. None of the patients had pleural fluid or pathological lymphadenopathy (>1 cm). The HRCT images of all cases (A-G) before (a) and after treatment were shown in Figure 1.

Bronchoalveolar lavage (BAL) was performed with the fiberoptic bronchoscope, in a wedge position within the affected lower lobe or middle lobe segment: 200 mL of sterile, room-temperature, 0.9% saline was instilled into the alveolar space in 50-mL aliquots, and gently removed. Case 1, 120 mL of BAL fluid was retrieved. The BAL fluid had 100×10<sup>6</sup> cells/mL: 60% alveolar macrophages, 21% lymphocytes, 13% neutrophils, and 0.2% eosinophils. The CD4/CD8 ratio of lymphocytes was 0.6. Case 5, 140 ml mL of BAL fluid was retrieved. The BAL fluid had 120×10<sup>6</sup> cells/mL: 54% alveolar macrophages, 25% lymphocytes, and 10% neutrophils. The CD4/CD8 ratio of lymphocytes was 0.4. BAL specimen

was sent to the microbiology laboratory for fungal, anaerobic and aerobic microorganisms, and acid-fast bacilli studies in both patients. No microbiological agent was detected. Case 6 had undergone fine needle aspiration biopsy for a differential diagnosis of malignancy three years ago. Its cytopathological evaluation revealed organizing pneumonia.

All patients were begun on CLA treatment at a dose of 0.5 g b.i.d. They were evaluated at three-month intervals. The cases did not reported any serious side effects. Complete clinical and radiological remission was obtained at three months in 3 patients; at six month in 3 patients; and at 9 months in 1 patient. The HRCT images of cases before (a) and after treatment (b) were presented at Figure 1. The follow-up duration ranged between 12 and 36 months when no relapses were observed (Table 2).

## DISCUSSION

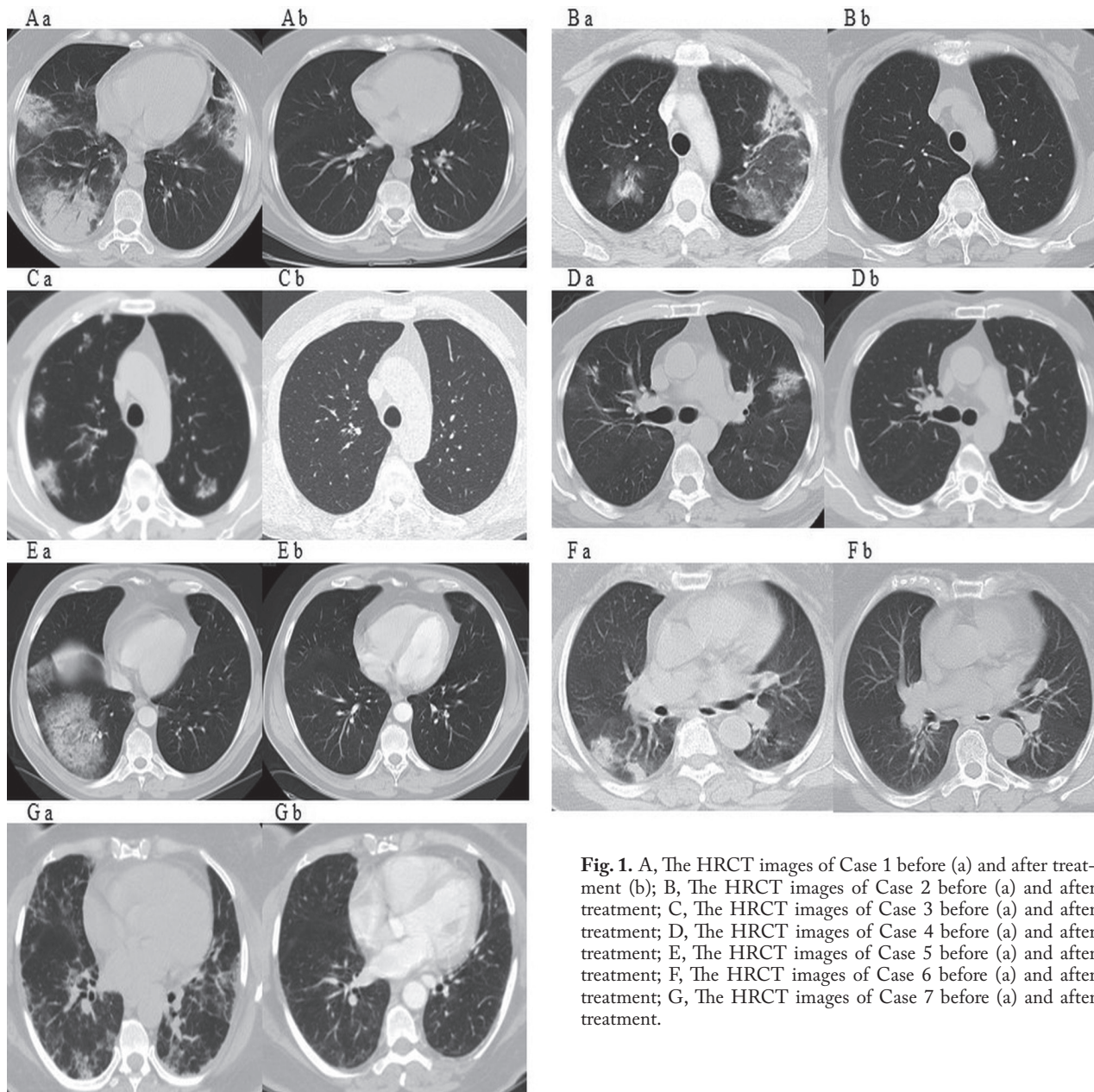
This paper discusses the clinical features of 5 newly diagnosed and 2 steroid resistant cases who received the diagnosis of COP on the basis of clinical and radiological findings and who were successfully treated with CLA. Although we did not perform any statistical analysis due to a small sample size, we noted that our group's clinical and radiological features showed similarity with previous reports in the literature.

Males and females are equally affected by COP, with mean age of onset of 50-60 years (10). COP is clearly non-related to smoking. Clinical manifestations begin with a mild flu-like illness with fever, cough, malaise, and they progress to mild dyspnoea, anorexia and weight loss. Dyspnoea is usually not se-

**Table 2.** Respiratory functions, diagnostic procedures, treatment and follow-up durations of the study population

Case number	PaO <sub>2</sub> , mmHg	FEV1, % predicted	FVC, % predicted	DLCO, % predicted	BAL	TTAB	Previous steroid treatment	Treatment duration, months	Follow-up duration, months
1	89.4	87	89	90	+			9	24
2	63.2	65	72	75				3	12
3	73.0	68	75	80			+	3	12
4	85.2	80	83	91				6	36
5	60.0	76	80	78	+			6	12
6	66.5	90	98	100		+	+	3	12
7	58.1	87	90	62				6	12

PaO<sub>2</sub>, partial oxygen pressure; FEV1, forced expiratory volume at first second; FVC, forced vital capacity; DLCO, carbonmonoxide diffusion capacity; BAL, bronchoalveolar lavage; TTAB, transthoracic fine needle aspiration biopsy



**Fig. 1.** A, The HRCT images of Case 1 before (a) and after treatment (b); B, The HRCT images of Case 2 before (a) and after treatment; C, The HRCT images of Case 3 before (a) and after treatment; D, The HRCT images of Case 4 before (a) and after treatment; E, The HRCT images of Case 5 before (a) and after treatment; F, The HRCT images of Case 6 before (a) and after treatment; G, The HRCT images of Case 7 before (a) and after treatment.

vere. Haemoptysis is uncommon and seldom severe. Since the most common manifestations are nonspecific, diagnosis is often delayed (6-13 weeks).

The three main characteristic imaging patterns of COP include multiple alveolar opacities (typical COP), solitary opacity (focal COP), and infiltrative opacities (infiltrative COP) (11). In a study exploring the diagnostic accuracy of HRCT in a patient series with various idiopathic interstitial pneumonia

types, the correct diagnosis rate was highest (79%) for COP (12), suggesting that the computed tomography imaging features are characteristic.

Our cases showed typical radiological signs of COP which include patchy areas of consolidation (peripheral, bilateral, possibly migratory, air bronchogram).

We performed BAL in two of our cases and detected an increased lymphocyte count and a fall in

the CD4/CD8 ratio, which are both characteristic of COP. In addition, main value of BAL in COP is the exclusion of other causes of organising pneumonia, particularly infections and neoplastic disorders. Ventilatory disorders were not very severe among our group. We noted reactive flow restriction in 2 cases and mild diffusion capacity reduction in 3 cases.

Cai and colleagues reported that protein for TNF- $\alpha$ , sTNFR1/2, IL-1 $\beta$ , IL-6, IL-8, IL-10, interferon- $\gamma$ -induced protein 10, and chemokine ligand 18 were upregulated in alveolar macrophages obtained from 6 patients with COP. Such upregulation of some cytokines and chemokines suggests the participation of activated neutrophil and Th1 pathways, an event that contributes greatly to ongoing epithelial injury (13).

Anti-inflammatory therapy is usually effective for the suppression of the symptoms of COP, due largely to the upregulation of inflammatory mediators. Corticosteroids is commonly used to manage COP (10).

Corticosteroids lead to rapid resolution of symptoms as well as the radiological elimination of pulmonary opacities and the absence of any significant sequelae. Quitting steroids or reduction their dose usually results in relapsing disease, which often compels prolonged treatment. Prolonged therapy brings about side effects such as steroid induced diabetes, osteoporosis, and myopathy. Recently, macrolides have come forward as an alternative to steroids. Macrolides are well known for numerous immunomodulatory actions, one of the most important ones of which is the regulation of leucocyte function, cytokine synthesis, apoptosis, and mucus production (14). Macrolides suppress the release of tumor necrosis factor (TNF) and other cytokines and neutrophil oxidation; enhance mucociliary clearance, and prevent biofilm development and bacterial flagellin expression (15). They also inhibit cytokine synthesis. They are thought to be effective in COP thanks to these anti-inflammatory properties (16).

It has also been shown that the cytokines that play a role in the pathogenesis of COP are lowered in cases responding to CLA. Patients who did not respond to treatment had a more severe symptomatic course of the disease, which may have been associated with unchanged cytokine levels (17). The duration of macrolide therapy in patients with COP is currently unknown. However, majority of cases are

treated without relapsing with a macrolide therapy for more than 3 months (18,19).

Complete regression was achieved in our all cases and no relapse was observed. Treatment was usually continued for at least 3 months. There were no adverse events caused by CLA. It is very difficult to draw any conclusions regarding factors promoting good response to CLA in such a small group. Undoubtedly, our patients were characterized by good clinical status and they did not have any severe ventilatory impairment or severe hypoxemia.

Evidence of the efficacy of macrolides with specific and unspecific inflammatory activities in COP have been repeatedly shown. Its use should be considered for the treatment of patients with COP. Further studies are needed to identify candidates for CLA treatment.

## CONCLUSIONS

CLA seems to be effective in selected patients with COP. This therapy is better tolerated than corticosteroid therapy and does not produce serious adverse effects. It may represent an alternative treatment to steroids in non severe cases with COP. Prospective studies are needed to determine the most effective dosing regimen for treating COP.

## REFERENCES

1. American Thoracic Society and European Respiratory Society. American Thoracic Society/European Respiratory Society International Multidisciplinary Consensus Classification of the Idiopathic Interstitial Pneumonias. This joint statement of the American Thoracic Society (ATS) and the European Respiratory Society (ERS) was adopted by the ATS board of directors, June 2001 and by the ERS Executive Committee, June 2001. *Am J Respir Crit Care Med* 2002; 165: 277-304.
2. Taniguchi H, Kondoh Y. Acute and subacute idiopathic interstitial pneumonias. *Respirology* 2016; 21: 810-20.
3. Izumi T, Kitaichi M, Nishimura K, Nagai S. Bronchiolitis obliterans organizing pneumonia. Clinical features and differential diagnosis. *Chest* 1992; 102: 715-9.
4. Yousem SA, Lohr RH, Colby TV. Idiopathic bronchiolitis obliterans organizing pneumonia/cryptogenic organizing pneumonia with unfavorable outcome: pathologic predictors. *Mod Pathol* 1997; 10: 864-71.
5. Lee J, Cha SI, Park TI, Park JY, Jung TH, Kim CH. Adjunctive effects of cyclosporine and macrolide in rapidly progressive cryptogenic organizing pneumonia with no prompt response to steroid. *Intern Med* 2011; 50: 475-9.
6. Ianaro A, Ialenti A, Maffia P, Sautebin L, Rombolà L, Carnuccio R, Iuvone T, D'Acquisto F, Di Rosa M. Antiinflammatory activity of macrolide antibiotics. *J Pharmacol Exp Ther* 2000; 292: 156-63.

7. Dorca J, Padrones S, Manresa F. Macrolides and lower respiratory tract infections. *Eur Respir Mon* 2004; 28: 78-93
8. Pathak V, Kuhn JM, Durham C, Funkhouser WK, Henke DC. Macrolide use leads to clinical and radiological improvement in patients with cryptogenic organizing pneumonia. *Ann Am Thorac Soc* 2014; 11: 87-91.
9. Chang WJ, Lee EJ, Lee SY, In KH, Kim CH, Kim HK, Park S. Successful salvage treatment of steroid-refractory bronchiolar COP with low-dose macrolides. *Pathol Int* 2012; 62: 144-8.
10. Cordier JF. Cryptogenic organising pneumonia. *Eur Respir J* 2006; 28: 422-46.
11. Cordier JF, Loire R, Brune J. Idiopathic bronchiolitis obliterans organizing pneumonia. Definition of characteristic clinical profiles in a series of 16 patients. *Chest* 1989; 96: 999-1004.
12. Johkoh T, Muller NL, Cartier Y, Kavanagh PV, Hartman TE, Akira M, Ichikado K, Ando M, Nakamura H. Idiopathic interstitial pneumonias: diagnostic accuracy of thin section CT in 129 patients. *Radiology* 1999; 211: 555-60.
13. Cai M, Bonella F, Dai H, Sarria R, Guzman J, Costabel U. Macrolides inhibit cytokine production by alveolar macrophages in bronchiolitis obliterans organizing pneumonia. *Immunobiology* 2013; 218: 930-7.
14. Ichiyama T, Nishikawa M, Yoshitomi T, Hasegawa S, Matsubara T, Hayashi T, Furukawa S. Clarithromycin inhibits NF-kappaB activation in human peripheral blood mononuclear cells and pulmonary epithelial cells. *Antimicrob Agents Chemother* 2001; 45: 44-7.
15. Giamarellos-Bourboulis EJ. Macrolides beyond the conventional antimicrobials: a class of potent immunomodulators. *Int J Antimicrob Agents* 2008; 31:12-20.
16. Amsden GW. Anti-inflammatory effects of macrolides—an underappreciated benefit in the treatment of community-acquired respiratory tract infections and chronic inflammatory pulmonary conditions? *J Antimicrob Chemother* 2005; 55: 10-21.
17. Radzikowska E, Roży A, Jaguś P, Wiatr E, Gawryluk D, Chorostowska-Wynimko J, Roszkowski-Śliż K. Cryptogenic Organizing Pneumonia: IL-1 $\beta$ , IL-6, IL-8, and TGF- $\beta$ 1 Serum Concentrations and Response to Clarithromycin Treatment. *Adv Exp Med Biol* 2016; 911: 77-85.
18. Chang WJ, Lee EJ, Lee SY, In KH, Kim CH, Kim HK, Park S. Successful salvage treatment of steroid refractory bronchiolar COP with low-dose macrolides. *Pathol Int* 2012; 62: 144-8.
19. Stover DE, Mangino D. Macrolides: a treatment alternative for bronchiolitis obliterans organizing pneumonia? *Chest* 2005; 128: 3611-7.