

NEW BRAIN LESIONS IN A PATIENT WITH SARCOIDOSIS: IS IT NEUROSARCOIDOSIS?

Subodh Pandey¹, Sanjay Mukhopadhyay², Michael C. Iannuzzi³, Birendra Sah⁴

¹ Resident, Department of Medicine, SUNY Upstate Medical University, ² Associate Professor, Department of Pathology, SUNY Upstate Medical University; ³ Professor and Chair, Department of Medicine, SUNY Upstate Medical University; ⁴ Assistant Professor of Medicine, Department of Pulmonary/Critical care, SUNY Upstate Medical University

ABSTRACT. A 45-year-old woman with pulmonary sarcoidosis diagnosed 5 years previously, who was on treatment with prednisone and methotrexate for 1 year, developed partial seizure with secondary generalization. MRI showed three non-cavitary enhancing lesions in the cerebello-occipital region. These lesions were presumed to be neurosarcoidosis. Methotrexate was discontinued, prednisone dose was increased as well as azathiopurine and levetiracetam were added. While on treatment, follow up imaging showed enlarging brain lesions. Biopsy of the lesions showed Epstein Barr virus (EBV) positive diffuse B cell lymphoma. Immunosuppressants were tapered off and she was begun on Rituximab. Because of lack of improvement after 4 cycles of Rituximab, she was then treated with high dose Methotrexate and Temozolamide. We present this case as a diagnostic challenge. New enhancing brain lesions occurring in a patient with long standing sarcoidosis, while likely to be neurosarcoidosis, may be due to a complication of immunosuppressant therapy. The need for early biopsy, if the lesions do not improve, should be considered. (*Sarcoidosis Vasc Diffuse Lung Dis* 2014; 31: 62-66)

KEY WORDS: Neurosarcoidosis, Immunodeficiency associated lymphoproliferative disorder, Methotrexate

INTRODUCTION

Neurologic manifestations occur in approximately 5-8% of cases with sarcoidosis (1-2). When a patient with sarcoidosis presents with neurological lesions in addition to neurosarcoidosis, infection and

malignancy should also be considered. We present the first case report of CNS lymphoma occurring in a patient with sarcoidosis who was on treatment with methotrexate and prednisone.

CASE REPORT

A 45-year-old woman was diagnosed with sarcoidosis, histologically confirmed by supraclavicular lymph node biopsy. Initially she had minimal symptoms and was not on any therapy. Three years later she presented with worsening cough and dyspnea. A chest CT showed increase in size of mediastinal and bilateral hilar lymph nodes with bilateral pulmonary nodules (Figure 1). Pulmonary function tests showed normal spirometry, lung volumes and diffusion capacity

Received: 03 June 2013

Accepted after revision: 24 October 2013

Correspondence: Birendra Sah, MD

Assistant Professor of Medicine

Department of Pulmonary/Critical care

SUNY Upstate Medical University

750 E. Adams St.

Syracuse, N.Y. 13210, USA

Phone: (315) 464-5411

Fax: (315) 464-6228

E-mail: sahb@upstate.edu

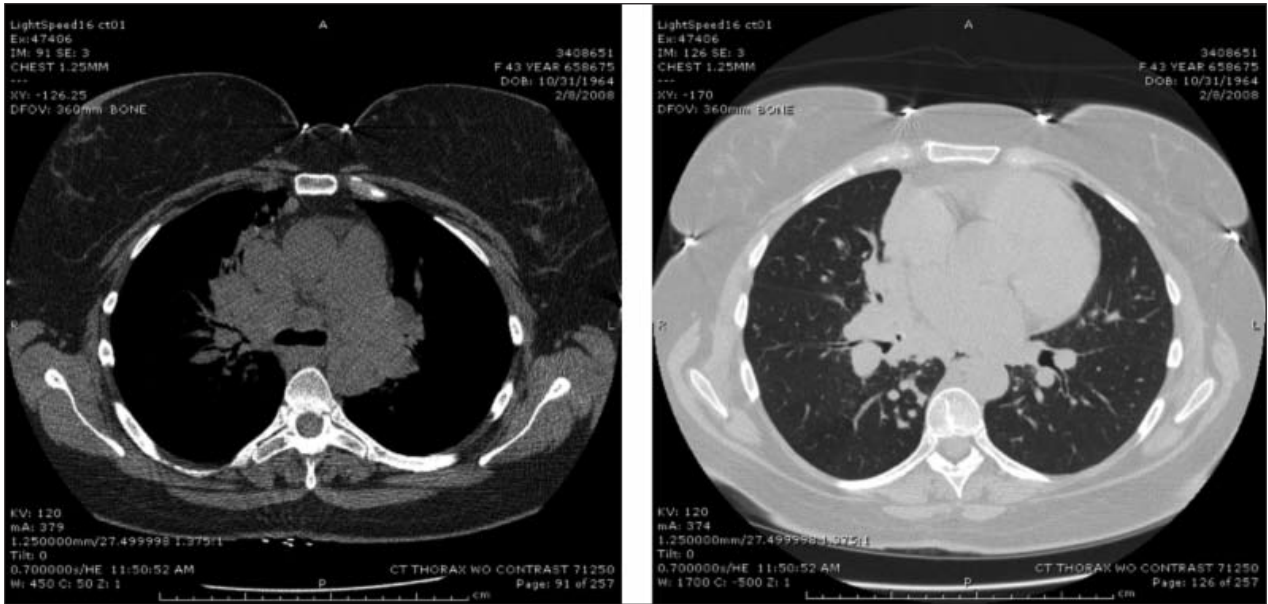


Fig. 1. CT scan images of thorax without contrast showing mediastinal and hilar lymphadenopathy and pulmonary nodules.

of carbon monoxide. She was started on Prednisone. Because she remained symptomatic on prednisone, Methotrexate (MTX) was added. One year later she was off prednisone and continued on MTX at 15 mg weekly. Eleven months later she presented with partial seizures with secondary generalization. Her serum angiotensin converting enzyme (ACE) was elevated

to 95 U/L. Mistakenly CSF fluid analysis was not done. Brain MRI with and without contrast showed 3 enhancing lesions; a 12 mm lesion in the left parieto-occipital region with surrounding edema, a 6 mm lesion in the posterior cerebellum and a 6 mm lesion in cerebellar vermis (Figure 2). Given her history of sarcoidosis, she was thought to have probable neurosar-

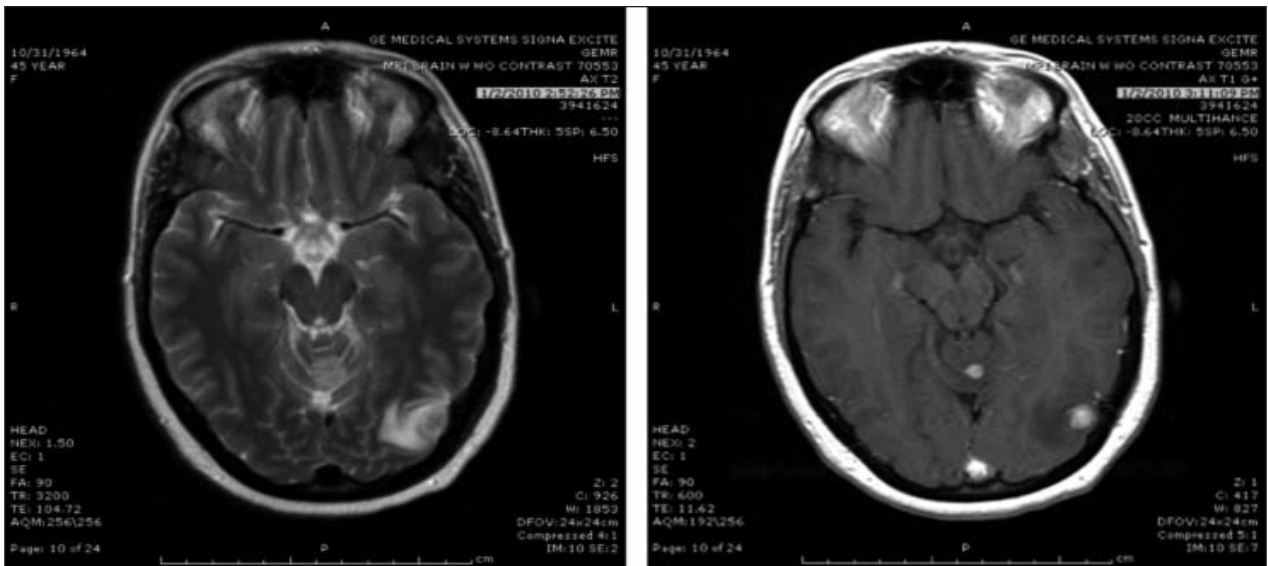


Fig. 2. (Left) T2 weighted image of brain MRI showing 1.2 cm enhancing mass in the left parieto-occipital lobe with surrounding edema. A second enhancing mass identified in the cerebellar vermis, measuring 6.0 mm. (Right) T1 weighted image of brain MRI with contrast showing enhancement of the lesions.

coidosis and was treated with Prednisone and Azathioprine. Four weeks later the patient had breakthrough seizures and follow up MRI showed increase in the size of brain lesions. She underwent biopsy of the left parietal brain lesion. The biopsy demonstrated immunodeficiency associated lymphoproliferative disorder consistent with diffuse B-cell lymphoma because to the detection of Epstein Barr Virus in brain tissue (Figure 3). Her immunosuppressants were tapered off and the patient was given 4 cycles of Rituximab. Repeat MRI still showed some increase in her brain lesions so treatment was changed to high dose MTX and temozolamide. She completed 8 cycles of chemotherapy and the subsequent MRI demonstrated a decrease in the size of the brain lesions.

DISCUSSION

The diagnosis of neurosarcoidosis remains a challenge. It may precede the diagnosis of sarcoidosis in up to 74% of patients and is the only manifestation in 10 to 17% of patients with neurosarcoidosis (3-4). Common clinical manifestations of neurosarcoidosis include cranial neuropathies, meningitis, neuroendocrinological dysfunction, hydrocephalus, seizures, neuropsychiatric symptoms, myelopathy and neuropathies (5). Cerebrospinal fluid analysis may show lymphocytic pleocytosis, and in a third of patients, oligoclonal immunoglobulin bands in the cerebrospinal fluid are elevated, making it difficult to differentiate sarcoidosis from multiple sclerosis (3). The diagnostic value of measuring ACE levels in cerebrospinal fluid is controversial.

The differential diagnosis of CNS lesions includes infections (tuberculosis, HIV, syphilis, meningitis, toxoplasma, progressive multifocal

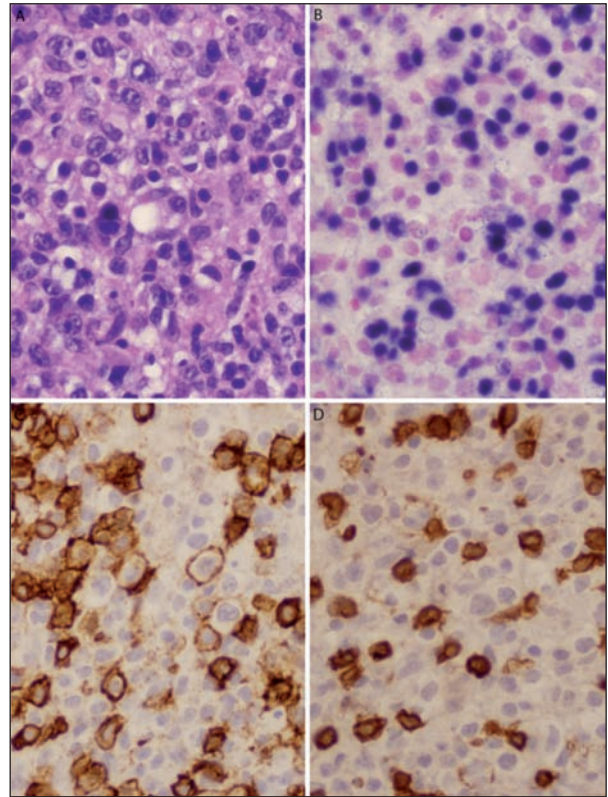


Fig. 3. Methotrexate-associated lymphoproliferative disorder (diffuse large B-cell lymphoma). A. Large atypical lymphoid cells admixed with small lymphocytes (hematoxylin-eosin). B. In-situ hybridization for Epstein-Barr virus encoded RNA (EBER) is positive in the tumor cell nuclei (blue signals). C. CD20 marks the large tumor cells. D. CD3 highlights admixed small T-lymphocytes. All photomicrographs (A-D) at 400x.

leukoencephalopathy); malignancy (primary CNS lymphoma, astrocytoma, other primary, metastatic brain tumors); and inflammatory or immune disorders (CNS vasculitis, multiple sclerosis). Diagnostic criteria by Zajicek et al are listed in Table 1 (6).

Table 1. Diagnostic criteria for neurosarcoidosis to establish definite, probable and possible disease.

Definite	Clinical presentation compatible with neurosarcoidosis Exclusion of other possible causes Positive nervous system histology
Probable	Clinical presentation compatible with neurosarcoidosis Laboratory support of CNS inflammation* Exclusion of other possible causes Evidence of systemic sarcoidosis**
Possible	Clinical presentation compatible with neurosarcoidosis Exclusion of other possible causes

*High concentrations of CSF protein and high numbers of cells, the presence of oligoclonal bands, or MRI evidence compatible with neurosarcoidosis.

**Positive histology or at least two indirect indicators from gallium scan, chest imaging, and serum angiotensin converting enzyme.

In an immunocompromised patient, primary CNS lymphoma (PCNSL) should also be considered. PCNSL is a type of non-Hodgkin's lymphoma confined to the brain and spinal cord which represents approximately 3% of all primary intracranial neoplasms (7). The most common form is diffuse large B-cell lymphoma. PCNSL has been associated with immunodeficiencies such as AIDS and iatrogenic immunosuppression (8). In HIV-infected patients the reported incidence of PCNSL is 2 to 6 percent (at least 1000 times higher than in the general population) (9). Iatrogenic immunosuppression induced PCNSL mostly occur in post-transplant patients. PCNSL has been reported in association with Methotrexate in rheumatoid arthritis patient and with Azathioprine in myasthenia gravis patients (10-12). We did not find any reported cases of Methotrexate induced PCNSL in sarcoidosis.

On initial presentation with seizure our patient had systemic sarcoidosis for 5 years; her MRI was compatible with neurosarcoidosis and hence was treated as probable neurosarcoidosis according to Zajicek et al criteria.

The diagnostic yield of CSF cytology for PCNSL is 26% in immunocompetent person, and further, EBV analysis of CSF in HIV patients has a sensitivity of 80 to 90 percent, and specificity approaches upto 100 percent (12, 13). If these results are extrapolated to immunosuppressive associated PCNSL, a positive result would mean early diagnosis and in cases, negate the need for biopsy.

Immunosuppression related PCNSL are usually diffuse large B-cell lymphoma, associated with EBV (13). In iatrogenic immunosuppressant cases, withdrawal of the immunosuppressive drugs leads to tumor regression (14). Definite therapy employ chemotherapy regimens usually incorporating high dose Methotrexate (15). The role of whole brain radiation is controversial, and surgery is confined just to biopsy.

CONCLUSION

Our case report highlights the diagnostic challenge of new brain lesions in a patient with known sarcoidosis. The possible causes are broad and apart from histology, none of the diagnostic modalities are definitive. In treating histologically unconfirmed disease – probable and possible neurosarcoidosis, it is

necessary to keep other causes in mind, especially iatrogenic lymphoproliferative disorder secondary to immunosuppressive agents.

REFERENCES

1. Stern BJ, Krumholz A, Johns C, Scott P, Nissim J. Sarcoidosis and its neurological manifestations. *Archives of neurology*. 1985 Sep;42(9):909–17. Available from: <http://www.ncbi.nlm.nih.gov/pubmed/3896208>
2. Lower EE, Broderick JP, Brott TG, Baughman RP. Diagnosis and management of neurological sarcoidosis. *Archives of internal medicine*. 1997 Sep 8;157(16):1864–8. Available from: <http://www.ncbi.nlm.nih.gov/pubmed/9290546>
3. Kellinghaus C, Schilling M, Lüdemann P. Neurosarcoidosis: clinical experience and diagnostic pitfalls. *European neurology*. 2004 Jan;51(2):84–8. Available from: <http://www.ncbi.nlm.nih.gov/pubmed/14752214>
4. Nozaki K, Scott TF, Sohn M, Judson MA. Isolated neurosarcoidosis: case series in 2 sarcoidosis centers. *The neurologist*. 2012 Nov;18(6):373–7. Available from: <http://www.ncbi.nlm.nih.gov/pubmed/23114669>
5. Nozaki K, Judson MA. Neurosarcoidosis: Clinical manifestations, diagnosis and treatment. *Presse médicale (Paris, France)*. 2012 Jun;41(6 Pt 2):e331–48. Available from: <http://www.ncbi.nlm.nih.gov/pubmed/22595777>
6. Zajicek JP, Scolding NJ, Foster O, Rovaris M, Evanson J, Moseley IF, et al. Central nervous system sarcoidosis—diagnosis and management. *QJM: monthly journal of the Association of Physicians*. 1999 Feb;92(2):103–17. Available from: <http://www.ncbi.nlm.nih.gov/pubmed/10209662>
7. Gerstner ER, Batchelor TT. Primary central nervous system lymphoma. *Archives of neurology*. 2010 Mar;67(3):291–7. Available from: <http://www.ncbi.nlm.nih.gov/pubmed/20212226>
8. Raez LE, Patel P, Feun L, Restrepo A, Raub WA, Cassileth PA. Natural history and prognostic factors for survival in patients with acquired immune deficiency syndrome (AIDS)-related primary central nervous system lymphoma (PCNSL). *Critical reviews in oncogenesis*. 1998 Jan;9(3-4):199–208. Available from: <http://www.ncbi.nlm.nih.gov/pubmed/10201628>
9. Flinn IW, Ambinder RF. AIDS primary central nervous system lymphoma. *Current opinion in oncology*. 1996 Sep;8(5):373–6. Available from: <http://www.ncbi.nlm.nih.gov/pubmed/9026061>
10. Chou AP, Lalezari S, Fong BM, Dye J, Pham T, Vinters H V, et al. Post-transplantation primary central nervous system lymphoma: A case report and review of the literature. *Surgical neurology international*. 2011 Jan;2:130. Available from: <http://www.pubmedcentral.nih.gov/articlerender.fcgi?artid=3205489&tool=pmcentrez&rendertype=abstract>
11. Kästner F, Paulus W, Deckert M, Schlegel P, Evers S, Husstedt IW. [Primary CNS lymphoma in azathioprine therapy for autoimmune diseases: review of the literature and case report]. *Der Nervenarzt*. 2007 Apr;78(4):451–6. Available from: <http://www.ncbi.nlm.nih.gov/pubmed/17375274>
12. Mariette X, Cazals-Hatem D, Warszawski J, Liote F, Balandraud N, Sibilia J. Lymphomas in rheumatoid arthritis patients treated with methotrexate: a 3-year prospective study in France. *Blood*. 2002 Jun 1;99(11):3909–15. Available from: <http://www.ncbi.nlm.nih.gov/pubmed/12010788>
13. Turner JJ, Morton LM, Linet MS, Clarke CA, Kadin ME, Vajdic CM, et al. InterLymph hierarchical classification of lymphoid neoplasms for epidemiologic research based on the WHO classification (2008): update and future directions. *Blood*. 2010 Nov 18;116(20):e90–8. Available

- from: <http://www.pubmedcentral.nih.gov/articlerender.fcgi?artid=2993636&tool=pmcentrez&rendertype=abstract>
14. Kamel OW, Van de Rijn M, Weiss LM, Del Zoppo GJ, Hench PK, Robbins BA, et al. Brief report: reversible lymphomas associated with Epstein-Barr virus occurring during methotrexate therapy for rheumatoid arthritis and dermatomyositis. *The New England journal of medicine*. 1993 May 6; 328(18): 1317–21. Available from: <http://www.ncbi.nlm.nih.gov/pubmed/8385742>
15. Doucet S, Kumthekar P, Raizer J. Primary Central Nervous System Lymphoma. *Current treatment options in oncology*. 2013 Mar 2; Available from: <http://www.ncbi.nlm.nih.gov/pubmed/23456261>